

An epoch systematic review for the management of oral lichen planus

Sayantika Jana¹, Atul Anand Bajoria^{2*}, Sangamesh NC², Silpiranjan Mishra², Sukriti Mukherjee², Shailja Das¹

¹Kalinga Institute of Dental Sciences, KIIT Deemed to be University, Patia, Bhubaneswar – 751024, Odisha, India

²Department of Oral Medicine & Radiology, Kalinga Institute of Dental Sciences, KIIT Deemed to be University, Patia, Bhubaneswar – 751024, Odisha, India

Abstract

Potentially malignant disorder, Oral lichen planus is a chronic mucocutaneous disorder due to abnormal immunological reaction. We reviewed review articles, case reports, case series, systemic reviews, and meta-analyses from 2021 to 2023 available in English literature on newer modalities in the management of oral lichen planus. Among all treatment modalities. Most effective specialists are related to gentle, nearby ADRS. oral candidiasis is the most widely recognized antagonistic response of effective corticosteroids. In general, effective specialists are all tolerated with no fundamental ARDS. The essential objective is suggestive administration and current treatment choices incorporate corticosteroids, calcineurin inhibitors, vitamin D, photodynamic therapy, cyclosporin, normal other options, laser, and ozone treatment. As per the evidence of efficacy and side effects, Topical calcineurin inhibitors (tacrolimus > pimecrolimus > cyclosporin) are safe and more effective than topical steroids (triamcinolone) followed by intralesional (betamethasone > triamcinolone).

Keywords: Oral Lichen Planus, meta-analysis, calcineurin inhibitors

Full-length review article* Corresponding Author, e-mail: atultink@gmail.com

1. Introduction

Oral Lichen Planus (OLP) is an ongoing mucocutaneous immune system problem emerging due to a strange immunological reaction. T-cell interceded provocative condition. It is overall normal in the fourth - fifth 10 years of life and has a female tendency. Clinically, Oral Lichen Planus is portrayed by white reticulation (wickham striae), erythema, and more over ulcerations. It is a possibly threatening problem and can be either suggestive or asymptomatic [1].

Besides the conventional treatment protocols, newer treatment modalities shown relatively better results in the remission of the lesion with less adverse effects. The present systematic review contains all the various treatment modalities used for the treatment of oral lichen planus in the past couple of years. Methodical writing search was performed from database commencement until January 2023 in the electronic data sets, MEDLINE by means of PubMed and Google Researcher. The pursuit was directed in PubMed on utilizing clinical subject heading terms, "oral lichen planus", "oral lichen planus, drug therapy".

The search strategy (Figure 1) was as follows; "Lichen Planus, Oral" [Mesh] OR "Lichen Planus, Oral/drug therapy"[Mesh] AND "topical corticosteroids"[Mesh] OR dexamethasone[tiab] OR clobetasol[tiab] OR triamcinolone

[tiab] AND "topical calcineurin inhibitors"[tiab] OR tacrolimus[tiab] OR pimecrolimus[tiab] OR cyclosporine[tiab] AND ("systemic therapies"[Mesh] OR corticosteroids[tiab] OR hydroxychloroquine AND ("lesion-directed therapy"[Mesh] OR "intra-lesional steroid injections"[tiab] OR "intralesional dexamethasone"[tiab]) AND ("phototherapy"[Mesh] OR "photodynamic therapy"[tiab] OR ("laser therapy"[Mesh]) AND ("topical amelanox"[tiab]) AND ("natural therapies"[Mesh]).

2. Review and Discussion

2.1. Corticosteroids

Corticosteroids have largely been used as the first-line treatment for oral lichen planus because of their ability to diminish cell-mediated immune activity and modulate immune function.

2.2. Topical Corticosteroids

Prolonged use of topical steroids with occlusal dressing can lead to adrenal suppression. Sandhu et al 2022 in systematic review On his comparative efficacy and treatment plan of oral lichen planus stated in his article that Topical

steroids seem to be the most practical and cost-effective treatment [2].

2.3. Intralesional Corticosteroids

Prolonged use of intralesional corticosteroids it can cause muscular atrophy with prolonged use. Ftiset, al, 2022 in his study on to determine safety and efficacy of intralesional corticosteroids injection On management of oral lichen planus stated in his article that Betamethasone administered intra-lesionally may be an advantageous addition to the topical management of oral lichen planus lesions, avoiding the risks associated with systemic corticosteroid administration [3].

2.4. Systematic Corticosteroids

Gururaj 2021, in his review on diagnosis and management of oral lichen planus stated in his article that Prednisone 10–20 mg/day may be recommended as a low-dose systemic steroid in the morning for patients with extensive symptomatic lesions. If the duration of systemic administration exceeds two weeks, the tapering module should be used. A topical or systemic anti-fungal medication will be helpful, especially in patients whose candidiasis developed after using long-term steroids [4].

2.5. Topical Tacrolimus

It has been established that tacrolimus is both safe and efficient for treating oral lichen planus. It is an immunosuppressant that doesn't require steroid injections, has a quicker recovery time, and causes fewer recurrences because it doesn't suppress the HPA axis or cause supradadded candidal infections. The momentary use of tacrolimus is a viable routine in OLP patients impervious to other effective and fundamental treatments, moreover, the unfavorable impacts of tacrolimus were minor and transient and didn't influence tacrolimus proceeded with application, as per Su et al 2021 in their foundational audit and meta examination on adequacy and wellbeing of skin organization of tacrolimus in oral lichen planus [5].

2.6. Vitamin- D

The safe framework relies upon vitamin D, which likewise has calming, antibacterial, hostile to proliferative, hostile to angiogenic, and supportive of separating capabilities. The dynamic vitamin D metabolite calcitriol is known as a pleiotrophic chemical. Atomic vitamin D receptors on invulnerable cells (B and T lymphocytes), neutrophils, monocytes, and dendritic cells interface with calcitriol. It increments apoptosis and restrains B cell advancement and expansion.

By lessening the arrival of Type 1 supportive of provocative cytokines (IL-8, TNF alfa, and interferon-gamma), vitamin D likewise controls the versatile invulnerable reaction. It advances the creation of Type 2 calming cytokines (IL-4, IL-5, and IL-10 and upregulates the humoral (Th2) response. Shazeena Saeed's oral lichen planus was treated with vitamin D, according to a systematic review. Study results showed a considerable improvement in the condition [6].

2.7. Photodynamic Therapy

Both photodynamic treatment and photo-biomodulation are harmless, safe, and have the vital advantage of basically no bad effects. PBM - Balance of Bajoria et al., 2023

favorable to and calming cytokines and development factors, as well as an expansion in ATP levels brought about by the age of receptive oxygen species and the ensuing actuation of the record factor NK-8. In his article, Magdalena Ewa Sulewska 2023 on randomised control trial on photodynamic therapy and photo-biomodulation in combination with acetamide- triamcinolone 0.1% as a means of treating oral lichen planus stated that "both photodynamic therapy and photo-biomodulation once a week for four weeks are safe and non-invasive treatment options, with the important advantage of lacking adverse effects" [7].

2.8. Rivelin-Clo

"Rivelin-CLO 20 g/patch treatment for 4 weeks resulted in clinically significant improvement in OLP ulcer size, symptoms, and quality of life, with a favorable safety profile, demonstrating its potential to address a significant unmet need in OLP," wrote Michael T. Brennan in his article from 2022 [8].

2.9. Coconut cream

With no side effects and no signs of poisonousness noted during therapy or follow-up for OLP. The size of the sore and the feeling of consuming something significantly decreased. According to Roshani Mamadapur's 2022 randomised control trial on the "efficacy of topical coconut cream and clobetasol propionate ointment for the management of oral lichen planus on", the coconut cream ended up being a protected and powerful treatment for OLP in light of the fact that it fundamentally diminished the size of the sore and the consuming sensation without causing any secondary effects or giving any indications of harmfulness during treatment or follow-up [9].

2.10. Nigella sativa

Cream produced using nigella sativa oil might be a protected, promising, adjuvant, or discretionary treatment. The skin use of nigella sativa cream was compelling and equivalent to clobetasol propionate 0.05% gel in the administration of oral lichen planus, with practically no secondary effects, as per Lokesh Kumar S 2022 on randomized control preliminary on Relative assessment of the viability of nigella sativa (75% v/v) cream and clobetasol propionate (0.05% w/w) gel. Along these lines, this study proposes utilizing skin Nigella sativa cream treatment for the treatment of OLP [10].

2.11. Topical Cyclosporine

In contrast to topical dexamethasone, which has all the drawback of being less clearly during beginning organization but capable of inciting further improvement after stopping with a good long reduction without any serious side effects, skin cyclosporine treatment brings about a huge clinical improvement in interesting OLP patients. Skin cyclosporine treatment prompts a basic clinical improvement in interesting OLP patients, though it seems less pronounced initially when compared to topical dexamethasone treatment, according to Maria Georgaki's 2022 article on a randomised control trial comparing the two treatments for oral lichen planus [11].

Table 1: Study with result by various authors on lichen planus management

Sr. #	Author/Year	Type of Study	Sample Size	Drug with Mode of Delivery	Results
1.	Eduardo Liberato da Silva, <i>et al.</i> , 2021	Systematic and Meta Analysis Review	28 randomized control trial	Tacrolimus 1% (topical) Pimecrolimus 1% (topical)	Topical tacrolimus and pimecrolimus are safe and effective than topical steroids.
2.	Maria Georgaki 2021	Randomized control trial	32 patients with biopsy-proven symptomatic OLP follow up for 6 months.	Topical dexamethasone vs cyclosporine. Topical cyclosporine 100mg/ml topically swiss and spit method 3 times a day for 4 weeks.	Topical cyclosporine more effective than topical dexamethasone.
3.	Cheshta Walia, <i>et al.</i> , 2022	Pilot Prospective Observational Study	52 symptomatic OLP patients	5ml intralesional injection of Triamcinolone Acetonide (TA) once a week for the first 4 weeks followed by one injection in the 6 th week along with . 1% TA mucosal paste and .03% Tacrolimus ointment in tapering dose till 8 th week	Combination of TA and TAC is more effective treatment in symptomatic oral lichen planus.
4.	S. Utz, <i>et al.</i> , 2022	Retrospective Analysis	57 (74% women, median age 66yrs)	Topical Tacrolimus, 0.03% oral rinse	Objective Remission- 28%,62%,87%,97% Of patients after 3,6,12,24 months respectively. Subjective Remission- 16%,48%,69%,83% After 3,6,12,24 months.
5.	LiliaKavliakova2022	Comparative Study	20 patients with histologically proven symptomatic OLP with gingival manifestation	Topical Tacrolimus 0.1% and Clobetasol propionate 0.05%	Tacrolimus can be considered as a decent option for topical medication particularly who does not respond to Topical corticosteroid.
6.	Vaibhav Seth <i>et al.</i> , 2022	Comparative Study Randomized double blinded placebo controlled clinical trial.	40 patients aged 18-70 years with erosive lichen planus.	Topical oral cream Amlexanox 5%, Triamcinolone Acetonide cream 0.1% , tacrolimus oral cream 0.03%. Glycerine	Topical application of 5% amlexanox paste is as effective as 0.03% tacrolimus and 0.1% acetone.

7.	Shazeena Saeed 2022	Systematic Review	5 studies, 3 were randomized controlled clinical trial and two were observational studies.	Vitamin D supplements as an adjunct to the conventional steroid therapy Placebo	Anti inflammatory and Immunomodulatory properties Alongwith its regulatory effects on keratinocytes proliferation and differentiation.
8.	Alaka saho 2022	Systematic review	11- phytoextracts, 7 phytochemicals 9phytoformulations	hyto-extracts, Phyto-chemicals, Phyto-formulationsP	.Natural ethnomedicines useful as potential, cost effective , less toxic compared to steroids.
9.	Walid ftis 2022	Randomized control trial	20 patients divided Into 2 equal groups.	1.4mg intralesional betamethasone, 8mg intralesional tiamcenolone acetonide	Intralesional betamethsone has better healed results than intralesional triamcinolone.

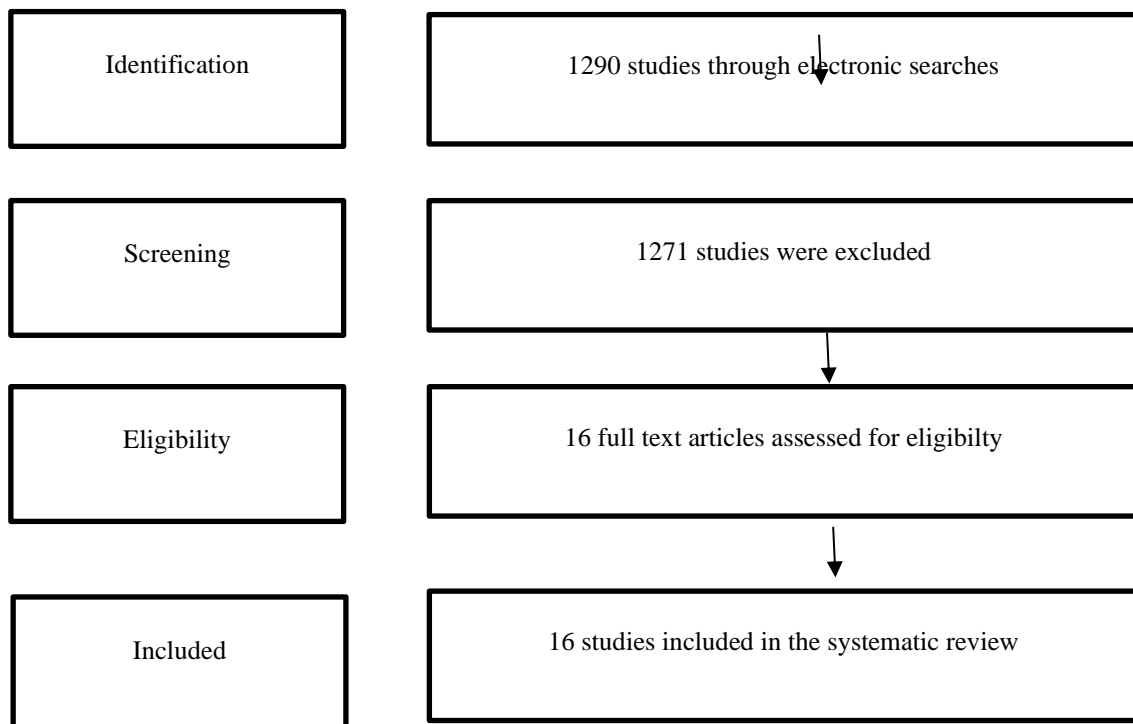


Figure 1: Search Strategy

2.12. Spirulina

Spirulina (*spirulina platensis*) is blue green growth and a rich wellspring of protein and nutrient supplementation with no huge side effects. It likewise has mitigating, immunomodulatory, cell reinforcement, and gastroprotective properties. It has a high protein content (up to 70%), nutrients, as B12 and provitamin A (β -carotenes). Furthermore, minerals, particularly iron. It likewise contains phenolic acids, tocopherol, and γ -linolenic corrosive. It has handily processed as it needs cellulose cell walls. The elevated degrees of phycocyanin, beta carotene, furthermore, superoxide dismutase can have a potential chemopreventive job in high-risk oral possibly harmful disorders.

The phycocyanin hinders proinflammatory cytokine development, like $\text{TNF}\alpha$, stifles cyclooxygenase-2 (COX-2) articulation, diminishes the development of prostaglandin E(2), smothers the enactment of atomic component κB by forestalling the corruption of cytosolic $\text{I}\kappa\text{B}-\alpha$ — in this manner, adjusting the mitogen-actuated protein kinase (MAPK) enactment pathways. One more element of spirulina, β -carotene, has been accounted for to have cancer prevention agent and calming activities. Because of the great many advantages of spirulina on resistant downregulation component and free radicle searching activity, the current review was pointed toward assessing its adequacy in the in general decrease of irritation in OLP subsequently lessening the consuming sensation and the lesion size as a clinical result. CSK Nallan Spirulina 500 mg supplementation two times a day could be a productive assistant treatment with steroids to treat oral lichen planus, according to Chaitanya et al.'s 2022 randomised control experiment on the efficiency of the supplements compared to triamcinolone acetonide 0.1% [12].

2.13. Laser Therapy

The clinical procedure known as laser PBM, formerly known as low level laser therapy (LLLT), uses a reasonable light emission that connects with explicit atoms in the tissues known as chromophores to give pain relieving, moderating, and biostimulating effects. Retrospective study by Andrea Raccon et al., 2023 on a single laser photobiomodulation session It is suggested that "a single session of laser PBM may provide some advantages in the reduction of pain for symptomatic OLP, with no undesirable effects" for the treatment of oral lichen planus symptoms [13].

2.14. Ozone Therapy

With meticulous oral mucosal injuries in rats, supplementary ozone treatment and LLLT using a 940 nm diode laser significantly improved the borders of strong irritation and tissue repair. Oznur Ozalp et al.'s comparative analysis of the effectiveness of low level laser therapy and ozone therapy in rats' surgical oral mucosal wounds in 2022 found that "both adjunctive ozone therapy and LLLT with a 940 nm diode laser provided significant improvement in parameters of acute inflammation and tissue repair" [14].

3. Conclusion

Over the last 3 decades, a variety of therapeutics have been used for treatment of oral lichen planus, in this systemic review Topical calcineurin inhibitors (Tacrolimus

>Pimecrolimus>cyclosporin) are safe and effective than topical steroids (triamcinolone) followed by intralesional (betamethasone > triamcinolone).

References

- [1] M.S. Greenberg, M. Glick. (2008). *Burket's Oral Medicine and Diagnosis* 12th edition. 230–360.
- [2] S. Sandhu, B.A. Klein, M. Al-Hadlaq, P. Chirravur, A. Bajonaid, Y. Xu. (2022). Oral lichen planus: comparative efficacy and treatment costs a systematic review. *BMC Oral Health*. 22(1):161
- [3] W. Ftis, H.Ftis, A. Keshlaf, L. Hamad. (2022). Efficacy of intralesion injection of corticosteroid for treating patient with Oral Lichen Planus Lesions. *Khalij-Libya Journal of Dental and Medical Research*. 6(1):90
- [4] N. Gururaj, P. Hasinidevi, V. Janani, T. Divynadaniel. (2021). Diagnosis and management of oral lichen planus - Review. *Journal of Oral Maxillofacial Pathology*. 25(3):392
- [5] Z. Su, J. Hu, B. Cheng, T. Xiaoran. (2022). Efficacy and safety of topical administration of tacrolimus in oral lichen planus: An updated systematic review and meta-analysis of randomized controlled trials. *Journal of Oral Pathology and Medicine*. 51(1): 63-73
- [6] S. Saeed, P. Choudhury, S.A. Ahmad, T. Alam, R. Panigrahi, S. Aziz. (2022). Vitamin D in the Treatment of Oral Lichen Planus: A Systematic Review. *Biomedicine*. 10:2964.
- [7] M.E. Sulewska, J. Tomaszuk, E. Sajewicz, J. Pietruski, A. Starzyńska, M. Pietruska. (2023). Treatment of Reticular Oral Lichen Planus with Photodynamic Therapy: A Case Series. *Journal of Clinical Medicine*. 12:875.
- [8] M.T. Brennan, L.S. Madsen, D.P. Saunders, J.J. Napenas, R.N. Riordain, A.M.L. Pedersen. (2022). Efficacy and safety of a novel mucoadhesive clobetasol patch for treatment of oral lichen planus. *Oral Surgery, Oral Medicine, Oral Pathology and Oral Radiology*. 51(1):86-97
- [9] R. Mamadapur, Z. Naik, S.L. Kumar, A. Bagewadi. (2022). Comparative efficacy of topical coconut cream and clobetasol propionate ointment for the management of oral lichen planus: A double-blinded randomized control trial. *Indian Journal of Pharmacology*. 54(2):84-89
- [10] S.L. Kumar, Z. Naik, A. Panwar, M. Sridhar, V. Keluskar, R.S. Kumar. (2022). Comparative evaluation of the efficacy of *Nigella sativa* (75% v/v) cream and clobetasol propionate (0.05% w/w) gel in oral lichen planus— a double-blinded randomized control trial. *Oral Maxillofacial Surgery*. 22
- [11] M. Georgaki, E. Piperi, V.I. Theofilou, E. Pettas, E. Stoufi, N.G. Nikitakis. (2022). A randomized clinical trial of topical dexamethasone vs. cyclosporine treatment for oral lichen planus. *Oral Medicine, Oral Pathology, and Oral Surgery*. 27(2):e119-e122.
- [12] N.C. Chaitanya, D. Chikte Y.P. Kumar, G. Komali S.P. Yellarthi, C.S. Reddy, P. Panta. (2022). Efficacy

of Spirulina 500 mg vs Triamcinolone Acetonide 0.1% for the Treatment of Oral Lichen Planus: A Randomized Clinical Trial, *The Journal of Contemporary Dental Practice*. 556

- [13] A. Roccon, F. Cavallin, G. Zanette, C. Bacci. (2023). Single session of laser photobiomodulation for symptom management of oral lichen planus: a retrospective study. *Lasers in Medical Science*. 38(1):43
- [14] O. Özalp, A. Sindel, M.A. Altay, I.H. Özbudak, B. Bilgin, B. Kocabalkan, D. Kader. (2022). Comparative evaluation of the efficacy of ozone therapy and low level laser therapy on oral mucosal wound healing in rat experimental model, *Journal of Stomatology, Oral and Maxillofacial Surgery*. 123(6):e672