

Assessment of Awareness, Knowledge and Attitude Towards Endocrowns Among Dental Practitioners in Chennai – A Questionnaire Study

Shindhuja N¹, Dr.Eazhil. R², Harish Raghav A¹

¹CRI, Chettinad Dental College and Research Institute, Kelambakkam, Chennai

²Professor, Department of Prosthodontics and Crown and Bridge, Chettinad Dental College and Research Institute, Kelambakkam, Chennai

Abstract

The aim of the study is to assess the awareness, knowledge, attitude towards endocrowns among dental practitioners. This cross-sectional study targeted dental practitioners in Chennai who were selected randomly. The calculated sample size was 256. A closed ended questionnaire was prepared according to the need of the study. It was sent to the study population through online mode. The responses of the participants were collected. 256 collected responses were analysed using SPSS software and descriptive statistics were obtained. Most of the participants were between the age group of 25-35 years and general dental practitioners (63.5%). About 51% of the participants were slightly aware of endocrowns, 42.58% of the participants preferred prefabricated post and tooth coloured core and crown to restore a badly damaged endodontically treated teeth and about 49% of the participants agreed that they rarely prefer endocrowns over post and core restorations for endodontically treated posterior teeth. Endocrowns were less preferred by the participants for restoring severely damaged endodontically treated teeth. This survey revealed that there is a need to spread awareness, knowledge on endocrowns among dental practitioners in Chennai.

Keywords: Endocrowns, Awareness and knowledge, Questionnaire –Study, Survey

Full-length article

*Corresponding Author, e-mail: eazhil235@gmail.com

Introduction

The coronal rehabilitation of endodontically treated posterior teeth is challenging. Endodontically treated teeth are weakened due to decayed or altered tooth structure attributed to caries or previous restorations, fracture or trauma, endodontic access and instrumentation, decreased moisture (10% less collagen bounded moisture), weaker collagen intermolecular cross-links.[1,2] When considering the restoration of devitalized teeth, dental materials should be able to replace the loss of tooth substance in order to ensure mechanical and functional properties, esthetics and coronal seal.[3] The following factors need to be considered during restoration of endodontically treated teeth, the number of remaining tooth structure, the tooth's location in the dental arch, occlusal forces and aesthetics where appropriate.[4]

Analysis of the reason for all extraction of endodontically treated teeth over a period of 1 year in a military clinic revealed that almost 60% of these were unrestorable tooth fractures, 32% involved periodontal problems and only 7% were endodontic failures .[1,5] Prognosis of Endodontically Treated Teeth (ETT) depends on the success of Root Canal Treatment, efficient obturation of the canal and minimizing the leakage of oral fluids and

bacteria into peri radicular areas maintained by durable coronal restorations that seal and seat properly.[6,7] A potential cause of endodontic failure is bacterial recontamination of the root canal from the oral cavity, due to loss of temporary restoration or leakage of an inadequate final restoration (microleakage). Some retrospective clinical studies reveal that the prognosis of an ETT is also influenced by the post endodontic restoration.[8]. Thus, bacterial recontamination can be prevented by prompt and effective definitive restoration following endodontic therapy [9].

Traditionally, a pulp less tooth received a dowel to “reinforce” it and a crown to “protect” it. The dowel is of two types; preformed dowel system and custom cast dowels: while the core is made up of different materials like amalgam/cast metal / glass ionomer/composite resins [10]. Crowns need to be placed on endodontically treated posterior teeth since they have occlusal interdigitation with opposing teeth that places expansive forces on the cusps. Though post and core system has been extensively used for restoring ETT, they had an average absolute rate of failure of 9% (7 to 14% range) when the data from eight studies were combined (average study length of 6 years) [11]. The common types of post retained restoration failures are endodontic failures,

periodontal disease, vertical root fractures, post dislodgements, post and core separations, crown-core separations [12-16]. Other conservative treatment options to restore ETT include fibre reinforced post and core system, amalcore, overlays, inlays.

In 1995, Pissis introduced monobloc technique that utilized porcelain core/crown unit as a single unit. Then in 1999, based on Pissis concept, Bindle and Mörmann discovered endocrown [17]. It was described as an adhesive porcelain crown fixed to posterior endodontically treated teeth especially molars. These endocrowns are bonded over the conservatively prepared pulp chamber of extensively coronally destructed endodontically treated tooth (crown and core as a single unit). It provides complete occlusal coverage without involving the root canals. They achieve retention from pulp chamber walls and also through adhesion. The new concept of adhesive dentistry, promote the use of endocrowns in clinical practice. In 2015, Sevimli et al stated that endocrown can be implemented in the prosthetic treatment plan of endodontically treated teeth [18].

The purpose of this cross-sectional study was to evaluate the predominant opinion of dentists in terms of current strategies for restoring endodontically treated teeth and to analyze the awareness, knowledge, attitude towards endocrowns.

2. Materials and Methods

A descriptive cross-sectional study was adopted for serving the purpose of the survey. A closed ended questionnaire was prepared, in which some of the questions were adapted from previously published surveys (Akbar 2015, Soliman et al 2021) [7,19]. The study was conducted among dental practitioners inclusive of general dentists, specialists across Chennai, Tamil Nadu. Dentists of all age groups irrespective of the gender were included in the study population. This survey excluded dentists who practice in others states apart from Tamil Nadu. Institutional Ethical Committee approval was obtained. Sample size was set to be 256 by using the following calculation (Figure 1).

The survey population were selected randomly. The questionnaire was distributed online, and duration of 3 months was provided. The questionnaire collected information about the awareness, knowledge on endocrowns and assessed their preference of choosing endocrowns over other options like conventional post and core system to treat an endodontically treated teeth. The collected data were statistically analysed using Statistical Package for Social Sciences software. Descriptive analysis was conducted and results were interpreted using percentage frequency distribution.

3. Results and discussion

Out of 256 respondents, 63.5% of them were general dentists, while 36.5% of them were specialists. Most of the participants were between the age group of 25-35 years.

Endocrowns are monolithic ceramic bonded restoration which provide adequate function and esthetics and preserve the biomechanical integrity of compromised

nonvital posterior teeth. They have less number of adhesive bond surface, hence endocrowns are less susceptible to the adverse effects of degradation of the hybrid layer.[20] They are indicated in endodontically treated teeth with short crown height with suitable pulp chamber depth. In 2018, Dogui et al reported that various clinical scenarios such as calcified root canals, fractured instrument, or narrow canals advocate the use of endocrown in an endodontically treated teeth.[8,21] They are viable alternative for post/core/crown restorations in cases of short crown height.

This questionnaire study assessed the awareness, knowledge, attitude towards endocrowns among dental practitioners. About 49.41% of the respondents preferred tooth coloured restoration to restore an endodontically treated teeth with >50% remaining sound tooth structure. According to Sarkis-Onofre et al (2015), in endodontically treated teeth with three or four coronal walls left, at least one marginal ridge remaining, and no undermined cavity walls, direct adhesive restoration may be considered an alternative cuspal coverage.[22] About 42.58% of the respondents preferred prefabricated post and tooth coloured core and crown to restore an endodontically treated teeth with <50% remaining sound tooth structure while 9.76% of them preferred endocrowns. Nearly half of them encountered less than 25% of the patients who complains of frequent dislodgement of crowns in endodontically treated teeth. About 39.7% believe that crown fracture is the most frequent drawback of endodontically treated teeth while 28.8% of them responded endodontic failure. This is similar to the findings of study conducted by Akbar I in 2015 [19]. About 83.3% of them agreed that quantity of remaining tooth structure, location of tooth in the arch, type of planned restoration affect the decision to place a post. These factors for choice of restoration were also mentioned in a study by Elagra 2019 [17]. About 43.6% of the respondents preferred prefabricated fibre reinforced post type. About 45.5 % of them preferred resin composite for core build up in case of the use of prefabricated post. This was similar to the results obtained from a survey conducted in Saudi Arabia (2015) [19]. This shows that the participants are familiar with the conventional post and core system.

The evolution of CAD/CAM systems have enhanced the options to produce single all ceramic endocrowns with high biocompatibility and optimal mechanical properties [23,24]. About 51% of the respondents are slightly aware of these endocrowns. Since premolars have a smaller adhesion surface leading to higher leverage than molars, these show less success rate than molars while restored with endocrowns. These endocrowns are contraindicated in cases with a short and narrow pulp chamber, if adhesion is not certain and if there is a very little tooth structure remaining. This was agreed by 44.4% of the respondents. About 30.4% of them responded that endocrowns are fabricated by their labs sometimes only. Less than half of the respondents preferred lithium disilicate endocrown to gain higher fracture resistance while zirconia was preferred by more participants.

Table 1: Questionnaire survey mentioning awareness , knowledge and attitude towards endocrowns

S.No.	Questions
1	What is your preferred line of treatment for Endodontically treated teeth with >50% remaining sound tooth structure?
2	What is your preferred line of treatment for Endodontically treated teeth with 50% remaining sound tooth structure?
3	What is your preferred line of treatment for Endodontically treated teeth with <50% remaining sound tooth structure?
4	Have you encountered patients who complain of frequent dislodgement of crowns on endodontically treated teeth?
5	What do you think is the most frequent drawback of Endodontically treated teeth?
6	Which one of the following would you prefer for Endodontically treated teeth in a bruxism patient?
7	Do you consider mechanical stress while restoration of posterior tooth?
8	How often would you estimate that you place a post in endodontically treated teeth?
9	Do you think the decision to place a post is affected by quantity of remaining tooth structure, location of tooth in the arch, type of planned restoration?
10	Does the post reinforce endodontically treated teeth and reduce fracture probability?
11	What is your preference for the type of post?
12	If you use a prefabricated post, which material would you use for core buildup?
13	Are you aware of endocrowns?
14	Do you think endocrowns are more resistant to compressive forces than conventional crowns?
15	Does your lab fabricate endocrowns?
16	Are you aware that endocrown is described as a monolithic (onepiece) ceramic bonded construction that invades pulp chamber?
17	Which material would you prefer for endocrown to gain higher fracture resistance?
18	Do endocrown take support from root canals?
19	What type of margin is required for endocrown preparation?
20	What is/are the contraindication for endocrown?
21	Do you take patient’s opinion while choosing the shade for endocrown?
22	Do you think endocrowns with ceramic occlusal thickness of 5.5 mm have fracture resistance twice as much as ceramic crowns which has occlusal thickness of 1.5 mm
23	Do you think the following are the adhesive steps on lithium disilicate endocrown? 1. Acid etching the intaligo surface of endocrown ,then washed off with water syringe and dried off 2. Application of silane 3. Applicaton of bonding agent 4. Light curing of bonding agent
24	Which one of the following would you prefer to cement zirconia endocrown?
25	Would you prefer endocrowns over post and core restorations for endodontically treated teeth?

Sample Size for Frequency in a Population

Population size(for finite population correction factor or fpc)(N): 1000
 Hypothesized % frequency of outcome factor in the population (p):66.35%+/-5
 Confidence limits as % of 100(absolute +/- %)(d): 5%
 Design effect (for cluster surveys-DEFF): 1

Sample Size(n) for Various Confidence Levels

ConfidenceLevel(%)	Sample Size
95%	256
80%	129
90%	195
97%	297
99%	373
99.9%	492
99.99%	576

Equation

Sample size $n = [DEFF * Np(1-p)] / [(d^2 / Z^2_{1-\alpha/2} * (N-1) + p*(1-p)]$

Figure 1: Sample size for frequency in a population

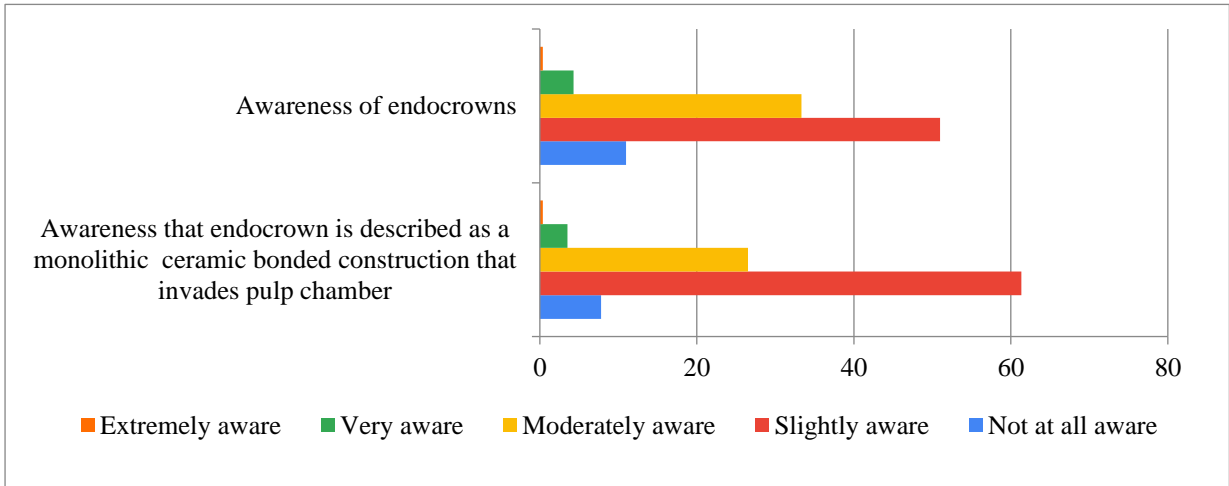


Figure 2: Awareness towards endocrowns among dental practitioners

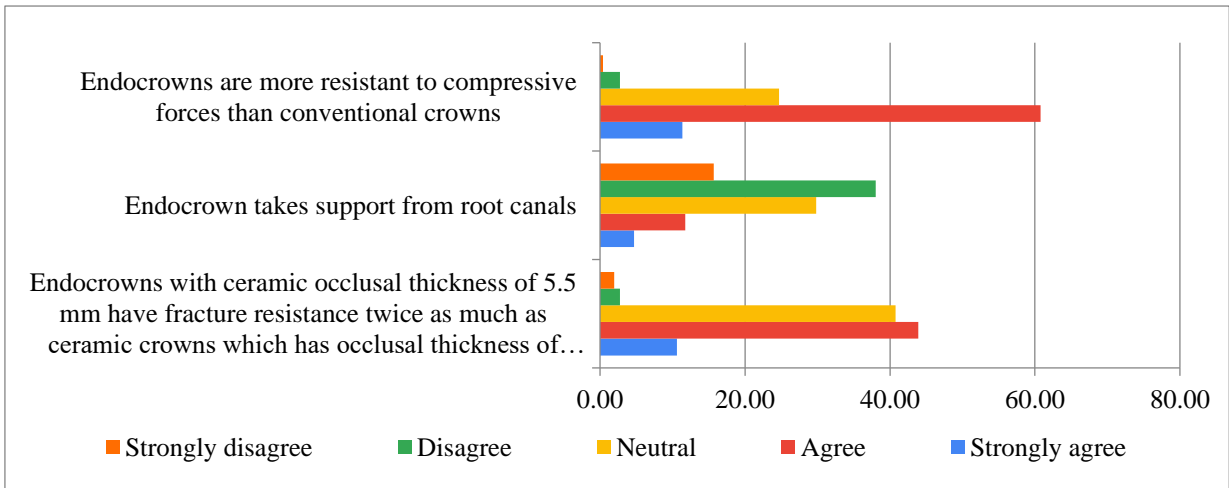


Figure 3: Knowledge towards endocrowns among dental practitioners

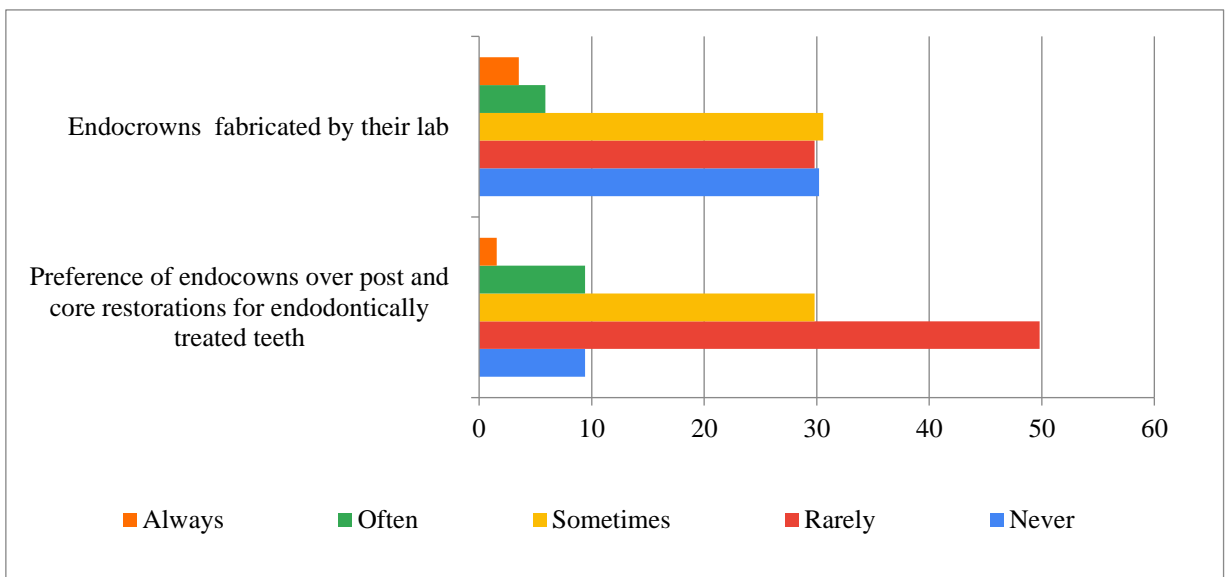


Figure 4: Attitude towards endocrowns among dental practitioners

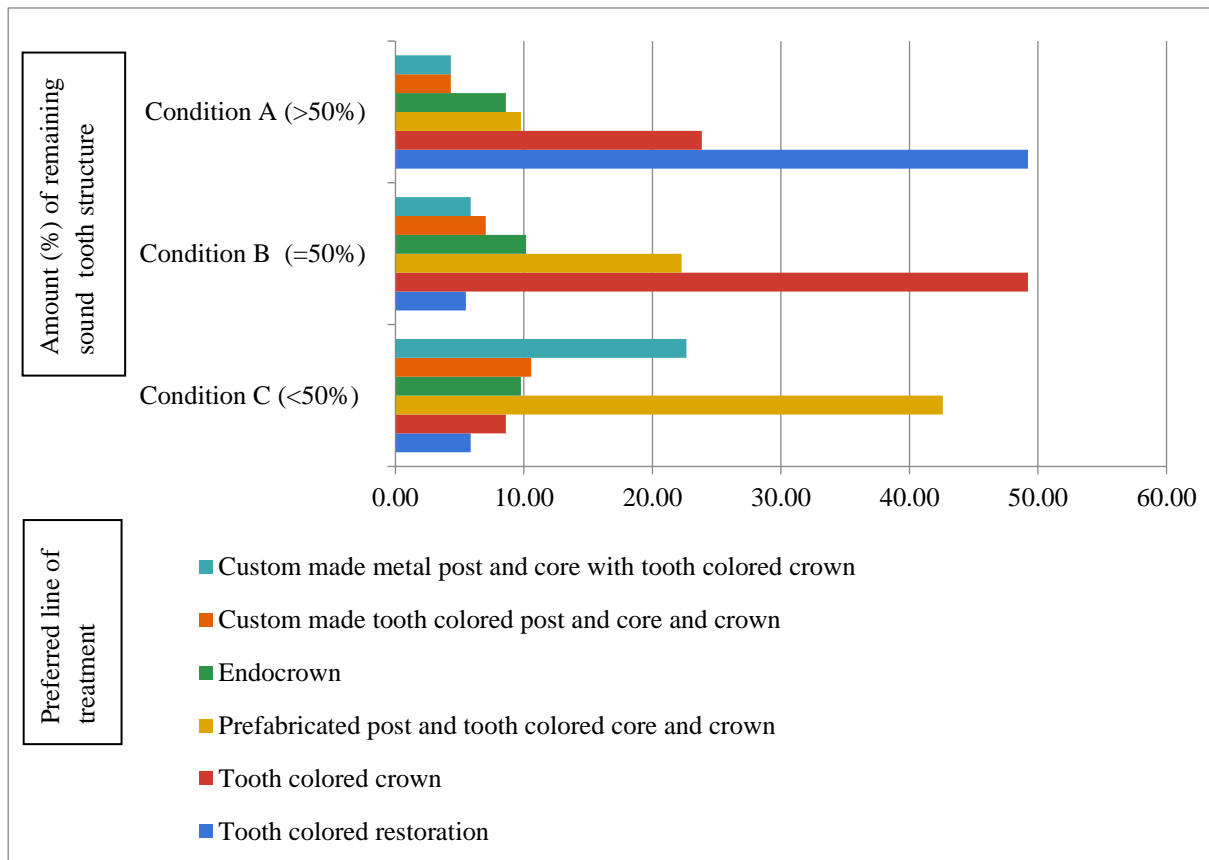


Figure 5: Attitude towards endocrowns among dental practitioners about amount of remaining sound tooth structure

The preparation design for endocrown is as follows, preparation of central retention cavity into the entire pulp chamber. Almost half of the participants know that it does not take support from root canals. A minimum of 2mm occlusal height reduction need to be attained in the axial direction. The ceramic occlusal thickness is usually 3-7 mm. Studies indicated that the fracture resistance of all-ceramic restorations rises with the increase of occlusal thickness and that endocrowns with 5.5 mm thickness fracture resistance is twice as much as ceramic crowns with 1.5 mm occlusal thickness.[17] 44.4% of the respondents agreed this. The cervical sidewalk is the foundation of the restoration, the objective is to accomplish a wide, uniform, steady surface resistant to compressive stress.[17] More than half of the participants agreed that the endocrowns are more resistant to compressive forces than conventional crowns. The supragingival butt joint is made to improve adhesion which 43.2% of the respondents are aware of. The preparation has to be parallel to the occlusal surface to ensure stress resistance along the long axis of the tooth.[17] Buccal and lingual walls need to be reduced. Interocclusal clearance of 2 mm has to be

achieved. Impression has to be made with polyvinylsiloxane impression material. Then, it has to be fabricated either by CAD/CAM technology or pressable ceramic technology. The fabricated endocrowns has to be checked for occlusion. And resin luting cement has to be used for cementation, which 48.24% of the participants preferred. About 42% of the participants agreed that the following are the adhesive step on lithium disilicate endocrown; 1. Acid etching of the intaligo surface of endocrown, then washed off with water syringe and dried off ; 2. Application of silane ; 3. Application of bonding agent ; 4. Light curing of bonding agent. About 47.5% preferred resin cement for cementation of zirconia endocrown. Almost half of the respondents rarely preferred endocrowns over post and core restorations for endodontically treated teeth. A former case report by Carlos et al (2013) revealed that no secondary caries, fracture, discoloration or loosening/ decementation of the crown was noted on clinical and radiographic evaluation over a 28-month follow up of endocrowns .[23] GT Rocca et al(2013) reported that Fibre – reinforced resin coating of endocrowns

reduced the risk of extensive fractures and improved the success rate of endocrown restoration on nonvital teeth [25].

In 2017, Vinola et al presented a case report of metal-ceramic endocrown, in which retentive grooves (1 mm deep) were placed to improve the retention and stability of the restoration.[26] The merits of Endocrowns over conventional crowns are; highly aesthetic, superior fracture resistance, less stress concentration, lesser clinical visits. They have an easier conservative preparation design compared to the traditional crown, maintaining the biologic width. The bonding surface offered by the pulpal chamber of the endocrown is frequently equal or indeed superior to that attained from the bonding of a radicular post of 8 mm depth as well as the application and polymerization of resins can be controlled. These adhesive restorations can decrease the infiltration of microorganisms from the coronal to the apical part therefore improve the clinical success of endodontic treatment. Belle flamme et al., in 2017 have stated that even in the presence of occlusal risk factors such as bruxism or any unfavorable occlusal relationships, endocrowns could be an approach to restore severely damaged molars and premolars [27]. This was agreed by only 21.8% of the respondents. The demerits of Endocrown are; debonding and risk of root fracture, since there is a difference in the modulus of elasticity between the harder ceramic and softer dentin. Hence case selection need to be concentrated to gain clinical success with Endocrowns.

4. Conclusion

From this survey, it is evident that the participants need to gain more awareness, knowledge towards endocrowns. Also , less number of dentists prefer endocrowns over conventional post and core system while dealing with an extensively damaged endodontically treated teeth. This need to be addressed. The concept regarding all ceramic systems, adhesive dentistry, endocrowns need to be included in seminars, CDE programmes to enhance the knowledge on endocrowns , so that we can implement it in our clinical practice to achieve best results. Since this survey was constricted to small population of dentists in a specific region, the study may have its limitations, which can be overcome by further studies.

References

- [1] D. McComb. Restoration of the endodontically treated tooth. Royal College of Dental Surgeons of Ontario. Ensuring Continued Trust. 2008; 22(1):1-20
- [2] M. Naumann, F. Blankenstein, T. Dietrich. Survival of glass fibre reinforced composite post restorations after 2 years—an observational clinical study; Journal of Dentistry (2005) 33, 305–312.
- [3] G.T. Rocca, I. Krejci. Crown and post-free adhesive restorations for endodontically treated posterior teeth: from direct composite to endocrowns, The European Journal of Esthetic Dentistry (2013); 8(2):156-179
- [4] D.J. Caplan, J. Kolker, E.M. Rivera, R.E. Walton. Relationship between number of proximal contacts and survival of root canal treated teeth. Int Endod J. 2002 Feb; 35(2):193-9.
- [5] D.E. Vire. Failure of endodontically treated teeth: Classification and evaluation. Journal of Endodontics, 1991 July; 17(7): p.338-342
- [6] S. Tabassum, F.R. Khan. (2016). Failure of endodontic treatment: The usual suspects. European journal of dentistry, 10(01), 144-147.
- [7] M. Soliman, L. Alshamrani, B. Yahya, G. Alajlan, A. Aldegheishem, E. Eldwakhly. (2021). Monolithic endocrown vs. Hybrid intraradicular post/core/crown restorations for endodontically treated teeth; cross-sectional study. Saudi journal of biological sciences, 28(11), 6523-6531.
- [8] G. Krastl. 2013. Post endodontic Resto-ration: A Survey Among Dentists in Switzerland. Schweiz Monatsschr Zahnmed, 123(12), 1076-1082.
- [9] I. Heiling et al., Endodontic failure caused by inadequate restorative procedures: review and treatment recommendations. Journal of Prosthetic Dentistry. 2002, 87: p.674-678
- [10] H.T. Shillingburg. Preparations for Extensively Damaged Teeth; Fundamentals of Fixed Prosthodontics, 3rd edition; Quintessence India, 2002, 181-209
- [11] Ingle. Bakland; Restoration of Endodontically Treated Teeth; Endodontics, 5th Edition; Pmph USA Ltd, 2002, 913-950
- [12] A. Muttlib, N. Aidaniza, P. Azman, A. Najwa, Y.T. Seng, R. Alawi, Z. Ariffin (2016). Intrakanalna prilagodba kolčića ojačanih vlaknima u odnosu na lijevane nadogradnje. *Acta Stomatologica Croatica*, 50(4).
- [13] Stockton LW. Factors affecting retention of post systems: a literature review. Journal of Prosthetic Dentistry. 1999 Apr; 81(4):380-5.
- [14] M. Balkenhol B. Wöstmann , C. Rein, P. Ferger. Survival time of cast post and cores: A 10-year retrospective study. Journal of Dentistry. 2007 Jan; 35(1):50-8.
- [15] A. Peutzfeldt, A. Sahafi, E. Asmussen. A survey of failed post-retained restorations; Clinical Oral Investigations. 2008 Mar; 12(1):37-44.
- [16] J.A. Sorensen, M.J. Engelman. Effect of post adaptation on fracture resistance of endodontically treated teeth; Journal of Prosthetic Dentistry. 1990 Oct; 64(4):419-24
- [17] M. Elagra., Endocrown preparation: Review., International Journal of Applied Dental Sciences 2019;5(1): 253-256
- [18] G. Sevimli, S. Cengiz, M. Selcuk. Endocrowns Review. Journal of Istanbul University Faculty of Dentistry. 2015; 49(2), 57–63.
- [19] I. Akbar. Knowledge, Attitudes and Practice of Restoring Endodontically Treated Teeth by Dentists in North of Saudi Arabia, International Journal of Health Sciences (Qassim) 2015 Jan; 9(1):41-9
- [20] G.R. Biacchi et al., The endocrown: an alternative approach for restoring extensively damaged molars, Journal of Esthetic and Restorative Dentistry. 2013 Dec; 25(6):383-90
- [21] H. Dogui, et al., Endocrown: An Alternative Approach for Restoring Endodontically Treated Molars with Large Coronal Destruction, Hindawi

- Case Reports in Dentistry 2018 Volume, Article ID 1581952, 6 pages.
- [22] R. Sarkis-Onofre, T. Pereira-Cenci, N.J. Opdam, F.F. Preference for using posts to restore endodontically treated teeth: findings from a survey with dentists. *Brazilian Oral Research*. 2015; 29 (1), 1–6.
- [23] R.B. Carlos, M. Thomas Nainan, S. Pradhan, R. Sharma, S. Benjamin, R. Rose. (2013). Restoration of endodontically treated molars using all ceramic endocrowns. *Case reports in dentistry*, 2013.
- [24] V. Veselinovic, A. Todorovic, D. Lisjak, and V. Lazic, “Restoring endodontically treated teeth with all ceramic endo-crowns case report”; *Dental Gazette of Serbia*. 2008; vol.55, pp. 54–64.
- [25] G.T. Rocca, N. Rizcalla, I. Krejci. Fibre-reinforced Resin Coating for Endocrown Preparations: A Technical Report., *Operative Dentistry*, 2013, 38-3, 242-248
- [26] S.M.J. Vinola, S. Balasubramanian, S. Mahalaxmi. “Endocrown”- An Effective Viable Esthetic Option for Expurgated Endodontically treated Teeth: Two Case Reports., *Journal of Operative Dentistry & Endodontics*. 2017; 2(2):97-102.
- [27] M.M. Belleflamme, S.O. Geerts, M.M.Louwette, C.F. Grenade, A.J. Vanheusden, A.K. Mainjot. (2017). No post-no core approach to restore severely damaged posterior teeth: An up to 10-year retrospective study of documented endocrown cases. *Journal of Dentistry*, 63, 1-7.