

Comparison between Intramedullary fixation vs transverse pinning by Kirchner wires for treatment of displaced metacarpal fractures

Abobakr Hasan Mohammed Ismail^{1}, Mohammed Osama Hegazy², Nagy Ahmed Zaky*

Saber³, Ahmed Shaban Hassan⁴

¹*M. B. B. Ch (Al-Azhar University, 2017)*

²*Professor of Orthopedic Surgery, Faculty of Medicine – Banha University, Egypt.*

³*professor of orthopedic surgery, Misr University for science and technology, Egypt.*

⁴*Lecturer of Orthopedic Surgery, Faculty of Medicine – Helwan University, Egypt.*

Abstract

The metacarpals shaft fracture is one of the most common fractures in the body, it represents about 10% of all body fractures and about 18-44 % of upper limb fracture, especially in young people. Many methods were prescribed to manage metacarpals shaft fractures, but the k-wires are the most common method used in fracture fixation due to less soft tissue damage and fewer complications. The aim of this study was to compare the results & complications of transverse pinning versus intramedullary pinning in metacarpal shaft fractures. A prospective study was held in Badr University Hospital and Abo Khalifa Emergency Hospital, including 28 patients divided into two groups. 14 cases were treated by intramedullary K-wire & 14 by transverse pinning. During the period from September 2022 to August 2023. There was no statistically significant variation among the two groups after adjusting for all confounding factors, confirming their general homogeneity. There's no statistically significant variation among both study groups according to the parameters of the non-controllable variables (age, gender, and side). (P value > 0.05). Both tow group of fixations the antegrade intramedullary K-wiring and transverse pinning demonstrate excellent and comparable results for shaft metacarpal fractures. However, the former is superior to intramedullary in terms of final range of motion as per ASSH TAM score.

Keywords: Intramedullary fixation, transverse pinning, Kirchner wires, displaced metacarpal fractures.

Full length article *Corresponding Author, e-mail: Ismail@fmed.bu.edu.eg

1. Introduction

The metacarpal bones fractures are one of the most orthopedic injuries, it represents about 10% of all body fractures and about 18-44 % of upper limb fracture, the metacarpals fractures are common in men in the second and third decades of life, fourth and fifth metacarpal shaft are the most common metacarpal fractures [1]. The majority of fractures are the result of accidental falls or multi-trauma injuries sustained in motor vehicle collisions. Or direct blow to a rigid object, or assault-related injuries [2]. Several metacarpal fractures are treatable without surgery with proper reduction and immobilization. Anatomic & stable reduction, bone union, and early mobilization are the key aims in the treatment of a hand fracture, as they are in the treatment of any other fracture. Treatment that is timely and allows for early range of motion improves functional outcomes [3].

Good functional outcomes have been reported with conservative management, which is why not all metacarpal fractures require surgical intervention. Most metacarpal fractures heal without surgery because they are relatively stable. Only eight percent of all metacarpal fractures are stable. The metacarpal bones that had less than 10–20° shaft angulation of the index and longer fingers, 30° of the ring fingers, and 40° of the little fingers wouldn't affect hand function. Therefore, they are not worthy of surgical fixation. Surgical fixation is also advocated for such fractures that have severe shaft angulation or rotation [4]. Fixation of such fractures can be accomplished in a number of ways. Intramedullary wires were what Foucher suggested, but Berkman and Miles came up with the idea of transverse pinning, in which wires are put at an angle between two metacarpals that are next to one another [5-6].

The purpose of this research was to examine whether or not metacarpal shaft fractures fared better when treated with transverse pinning or intramedullary pinning.

2. Patients and methods

A prospective research study was held in Badr University Hospital and Abo Khalifa Emergency Hospital, including 28 patients divided into two groups: 14 treated by intramedullary K-wire & 14 treated by transverse pinning. A written consent was obtained, and the patients were informed about the surgical procedure and expected complications. All of the patients were monitored for a minimum of eight weeks, and the maximum number of weeks that any of the cases were monitored was twelve.

2.1. Inclusion criteria

- Age: 18–65 years old.
- Gender: both male & female.
- Onset: acute fracture and displaced diaphysis fracture.

2.2. Exclusion criteria

Patient with an old fracture, acute infection, pathological fractures associated with neurovascular injuries, open fractures, and head and neck and base fractures

2.3. Methods

Methods of diagnosis History taking (personal history and mode of trauma), physical examination, and radiographic evaluation (standard lateral, posteroanterior (PA), and oblique X-rays)

2.3.1. Surgical technique Position

All patients had surgery while lying down in a supine position with the injured hand placed on the radiolucent table perpendicular to the body of the patient

2.3.2. Anesthesia

It had been done under general anesthesia, a nerve block, or a brachial plexus block.

2.3.3. Intraoperative fluoroscopy

Intraoperative imaging (C-arm) was a prerequisite and was used for all cases throughout the procedure.

2.3.4. Intramedullary K Wire

In order to get access to the intramedullary canal, a small incision, was made just proximal to the base of the metacarpal. Next, a hole was drilled through the dorsal cortex of the bone while the drill was pointed distally. The metacarpal fracture was closed reduction by traction of the fracture, as well as the Jahss procedure for neck fractures. This helped correct the rotational deformity. An anatomical reduction can be achieved with the percutaneous application of a reduction clamp in certain types of fractures, such as spiral fractures or oblique fracture. After the reduction has been checked off using the image intensifier, the percutaneous fixation with two K-wires measuring mm is carried out. The initial K-wire has one of its ends bent in order to control the direction in which it is introduced, and the T handle is then used to push it into the medulla. After passing through the medullary canal one at a time, the two

wires are positioned in opposite orientations, creating a "flower bouquet" effect in the metacarpal head. After the K-wires were cut, a final fluoroscopic check was performed to ensure the fracture was adequately fixed, and a clinical check was performed to ensure the finger was in the correct rotational position when fully extended and partially flexed. To aid soft tissue healing, a short arm splint was worn in an intrinsic plus position (80 degrees of metacarpophalangeal joint flexion & full extension of the interphalangeal joints) for 14 days.

2.3.5. Transvers Pinning

A small incision was made at the medial aspect of the hand as in the 4th and 5th metacarpal fractures and at the lateral aspect as in the 1st, 2nd, and 3rd metacarpal fractures of the hand, one or two incisions are made close to the fracture site, and one or two incisions are made further away from the fracture site. Traditional methods of reduction, such as traction & fracture manipulation of the Jahss maneuver for neck fractures, were used to close the fractures; a reduction clamp may have been used percutaneously in more complex cases, such as those involving spiral or oblique fractures, to achieve a more anatomical reduction. Percutaneous K-wire fixing is performed once reduction is confirmed with an image intensifier. The drill was used to insert the K-wires; two wires were inserted from the medial cortex to the adjacent metacarpal, then the other two wires were inserted proximal to the fracture site to the adjacent metacarpal under the image of the C-arm. After fixation, the stability of the fracture and rotational deformity of the fingers were checked, and a short arm splint was applied. in an intrinsic plus position (80 metacarpophalangeal joint flexion & full interphalangeal joint extension) for 14 days for the purpose of promoting the healing of soft tissue.

2.4. Statistical analysis

SPSS version 21 (SPSS Inc., Chicago, IL, USA) was used to process the collected data. Quantitative data were displayed as means \pm (SD), whereas qualitative data were displayed as figures and percentages (%). In order to evaluate whether or not there was a significant difference between quantitative variables, the student t test was carried out, Chi Square, on the other hand, was used to analyze the significance of variations between qualitative variables. A probability value (p-value) less than 0.05 was deemed statistically significant.

3. Results

During the period from September 2022 to August 2023, this study was carried out as an interventional prospective study on 28 patients with shaft metacarpal fractures who were candidates for surgical intervention and had a postoperative 8-week follow-up. The investigation was carried out in the orthopedic surgery department of Badr University Hospital and Abu Khalifa Emergency Hospital. The general homogeneity of both groups was confirmed because there was no statistically significant variation among the both groups when all non-controllable variables were considered. The mean age of the patients who underwent fixation transverse wires was 34.43 years with SD \pm 14.48, ranging from 19 to 62.

While in the intramedullary group the mean age was 38.86 years with SD \pm 13.61, ranging from 20 to 60. In the transverse wire group, 64.3% of patients were males, while in the intramedullary group, 71.4% were males. In the transverse wire group, 71.4% of patients had a fracture in the dominant hand and 64.3 had a right-hand fracture, while in the intramedullary group, 78.4% had a fracture in the dominant hand and 71.4 had a right-hand fracture. There's no statistically significant variation among the 2 study groups according to the parameters of the non-controllable variables (age, gender, and side). (P value > 0.05) (Table 1).

3.1. Mechanism of injury

The main cause of metacarpal fracture was direct trauma, which represents 44% in both groups; the second cause was falling on an outstretched hand, which represents 42% in the transverse group and 28% in the intramedullary group; and the RTA is the third cause, which represents 14% in the transverse group and 28 % in the intramedullary group (Figure 1). Metacarpal affected: In our study, the 4th and 5th metacarpals were the most affected bones; they represented the majority of cases, while the first metacarpal was the least affected bone, as illustrated in the next chart (Figure 2). The patients were clinically assessed based on TAM and VAS. In the patients who were fixed with transverse k-wires, the mean TAM was 104.64 ± 10.09 with a range from 90 to 120, and the mean VAS was 7.57 ± 1.28 with a range from 6 to 9. While the patients who were fixed with intramedullary wires had a mean TAM of 109.64 ± 9.09 with a range from 95 to 120, the mean VAS was 7.14 ± 1.07 with a range from 6 to 9. The variation among 2 study groups was statistically insignificant according to the preoperative clinical assessment and ROM at 3 months evaluation (P value > 0.05) (Figure 3).

3.2. Operative time

The average operative time in the intramedullary group was 25.36 ± 6.03 min with a range of 20 to 40 while in the transversal group it was 29.29 ± 6.46 min with a range of 20 to 40.

3.3. Time to union

The mean time to heal was 7.43 ± 1.02 with a range from 6 to 9 weeks, while in the intramedullary group it was 7.14 ± 0.95 with a range from 6 to 9 weeks.

3.4. DASH Score

There's no significant variation among the 2 groups with a p value > 0.05.

3.5. Outcome

The final outcome was assessed after fracture healing: in the patients who were fixed with transverse k-wires, the mean TAM was 243.21 ± 10.85 with a range from 230 to 260, and the mean VAS was 1.07 ± 0.92 with a range from 0 to 3. While the patients who were fixed with intramedullary wires had a mean TAM of 250 ± 8.55 with a range from 235 to 260, the mean VAS was 1.21 ± 1.05 with a range from 0 to 3. There was no loss of reduction or deep infection in both groups. On pin tract infection was found 2 (14.3%) in each group.

3.6. Case presentation

3.6.1. Case 1: Intramedullary fixation

Male Patient 21 year's student came to the E.R. of Abu Khalifa Hospital complaining of pain and swelling of the right dominant hand after falling on the ground. By examination, localized tenderness over the 3rd and 4th metacarpal bones and diffuse swelling on the dorsum of the hand were found; a slight rotational deformity of the 3rd and 4th fingers was noticed (Figure 4); and the patient was neurovascularly intact. PXR showed spiral fractures of the 3rd and 4th metacarpal shafts with 30-degree angulation & shortening (Figure 5). Surgical fixation of the 3rd & 4th metacarpal fractures was done using intramedullary k-wires (Figure 6).

3.6.2. Case 2: Transvers fixation

Male patient 22 years old, driver, comes to the ER of Abu Khalifa emergency hospital complaining of pain and swelling of the left hand after direct trauma to the hand. By examination, there is localized tenderness and edema over the 4th metacarpal bone of the left hand, and there is a slight rotational deformity of the 4th finger. The neuromuscular system is intact (Figure 7). The x-ray revealed a spiral fracture of the shaft of the 4th metacarpal bone (Figure 8). Surgical fixation of the 4th metacarpal bone was done using the Transverse K. Wine Technique (Figure 9).

4. Discussion

In this research, 28 cases with metacarpal shaft fractures were involved. Patients were followed up over the course of three months. K-wires (1 mm to 1.2 mm k-wires) were used. Below the elbow volar slab for 2 weeks was used for all cases, and active ROM was allowed starting from the third week after fixation. Pin removal was done after 6 weeks. All cases returned to their pre-injurious jobs & activities. The homogeneity of both groups was established according to age, sex, dominant hand, and site of fracture, and there was no significant variation among both groups based on these uncontrollable variables. The age distribution in the current research study was comparable to that observed by Nakashian et al., (2012) who discovered that prevalence peaked between the second and third decades of life. This may be attributed to the active lifestyles and increased participation in cultural & athletic activities of individuals in this age group [6]. The gender distribution was discovered to be the same as that of Nakashian et al., (2012) with males accounting for most in the 2nd and 3rd decade and the male-female ratio being the same as in cases above fifty years of age. It's possible that the increased prevalence of osteoporosis in women after menopause is to blame for the increased frequency of fractures in older women who are female and over the age of fifty. In the current investigation, the leading cause of metacarpal fractures was shown to be direct trauma as well as falling on an extended hand [6]. This was comparable to the findings of Gudmunsen & Borgen (2009), who discovered that the most frequent reason for metacarpal fractures was impact with a wall or falling [7]. Transverse K-wire fixation for metacarpal fracture stabilization can be used for all fracture locations and configurations. It was first described by Berkman & Miles.

Transverse K-wire fixation for metacarpal fracture fixation is a forgiving technique that can be used for all metacarpal fractures. It is easy to re-insert the pin if the fracture is not reduced to an acceptable level or if the pin location is incorrect. According to Fusetti et al., (2002) the main benefit of percutaneous transverse K-wire fixation is that it eliminates the problems associated with open reduction and internal fixation, such as delayed fracture healing, infection, stiffness due to extensive soft tissue dissection, later fibrosis and extensor tendon adhesion, plate loosening or breakage, and complex regional pain syndrome [8]. Bouquet osteosynthesis, also known as many wires were 31 intramedullary flexible wires repairing for metacarpal

fractures, was initially described by Foucher and has had exceptionally good results over the course of the past two decades. This technique is an open technique for anterograde intramedullary fixation, and it involves the insertion of three pre-bent Kirschner wires (K-wires) into the decreased metacarpal head in different directions. According to Fusetti et al., (2002) the primary benefit of percutaneous intramedullary K-wire fixation in the treatment of unstable metacarpal fractures is the avoidance of adverse effects that occur with open reduction and internal fixation, such as the fracture not healing, infection, stiffness due to extensive soft tissue dissection, later fibrosis and extensor tendon adhesion, and loosening of the plate [8].

Table 1: Basal Characteristics of Included Subjects.

		Intramedullary K-wires (N=14)	Transvers pinning (N=14)
Age		34.43 ±14.48 (19-62)	38.86 ±13.61 (20-60)
Sex	Male	9 (64.3%)	10 (71.4%)
	Female	5(35.7%)	4 (28.6%)
Site	Right	9 (64.3%)	10 (71.4%)
	Left	5(35.7%)	4 (28.6%)
Dominant hand	Dominant	10 (71.4%)	11 (78.6%)
	Non- dominant	4 (28.6%)	3 (21.4%)

P>0.05. There is no significant difference. [1]: T-Test; [2]: Chi Square Test

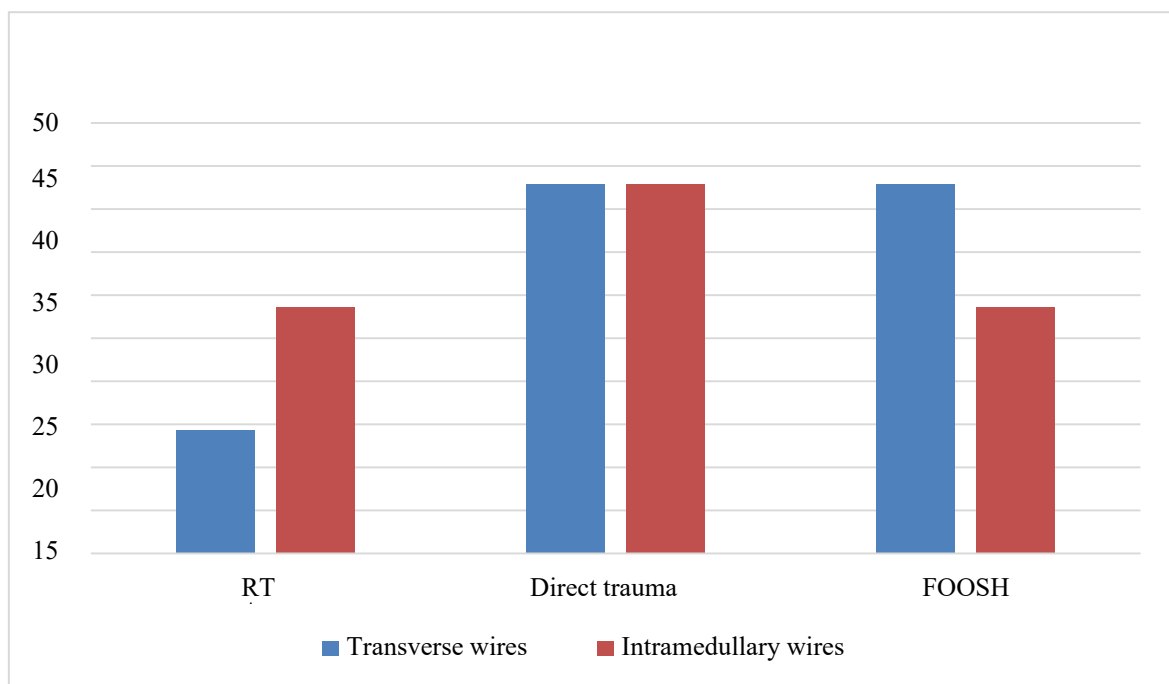


Figure 1: Mechanism of injury

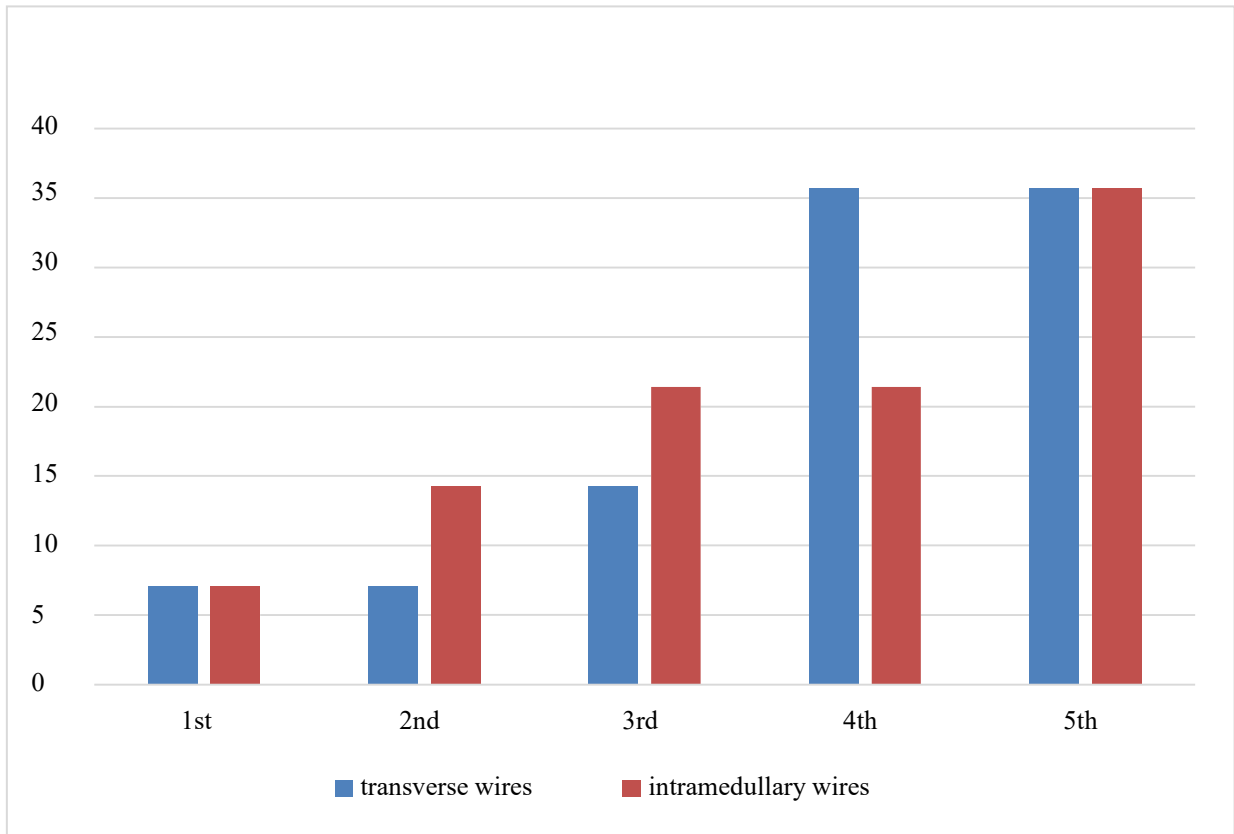


Figure 2: Pre-operative assessment.

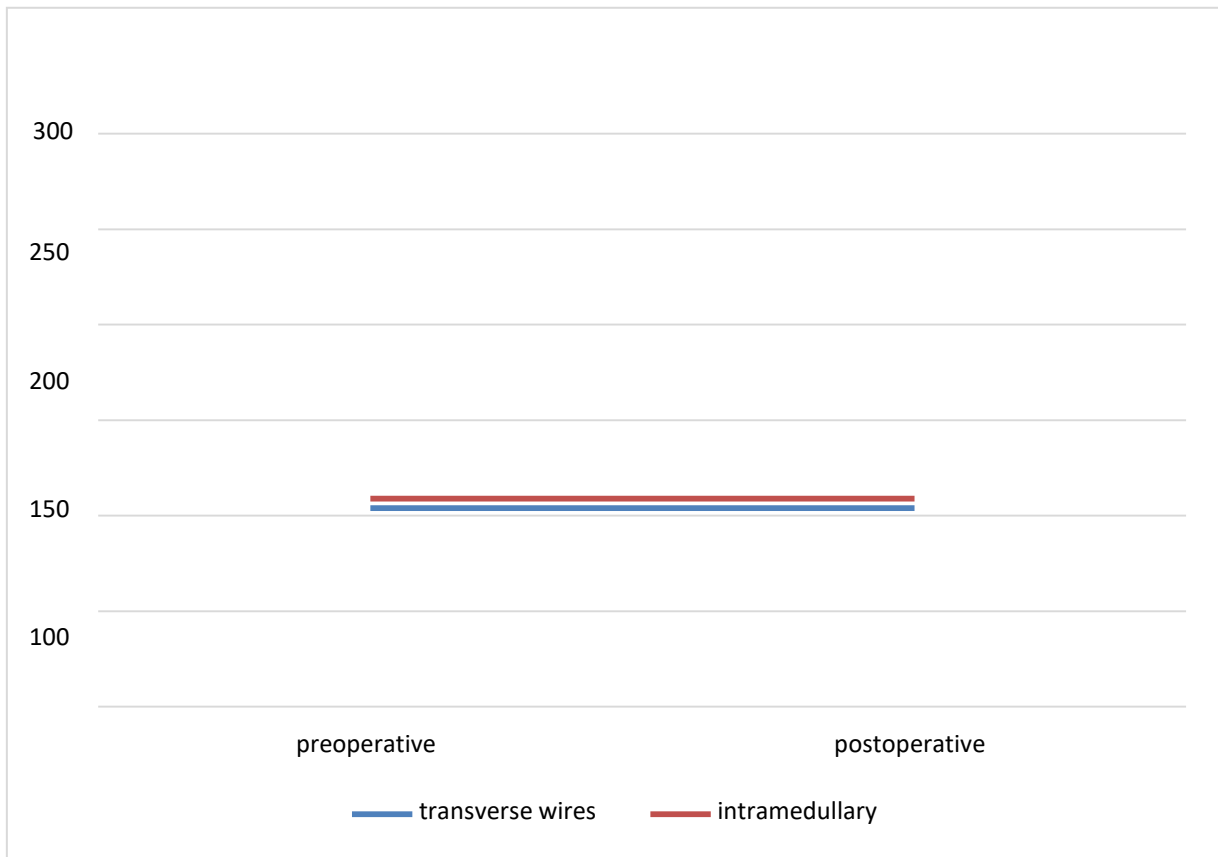


Figure 3: Complications.

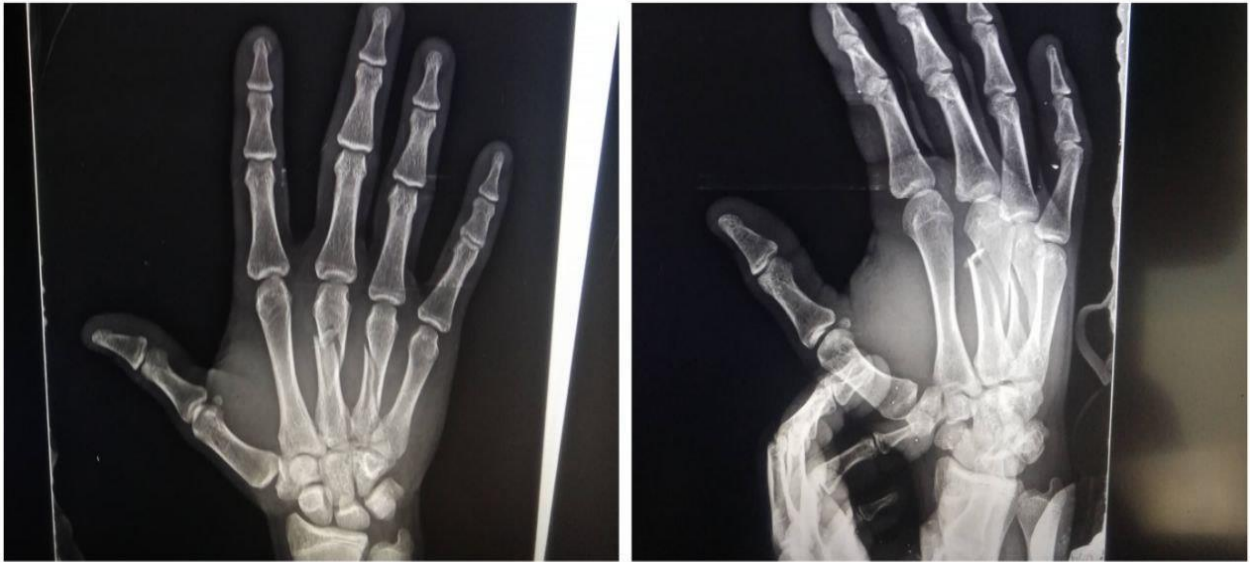

Figure 4: 29-year-old male patient with spiral fractures of the third and fourth metacarpals, A/P and oblique views.

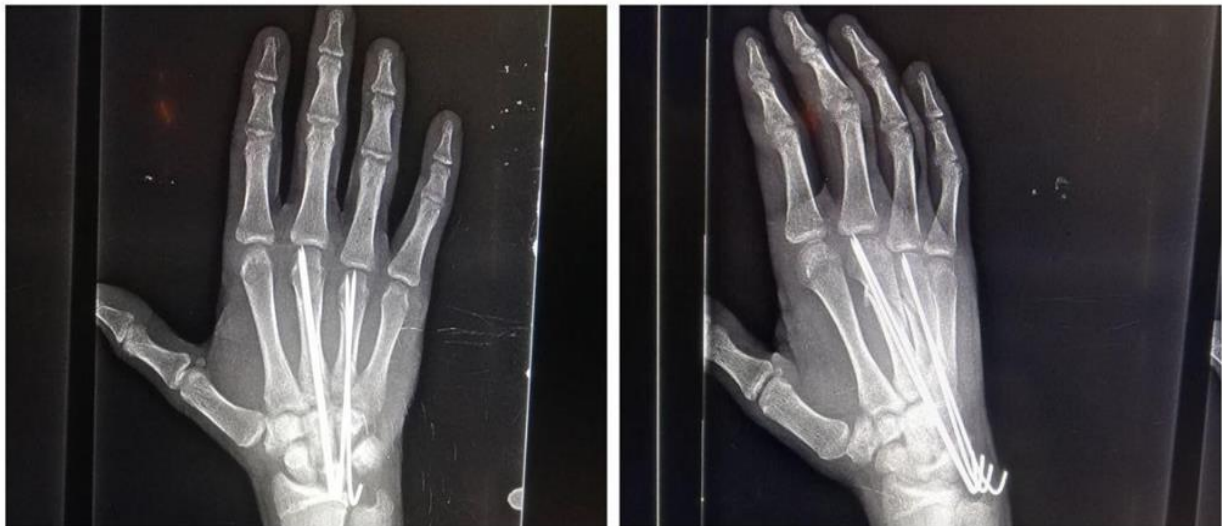

Figure 5: Early follow-up (4 weeks postoperative) x-rays (P.A., oblique, and lateral views) showed a stable uniting fracture.

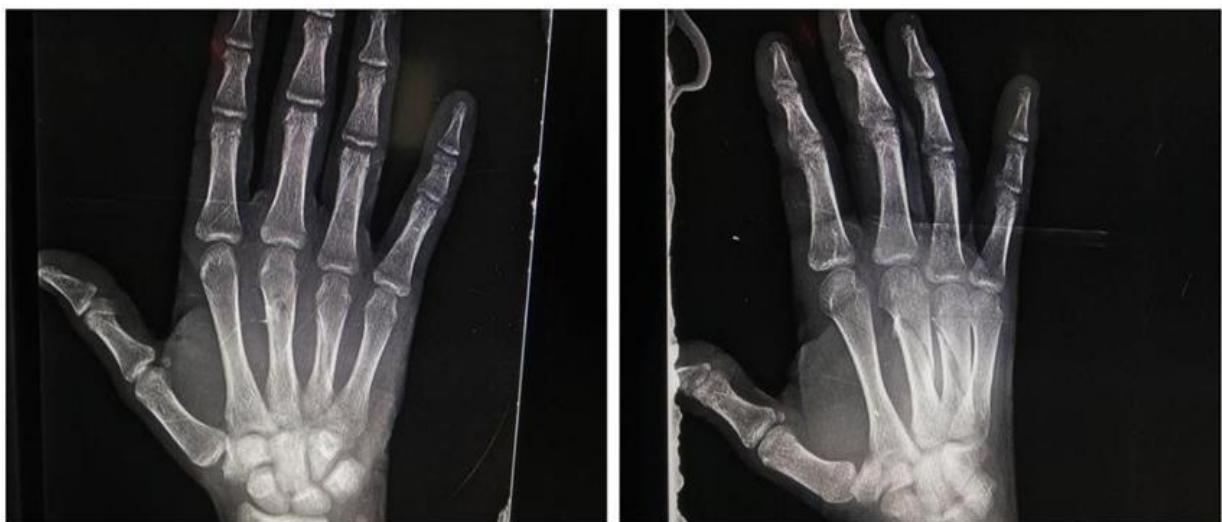

Figure 6: Showing stable united fracture after removal of the K-wires (8 weeks post-operative).

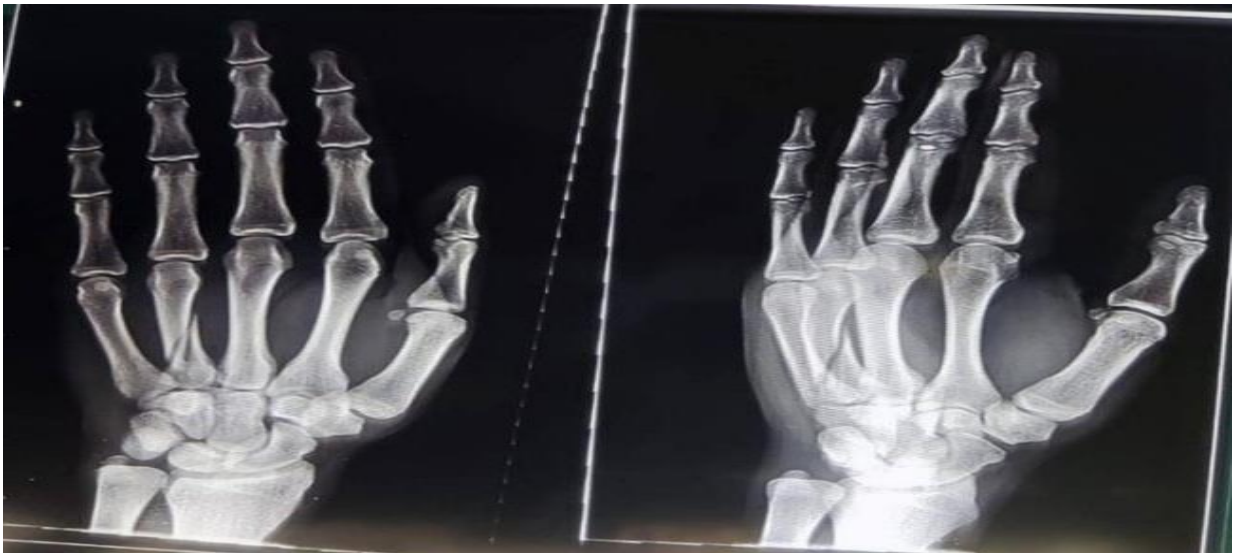

Figure 7: A 22-year-old male has a spiral fracture of the 4th metacarpal fracture.

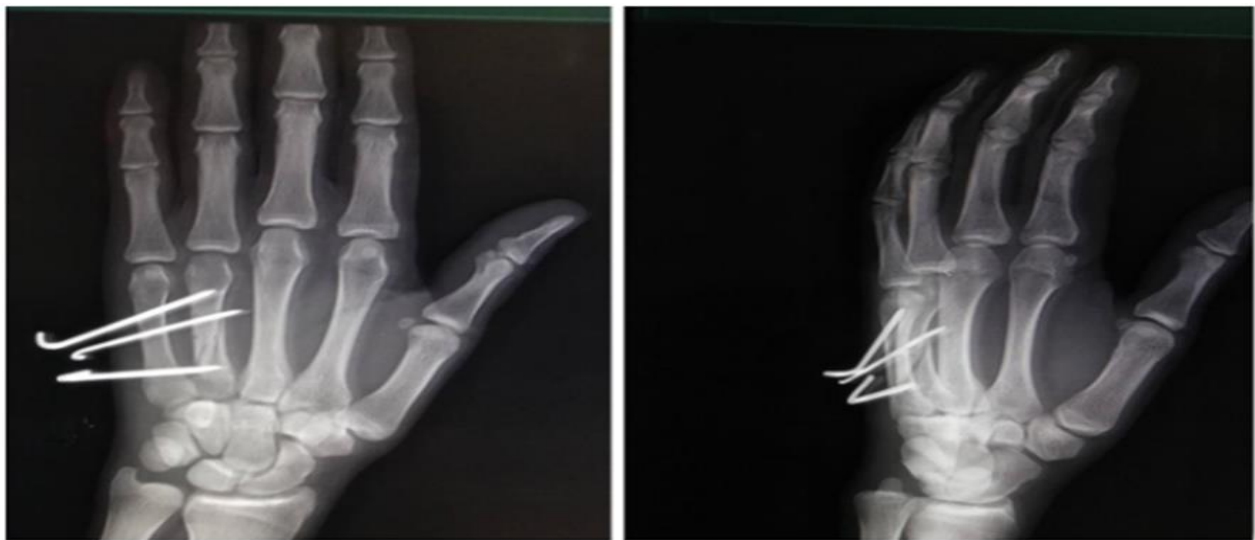

Figure 8: Late follow-up at the 4th week postoperative X-ray P/A & oblique views that show a stable uniting fracture.

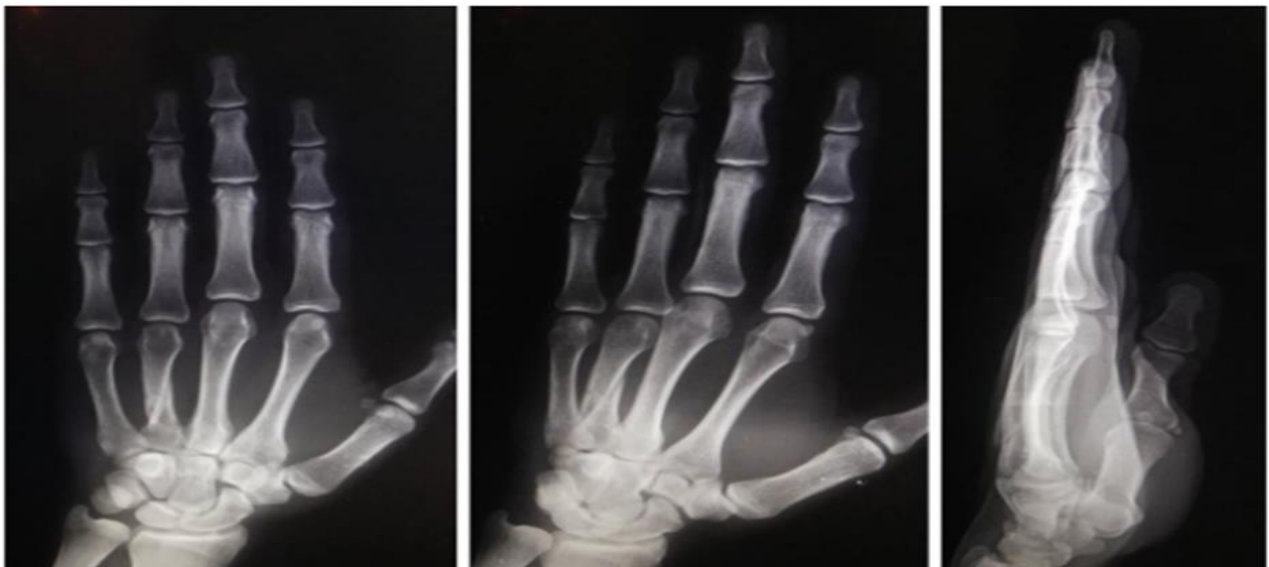

Figure 9: Plain x-ray at the 8th week post-operative after removal of k-wires shows a stable united fracture.

Sletten et al., (2015) managed 67 patients with fractures of the metacarpal with either intra-medullary pinning or transverse pinning. The clinical criterion for inclusion was a recent, isolated, closed fracture of the metacarpal bone, which is similar to our study. Forty-five underwent transverse pinning, and twenty-two underwent intramedullary pinning. Men were 88%, with a mean age of 30 (range 18–65), and 71 % of them had their dominant hand injured with an average follow-up of 17 months [9]. At final follow-up, most patients had 0 degree of pain on the VAS score in both groups, ranging from 0 to 4. The mean TAM was 262 in the intramedullary group and 264 in the transverse wiring group [9]. Only 12% of cases had superficial infections that were treated conservatively with antibiotics. No major complication or loss of reduction happened in the patients. Yaqub et al., (2002) managed 60 cases with fractures of the metacarpal with either intra-medullary pinning or transverse pinning. The clinical criterion for inclusion was a recent, isolated, closed fracture of the metacarpal bone with angulation or rotational deformity [10].

5. Conclusions

Both the intramedullary k wires and transverse pinning are minimally invasive techniques with the advantage of early postoperative rehabilitation and clinical, functional, and radiological recovery. Although the similar results were obtained with both techniques when assessed in terms of clinical and radiological recovery, the functional recovery however in terms of the final range of motion achieved as per ASSH TAM score was found to be superior with intramedullary pinning.

References

- [1] L. S. Urband, S. Wong, D. N. Cage. (2023). Diagnosis and Evaluation of Fractures of the Hand and Wrist. *The Art of the Musculoskeletal Physical Exam* (pp. 307-318). Cham: Springer International Publishing.
- [2] J. De Jonge, J. Kingma, B. Van der Lei, H. Klasen. (1994). Fractures of the metacarpals. A retrospective analysis of incidence and aetiology and a review of the English-language literature. *Injury*. 25 (6): 365-369.
- [3] M. W. Neumeister, K. Webb, K. Mckenna. (2014). Nonsurgical management of metacarpal fractures. *Clinics in Plastic Surgery*. 41 (3): 451-461.
- [4] S. Galal, W. Safwat. (2017). Transverse pinning versus intramedullary pinning in fifth metacarpal's neck fractures: A randomized controlled study with patient-reported outcome. *Journal of clinical orthopaedics and trauma*. 8 (4): 339-43.
- [5] S. D. Akinleye, G. Garofolo-Gonzalez, M. D. Culbertson, J. Choueka. (2019). Iatrogenic injuries in percutaneous pinning techniques for fifth metacarpal neck fractures. *Hand*. 14 (3): 386-92.
- [6] M. N. Nakashian, L. Pointer, B. D. Owens, J. M. Wolf. (2012). Incidence of metacarpal fractures in the US population. *Hand*. 7 (4): 426-30.
- [7] T. E. Gudmundsen, L. Borgen. (2009). Fractures of the fifth metacarpal. *Acta Radiologica*. 50 (3): 296-300.
- [8] C. Fusetti, H. Meyer, N. Borisch, R. Stern. D. D. Santa, M. Papaloizos. (2002). Complications of plate fixation in metacarpal fractures. *Journal of Trauma and Acute Care Surgery*. 52 (3): 535-539.
- [9] I. N. Sletten, J. C. Hellund, B. Olsen, S. Clementsen, H. D. Kvermmo, L. Nordsletten. (2015). Conservative treatment has comparable outcome with bouquet pinning of little finger metacarpal neck fractures: a multi-centre randomized controlled study of 85 patients. *Journal of Hand Surgery (European Volume)*. 40 (1): 76-83.
- [10] A. E. Yaqub, N. Singh, P. Tiwari, S. S. Jaura, B. S. Brar. (2002). Comparison of Antegrade Percutaneous Intramedullary K-wire Fixation and Transverse Pinning for Treatment of Unstable Displaced Metacarpal Neck and Shaft Fractures: A Prospective Interventional Study. *Journal of Clinical & Diagnostic Research*. 16 (8).