

Transforaminal Lumbar Interbody Fusion Technique for the Treatment of Degenerative Lumbar Disease

¹Ahmed Elsayed Nena, ²Mawada Ahmed Hassan Taha,

³Abuamar Zaidan, ^{4*}Moustafa Saad

¹ Department of trauma and Orthopedics, Cairo University, Egypt

² Dar Al Elaj Specialized Hospital, Egypt

³ Royal college of Surgeons of Edinburgh

⁴ Department of Trauma and Orthopedics, Benha university, Benha, Egypt

Abstract

Transforaminal lumbar interbody fusion (TLIF) is a procedural option to the spinal canal and anterior approach. By assessing the suitability using posterior instrumented transforaminal lumbar interbody fusion to treat symptomatic lumbar degenerative disease surgically. The research carried out at the Royal National Orthopaedic Hospital Stanmore London and the orthopaedics department of Benha University Hospital on twenty cases had symptomatic degenerative lumbar illness that had not responded to medicinal treatment. Clinical assessment was performed on every patient, which included Standing radiographs (antroposite and lateral views) of the lumbar spine, focusing on radiological markers of open instability. Following one year of surgery, the Oswestry Disability Index (ODI) and VAS were significantly decreased compared to baseline ($P < 0.001$, < 0.001). In the studied group, 17 individuals (15 %) reported a good rate of patient satisfaction, whereas 3 individuals (15 %) reported a poor rate of patient satisfaction. 18 (90 %) patients reported pain alleviation, whereas 2 (10 %) patients reported no improvement. The TLIF technique provides a safe, effective, simple approach to treating degenerative lumbar spine problems, resulting in significant enhancements in the quality of life and surgical satisfaction of patients.

Keywords: Degenerative Lumbar Disease, Oswestry Disability Index, Spine Disease Lumbar Interbody Fusion.

Full length article *Corresponding Author, e-mail: drmoustafasaad@fmed.bu.edu.eg

1. Introduction

To optimize the potential of fusion and maintain correct disc height, sagittal plane alignment, and capacity for supporting weight on the spine, interbody fusion procedures have been devised [1]. TLIF (transforaminal lumbar interbody fusion) is an alternate procedure to the anterior technique and the spinal canal approach. While theoretically feasible, it successfully mitigates many complications encountered during interbody fusion of the posterior and anterior lumbar spine. One benefit of this strategy is its straightforward execution in a unilateral fashion. This minimizes the extent of spinal instability and violation of the posterior elements, hence optimizing the stability of the fusion union. It also decreases the necessity for spinal nerve root manipulation and improves access to the neuroforamen. Retraction may therefore prevent nerve damage from transpiring [2]. In adults, stability and fusion of spinal deformities constitute the primary indication for

lumbar interbody fusion surgery[3]. Lumbar fusion has thus been characterized as a therapeutic approach for degenerative scoliosis, lumbar instability-associated stenosis, and symptomatic spondylolisthesis. Secondary indications including discogenic low back pain, recurrent lumbar disc herniation necessitating significant bone removal to expose herniation of a big or lateral disc, disc fragments, or previous lumbar fusions that failed alternative methods[4]. Herniation of a big or lateral disc, disc fragments, or previous lumbar fusions that failed alternative methods. The purpose of this study was to assess and analyze in symptomatic lumbar degenerative degeneration, evaluating the surgical effectiveness of posterior instrumented transforaminal lumbar interbody fusion [5].

2. Patients and Methods

This research included twenty patients with symptomatic degenerative lumbar illness who had not

exhibited any response to therapeutic interventions. of more than 40-year-old and had radiographic indications of either stable or unstable lumbar degenerative degeneration. This study had been carried out at the Royal National Orthopaedic Hospital Stanmore London and the orthopaedics department at Benha University Hospital. The study was conducted after approval by the Ethics committee of the Faculty of Medicine, Benha University Hospital, Egypt (Approval code:). A written informed consent was obtained from all participants. Exclusion criteria patients whose radiological documentation is incorrect or insufficient. All the studied patients underwent clinical evaluation Through comprehensive history taking and physical examination, particular emphasis should be placed on neurologic conditions, prior spinal procedures, gait disturbances, and any modifications to bodily habitus and posture, Lumbar spine standing radiography (Anteroposterior and lateral views) monitoring radiographic indicators of open instability while maintaining lumbar spine radiographs captured in a supine position (anteroposterior and lateral views) (cobbs angle above 10 degrees or lithium surpassing 3.5 mm). As determined by radiological techniques, Instability in Frank (lithesis above 3.5 mm or cobbs angle above 10 degrees).

2.1. Surgical approach

During anaesthesia induction, antibiotics were administered intravenously. All operative data regarding the operation was recorded, included the duration of the procedure, blood loss, anaesthesia, approach, and the state of soft tissue and muscles. The patients position was prone position on radiolucent operating table. Throughout the procedure, a fluoroscopy C-Arm was utilized. Standard posterior midline incision was utilized to access the spine. Screw pedicle insertion occurred either prior to or after to the interbody repair. The selection of the approach side was frequently predicated upon the scar tissue or site of the pathology. Utilizing a Kerrison rongeur, the inferior lamina of the cephalad vertebra was extracted, while a straight osteotome or a Kerrison rongeur was employed to resect its inferior articular process. While safeguarding the nerve root that traversed the intervertebral foramen, the process of superior articulation of the caudal vertebra was excised utilizing either a Kerrison or a straight osteotome. By performing a Kerrison punch to eliminate the protruding superior articular process and achieve complete disc exposure, the medial and cephalad margins of the pedicle were revealed. Bipolar cautery was utilized to conduct a comprehensive and thorough hemostasis over the exposed disc area. To establish a window into the disc space, a box annulotomy was executed. Pituitary rongeur was initially employed to eliminate loose nuclear tissue subsequent to box annulotomy. For the disc preparation, either an 8 mm starting dilator or a disc spreader was utilized. In order to facilitate optimal access for disc preparation and reconstruction, it is ideal that the end plates be parallel once distraction has been completed, maximizing the posterior openness of the disc area. A temporary rod or laminar spreader was utilized to sustain the opening of the disc gap between the spinous processes once distraction was achieved. Curettes, osteotomes, rongeurs, and shavers were employed in turn to execute the final discectomy In order to enhance visibility and facilitate access to the anterior

Nena et al., 2023

contralateral region of the disc, the posterior lip of the vertebral body flush with the endplates may be removed using an osteotome. A contralateral posterior corner of the disc space may be utilised in conjunction with an offset down-biting curette to facilitate the removal of disc material. Disc material can be extracted from the contralateral aspect of the disc area using a double-angled cup curette (left and right). With the inferior and superior endplates in mind, these curettes were purposefully created. For optimal interbody fusion, a substantial volume of bone graft was inserted into the disc space. Utilize the disc preparation package's assortment of straight and curved bone tamps to apply bone graft to the contralateral side and anterior third of the disc area. Utilizing cage testing to aid in the accurate selection of the implant was critical. A cage trial was used prior to insertion of the implant to evaluate potential cage placement and determine the optimal implant fit. The final position of the cage was checked by intraoperative X ray to confirm satisfactory position both in AP and lateral views.

2.2. Follow up

Following the operation, patients were attended for follow-up to return the hospital at four weeks, three months, six months, twelve months, and annually thereafter.

2.3. Statistical analysis

The statistical analysis was performed with SPSS version 28. (IBM Inc., Armonk, NY, USA). to express quantitative values, the mean and standard deviation were utilized (SD). Frequency and percentage were used to represent qualitative factors (%). When two samples are correlated, the paired sample t-test is a statistical method utilised to compare the means of the two populations.

2.4. Case (1)

Housewife patient, 42 years old, diagnosed with left-sided sciatica, L4/5 spondylolisthesis, and L5/S1 discectomy. The preoperative ODI score was 40, and the final follow-up ODI score was 29 (**Figure 1**).

2.5. Case (2)

60-year-old male diagnosed with Chronic LBP accompanied by bilateral limb claudication and increasing deformity in a. The preoperative ODI was 55, and the last follow-up was 39 (**Figure 2**).

3. Results

The mean age of the studied patients was 49.90 ± 5.524 years. The majority in male was 7(35%) while female cases were 13(65%). The mean weight was 72.60 ± 8.642 kg, the mean height was 167.27 ± 9.474 cm, and the mean BMI was 25.937 ± 2.183 kg/m². The comorbidities of the patients show that 3 cases (15%) had HTN, 4 cases (20%) had DM, 1 case (5%) had dyslipidaemia, and 1 case (5%) had cardiovascular (**Table 1**). Table 2 shows that the degenerated segment was, degenerated segment was L5/S1 in 5 cases (25%), L4/L5 in 20 cases (100%) and 3 cases (15%) had in multi levels. Regarding the spine disease, 6 cases (30%) patients had degenerative disc, 6 cases (30%) patients had spondylolisthesis, 3 cases (15%) patients had failed back surgery, 3 cases (15%) patients had degenerative scoliosis, 4 cases (20%) patients had lumbar canal stenosis and 2 cases (10%) patients had disc regeneration. The

duration of the surgical procedure varied from 1.5 to 3.5 hours, with a mean value 60 ± 0.620 hours. The blood loss varied from 160 to 345 ml, with a mean value of 248.75 ± 62.993 ml. The hospital stay varied from 4 to 7, with a mean value of 5.95 ± 1.146 days. The Oswestry Disability Index (ODI) and Visual analogue scale (VAS) were significantly decreased compared to baseline ($P < 0.001$, < 0.001) following one year of surgery (**Table 3**). Table 4 shows that Radiology findings of the studied group show that 18 (90%) had Disc restored, 11 (55%) had Solid fusion, 2 (10%) had Delayed union, 1 (5%) had Cage subsidence and 1 (5%) had Pseudarthrosis. Regarding complications, 2 (10%) had Persistent back pain, 3 (15%) had Infection, 1 (5%) had Neurological deficit and 1 (5%) had Pseudarthrosis. Satisfaction of the studied group shows that 17 (85%) reported being satisfied with the surgical outcome and 3 (15%) had poor satisfaction. Pain improvement was reported by 18(90%) and 2(10%) reported no pain improvement. The return to work of the studied group shows that 1(5%) didn't return to work, 15(75%) returned to their work and 4(20%) returned to their work but with light duties (**Table 5**).

4. Discussion

Fusion of both the anterior and posterior spinal columns is a feasible outcome of TLIF. While maintaining contralateral laminae, articular facets, and transverse processes that can serve as a posterolateral arthrodesis surface, the transforaminal approach should be unilateral, as per the original procedure. The TLIF treatment, which has been adopted as a minimally invasive spine surgical approach in recent years due to the development of advanced instrumentation and current imaging guidance, has demonstrated its superiority over traditional open surgery in terms of injury to spinal soft tissues [6]. While there is evidence that minimally invasive TLIF (mini-TLIF) is a safe and effective surgical treatment compared to traditional open surgical procedures, its superiority in managing lumbar degenerative pathology has not yet been established. This is due to the scarcity of literature presently comparing the two techniques [7] [8] Regarding the indication of surgery, Hassaan et al. [9] 90 % of patients presented with leg pain and 100 % presented with mechanical back pain, as indicated in their study. The current study reveals that 6 (30 %) of the cases required an operation for spondylolisthesis, 9 (45 %) for degenerative disc disease, 3 (15 %) for back surgery, and 4 (20 %) for lumbar canal stenosis. Our results are supported by study of Humphreys et al. [10] as the TLIF was a viable alternative to the PLIF due to its significantly reduced risk of complications, shorter operating time and hospitalisation, and substantial reduction in blood loss during the procedure. By reducing the risk of nerve root injury, the TLIF method eliminates arguably the most significant drawback of the PLIF method. In contrast to PLIF, TLIF was deemed the superior surgical technique for posterior operative therapy of symptomatic degenerative lumbar spine issues due to the loss of the case-specific benefits of TLIF in comparison to a combined anterior and posterior single-level fusion. After removing the case-specific advantages of TLIF over a combined anterior and posterior single-level fusion, TLIF was determined to be the superior surgical approach for posterior operative therapy of symptomatic degenerative lumbar spine difficulties, as Nena et al., 2023

opposed to PLIF. After removing the case-specific advantages of TLIF over a combined anterior and posterior single-level fusion, for posterior operative therapy of symptomatic degenerative lumbar spine complications, TLIF was found to be the superior surgical strategy compared to PLIF. In terms of pain improvement, pain was reported to have improved in 18 (90 %) of the participants, whereas it did not improve in 2 (10 %). The present study is supported by study of Deng et al. [11] as 83.5 % of patients reported an improvement in lumbar discomfort, compared to Mohammad's 90 % improvement. Hassaan et al. [9] study. The previous study [12] reported that In 70 % of the 81 patients, pain symptoms were alleviated, and 80 % of the patients reported good outcomes. According to the findings of the current study, patient satisfaction was rated poorly by 3 individuals (15%) and well by 17 (85%). Out of the cohort under investigation, pain improvement was observed in 2 individuals (10 %) and improved by 18 (90 %). Regarding the return to work of the investigated group, the data reveals that 5% of the participants did not recommence their duties, 75% (n=15) recommenced employment, and 20% (n=4) reduced their burden. Regarding the return to work of the examined group, the data reveals that 5% of the participants did not recommence their duties, 75% (n=15) recommenced employment, and 20% (n=4) reduced their burden. Our findings are consistent with study of Lowe and Tahermia [13] TLIF surgery was associated with a fusion rate of 95% radiologically and 88 % clinically favourable outcomes. Asil and Yaldiz [14] reported that in his study overall complication rate was 23.9%, dural injury rate was 9.9%, graft mal-position rate was 2.82%, and the screw mal-position rate was 4.23%. According to Xue et al. [15], In both groups, the average postoperative VAS and ODI scores improved statistically significant; regarding The overall rate of complications, screw failure, and complete fusion there was no statistically significant difference between groups. Audat et al. [12], There was no statistically significant difference between groups at different follow-up intervals, despite the fact that the ODI scores decreased statistically significant with time ($p < 0.005$). The equivalent radiographic fusion rates for Group I 91.9%, Group II 88.9%, and Group III 91.8%. According to this study [16] reported that in The TLIF group underwent a shortened time to walk, a shorter hospital stay, decreased blood loss, and required fewer transfusions and postoperative back pain. Following-up found the less invasive group to have ODI and VAS scores that were significantly decreased. As opposed to this, the open group exhibited a much reduced operational period. Although both groups experienced a comparable incidence of complications, the minimally invasive group documented two instances of screw malposition. Some of the study's limitations were the relatively short duration of follow-up in certain cases and the small sample size. As a result, additional research on a bigger sample size and on a broader geographical range is required to validate our results.

5. Conclusions

Treatment of degenerative lumbar spine problems with TLIF is a straightforward, risk-free, and efficacious approach that also enhances the quality of life for affected individuals.

Table 1: Distribution of studied sample according to patient’s demographic data, and comorbidities

		Number	Percent
Age (years)	≤50	12	60
	>50	8	40
	Range	41-60	
	Mean ± SD	49.90 ± 5.524	
Sex	Male	7	35
	Female	13	65
Weight (Kg)	Range	58 – 90	
	Mean ± SD	72.60 ± 8.642	
Height (cm)	Range	150 – 190	
	Mean ± SD	167.27 ± 9.474	
BMI (Kg/m ²)	Range	21.85 – 32.05	
	Mean ± SD	25.937 ± 2.183	
Comorbidity	HTN	3	15
	DM	4	20
	Dyslipidemia	1	5
	Cardiovascular	1	5

HTN: hypertension, DM: diabetes mellitus.

Table 2: Distribution of studied sample according to patient’s TLF level, spine disease and operation data

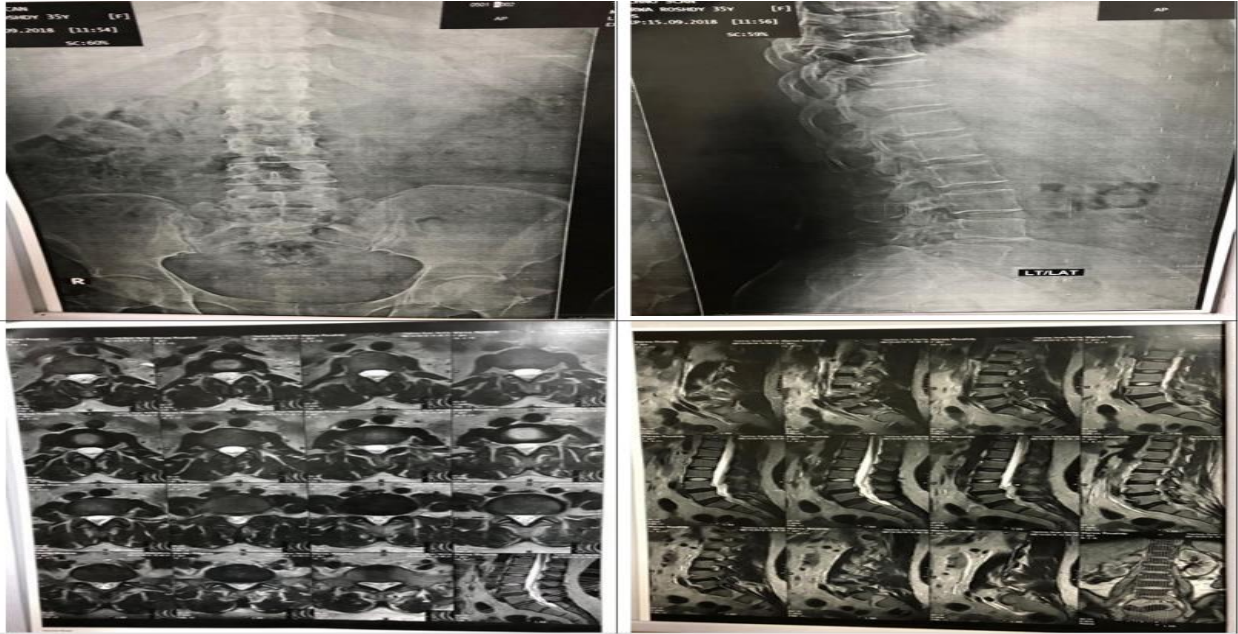
		Number	Percent
TLF Level	L4/L5	20	100
	L5/S1	5	25
	Multi levels	3	15
Spine Disease	Spondylolisthesis	6	30
	Degenerative Disc	6	30
	Degenerative scoliosis	3	15
	Failed Back surgery	3	15
	Lumber Canal Stenosis	4	20
	Disc regeneration	2	10
		Min. – Max.	
Surgical Time		1.5 – 3.5	2.60±0.620
Blood Loss		160 – 345	248.75±62.993
Hospital Stay		4 – 7	5.95±1.146

TLF: transformational lumbar interbody fusion

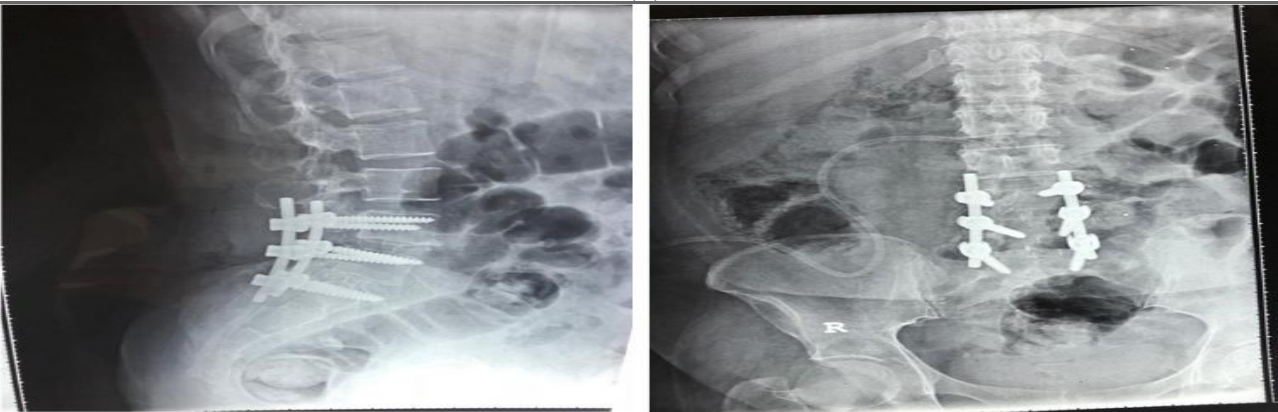
Table 3: Comparison between before and after treatment according to patient’s assessment tools

		Before	After 1 year	P Value
Oswestry disability index (ODI)	Min. – Max.	42 – 80	21 – 65	<0.001*
	Mean ± S.D.	61.65±11.38	35.35±11.417	
VAS score	Min. – Max.	4 – 9	0 – 3	<0.001*
	Mean ± S.D.	6.80±1.609	0.75±0.910	

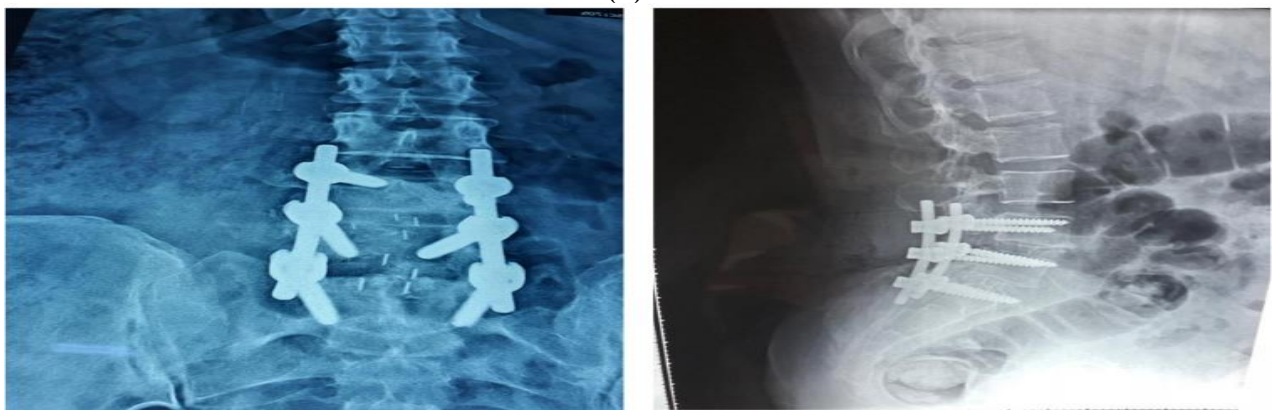
VAS: visual analogue scale, *: statistically significant as p value <0.05.



(A)



(B)



(C)

Figure 1: (A) preoperative, (B) postoperative and (C) follow up

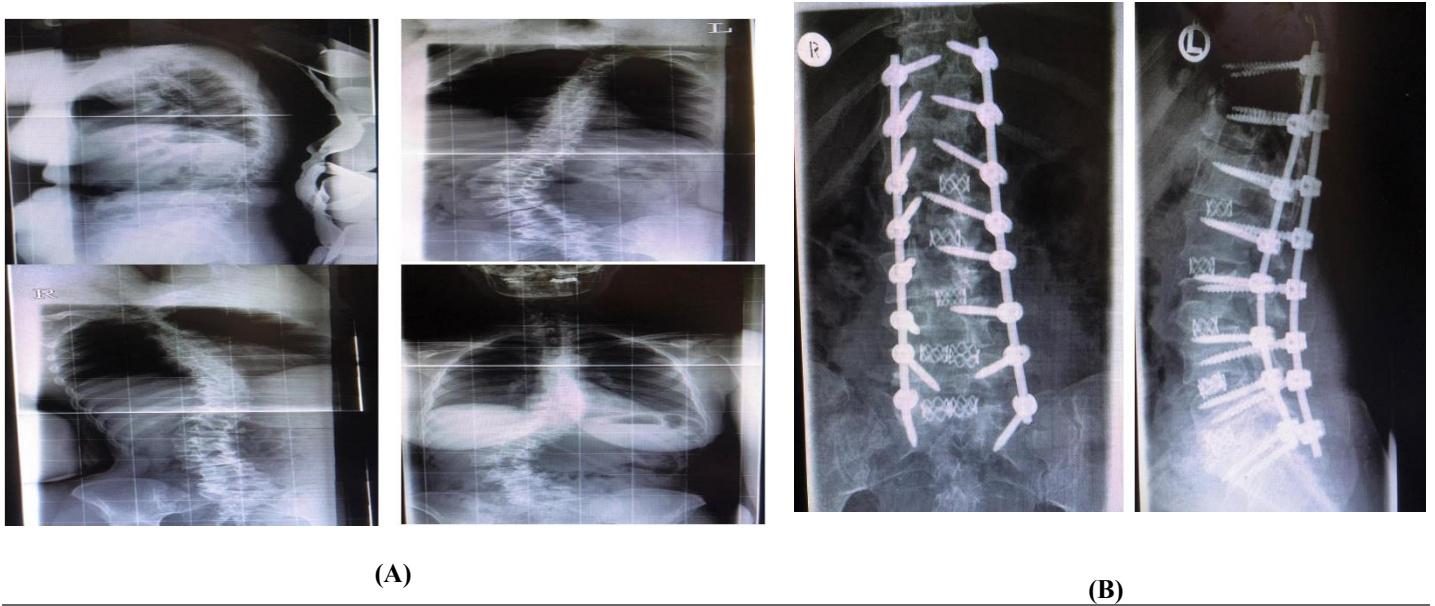


Figure 2:(A) preoperative, (B) follow up

Table 4: Distribution of studied sample according to patient’s radiology findings and complications

		Number	Percent
Radiology findings	Disc restored	18	90
	Solid fusion	11	55
	Delayed union	2	10
	Cage subsidence	1	5
	Pseudarthrosis	1	5
Complications	Infection	3	15
	Persistent back pain	2	10
	Pseudarthrosis	1	5
	Neurological deficit	1	5

Table 5: Distribution of studied sample according to patient’s satisfaction, pain improvement and return to work

		Number	Percent
Patient satisfaction	Good	17	85
	Poor	3	15
Pain improvement	Improved	18	90
	not improved	2	10
Return to work	No	1	5
	Yes	15	75
	Light duties	4	20

When posterior decompression and circumferential fusion in the lumbar region are required, in particular, we contend that this method ought to be advocated for and utilised appropriately in specific circumstances.

Financial support and sponsorship

Nil

Conflict of Interest

Nil

References

- [1] Y.-H. Kim, K.-Y. Ha, K.-W. Rhyu, H.-Y. Park, C.-H. Cho, H.-C. Kim, H.-J. Lee, S.-I. Kim. (2020). Lumbar interbody fusion: techniques, pearls and pitfalls. *Asian spine journal*. 14(5): 730.
- [2] M.C. Prabhu, K.C. Jacob, M.R. Patel, H. Pawlowski, N.N. Vanjani, K. Singh. (2022). History and evolution of the minimally invasive transforaminal lumbar interbody fusion. *Neurospine*. 19(3): 479.
- [3] R.J. Mobbs, K. Phan, G. Malham, K. Seex, P.J. Rao. (2015). Lumbar interbody fusion: techniques, indications and comparison of interbody fusion options including PLIF, TLIF, MI-TLIF, OLIF/ATP, LLIF and ALIF. *Journal of spine surgery*. 1(1): 2.
- [4] C.D. Cole, T.D. McCall, M.H. Schmidt, A.T. Dailey. (2009). Comparison of low back fusion techniques: transforaminal lumbar interbody fusion (TLIF) or posterior lumbar interbody fusion (PLIF) approaches. *Current reviews in musculoskeletal medicine*. 2: 118-126.
- [5] T. Aizawa, H. Ozawa, T. Kusakabe, T. Nakamura, A. Sekiguchi, A. Takahashi, E. Itoi, T. Sasaji, S. Tokunaga, T. Chiba. (2012). Reoperation for recurrent lumbar disc herniation: a study over a 20-year period in a Japanese population. *Journal of Orthopaedic Science*. 17(2): 107-113.
- [6] J.L. Gum, D. Reddy, S. Glassman. (2016). Transforaminal lumbar interbody fusion (TLIF). *JBJS essential surgical techniques*. 6:22-8.
- [7] W.-S. Choi, J.-S. Kim, J.-W. Hur, J.-H. Seong. (2018). Minimally invasive transforaminal lumbar interbody fusion using banana-shaped and straight cages: radiological and clinical results from a prospective randomized clinical trial. *Neurosurgery*. 82(3): 289-298.
- [8] G.B. Brodano, K. Martikos, F. Lolli, A. Gasbarrini, A. Cioni, S. Bandiera, M. Di Silvestre, S. Boriani, T. Greggi. (2015). Transforaminal lumbar interbody fusion in degenerative disk disease and spondylolisthesis grade I: minimally invasive versus open surgery. *Clinical Spine Surgery*. 28(10): E559-E564.
- [9] M. Mohammad Hassaan, I. Ali Nassar, A.A.-A. Alsebaie, A. Ibrahim Khamiss, A. Ibrahim Akar. (2016). Transforaminal lumbar interbody fusion in management of degenerative lumbar spine disorders. *Al-Azhar Medical Journal*. 45(1): 161-170.
- [10] S.C. Humphreys, S.D. Hodges, A.G. Patwardhan, J.C. Eck, R.B. Murphy, L.A. Covington. (2001). Comparison of posterior and transforaminal approaches to lumbar interbody fusion. *Spine*. 26(5): 567-571.
- [11] D.-I. Yan, F.-x. Pei, J. Li, C.-I. Soo. (2008). Comparative study of PILF and TLIF treatment in adult degenerative spondylolisthesis. *European Spine Journal*. 17: 1311-1316.
- [12] Z. Audat, O. Moutasem, K. Yousef, B. Mohammad. (2012). Comparison of clinical and radiological results of posterolateral fusion, posterior lumbar interbody fusion and transforaminal lumbar interbody fusion techniques in the treatment of degenerative lumbar spine. *Singapore medical journal*. 53(3): 183-187.
- [13] T.G. Lowe, A.D. Tahernia, M.F. O'Brien, D.A. Smith. (2002). Unilateral transforaminal posterior lumbar interbody fusion (TLIF): indications, technique, and 2-year results. *Clinical Spine Surgery*. 15(1): 31-38.
- [14] K. Asil, C. Yaldiz. (2016). Retrospective comparison of radiological and clinical outcomes of PLIF and TLIF techniques in patients who underwent lumbar spinal posterior stabilization. *Medicine*. 95(17): e3235.
- [15] H. Xue, Y. Tu, M. Cai. (2012). Comparison of unilateral versus bilateral instrumented transforaminal lumbar interbody fusion in degenerative lumbar diseases. *The Spine Journal*. 12(3): 209-215.
- [16] F. Shunwu, Z. Xing, Z. Fengdong, F. Xiangqian. (2010). Minimally invasive transforaminal lumbar interbody fusion for the treatment of degenerative lumbar diseases. *Spine*. 35(17): 1615-1620.