

Biological and Tissue-Preservation Mechanisms of the Socket Shield Technique and Subepithelial Connective Tissue Grafting in Immediate Implant Placement: A Mini-Review

Osama Ahmed El Naggar¹, Mohamed Wagdy Bissar², Mahetab M. Abdalwahab³

¹Master candidate at the Department of Oral Medicine, Periodontology and Oral Diagnosis, Faculty of Dentistry, Ain Shams University, Cairo, Egypt

²Associate Professor of Oral Medicine, Periodontology, and Oral Diagnosis, Faculty of Dentistry, Ain Shams University, Cairo, Egypt

³Associate Professor of Oral Medicine, Periodontology, and Oral Diagnosis Faculty of Dentistry, Ain Shams University, Cairo, Egypt

Abstract

Restoration of esthetics in the anterior maxilla following tooth extraction and immediate implant placement remains biologically challenging due to the inevitable remodeling of hard and soft tissues. These dimensional changes are largely governed by biological and biochemical processes initiated after extraction, particularly the loss of the periodontal ligament (PDL), which serves as a critical source of vascular supply, cellular signaling, and metabolic support to the labial bundle bone. Disruption of this vascularized interface accelerates bone resorption and compromises peri-implant tissue stability. This mini-review highlights the biological rationale and tissue-preservation mechanisms of two complementary techniques: the Socket Shield Technique (SST) and the Subepithelial Connective Tissue Graft (SCTG). SST, as a partial extraction therapy, preserves the buccal root fragment and maintains the PDL–bundle bone complex, thereby sustaining local blood supply, cellular viability, and bone metabolism at the implant site. This biological preservation limits facial bone resorption and supports structural stability. In contrast, SCTG functions as a soft tissue augmentation strategy that enhances mucosal thickness and tissue quality. Increasing peri-implant mucosal thickness beyond 2 mm has been associated with improved vascularization, reduced inflammatory response, and decreased marginal bone loss. The grafted connective tissue contributes to a more resilient biological seal, promoting long-term tissue homeostasis around implants. The combined application of SST and SCTG addresses both hard and soft tissue remodeling at a biological level, offering a predictable approach for maintaining peri-implant tissue architecture and optimizing long-term esthetic and functional outcomes in immediate implant therapy.

Keywords: Socket Shield Technique, Partial Extraction Therapy, Subepithelial Connective Tissue Graft, Immediate Implant Placement, Alveolar Bone Resorption, Esthetic Zone.

Full length article *Corresponding Author, e-mail: osamaaa.eg@gmail.com, Doi # <https://doi.org/10.62877/6-IJCBS-25-28-22-6>,
Submitted: 03-12-2025; Accepted: 30-12-2025; Published: 31-12-2025

1. Introduction: The Esthetic and Biological Imperative

The contemporary standard for successful implant therapy in the anterior maxilla demands more than osseointegration; it requires the meticulous reproduction of natural, harmonious soft and hard tissue contours that serve as the framework for the final prosthesis [1]. Immediate Implant Placement with Provisionalization (IIPP) is widely utilized to expedite restoration and optimize surrounding tissues [2]. However, immediate implant placement is

intrinsically compromised by the biological reality that alveolar bone is a tooth dependent structure that undergoes progressive resorption after extraction [3]. This atrophy is most pronounced in crestal and buccal regions because most of thin labial plate's blood supply originates from periodontal ligaments (PDL), which is lost during extraction [2]. The rapid loss of this vascularized bundle bone leads to substantial dimensional changes and complicates the achievement of predictable esthetic outcomes, especially when the labial

plate is often thinner than 1-2 mm thickness which is crucial for stable peri-implant tissues [4]. To overcome these anatomical and physiological constraints, preservation strategies that prioritize maintaining both hard tissue volume and soft tissue stability are essential.

2. Roles and Mechanisms of Preservation Techniques

The literature establishes the critical roles of SST and SCTG as complementary tools for managing the post-extraction environment in the aesthetic zone Table 1.

2.1. The role and mechanism of socket shield (SST): Biological Hard Tissue Preservation

The socket shield technique (STT), which was introduced in 2010, is a partial extraction therapy that focuses on biologically conserving the native tissue rather than managing the resorbing socket [5], (Figure 1).

- **Mechanism of bundle bone preservation:** The primary role of socket shield technique is to interrupt the biological signaling cascade that triggers bone atrophy. This achieved by retaining the labial one third portion of tooth root fragment, known as the socket shield within the socket [6].
- **Structural Integrity:** By preventing the collapse of buccal bone plate, the SST effectively mitigates the inevitable horizontal and vertical resorption that compromises ridge volume and consequently the overlying soft tissue contours [7].
- **Vascular Maintenance:** The retaining shield maintains the vitality of the underlying bone structure safeguarding the PDL and its fibrous apparatus, ensuring continued blood supply and structural support to the bundle bone and labial plate [8].

Technical implementation details are crucial: the shield typically requires a facial portion thickness of 1-2 mm for stability and is often reduced coronally to approximately 0.5 mm above the buccal alveolar crest to avoid exposure and facilitate soft tissue contouring [8]. The implant is typically placed lingual to the shield, creating a jumping distance [9],

and stability is often reinforced through a mechanical locking approach in direct apical contact with root fragment.

2.2. The role and mechanism of subepithelial connective tissue graft (SCTG): volumetric soft tissue augmentation

Complementary to hard tissue stability, the SCTG is utilized to create a robust and resilient soft tissue margin, which is crucial for long term stability [10], (Figure 2).

- **Volumetric augmentation:** The primary mechanism involves transplanting dense connective tissue, typically harvested from the palate, into the recipient site, significantly increasing the peri-implant mucosal thickness and volume.
- **Esthetic stabilization and seal:** The augmented soft tissue stabilizes the gingival margin, prevents midfacial gingival collapse and supports the emergence profile of the provisional restoration [11]. The increased soft tissue density provides a more resilient biological seal, minimizing the risk of bacterial infiltration and recession, which are common esthetic failure in the anterior maxilla [12].
- **Marginal bone loss reduction:** Evidence indicates that the thickness of keratinized mucosa plays a key role in maintaining long-term peri-implant stability. Implant with at least 2 mm of keratinized tissue demonstrate significantly lower marginal bone loss than those with narrower or thinner keratinized mucosa [13]. The SCTG contributes to achieving or preserving this beneficial soft tissue thickness.
- **Optimized surgical approach:** SCTG placement often utilizes a partial-thickness flap or tunneling technique to create a subperiosteal pouch without vertical incisions. This method is preferred because it maintains the periosteal blood supply to the buccal plate, optimizing graft survival and minimizing the risk of bone resorption associated with extensive flap elevation.

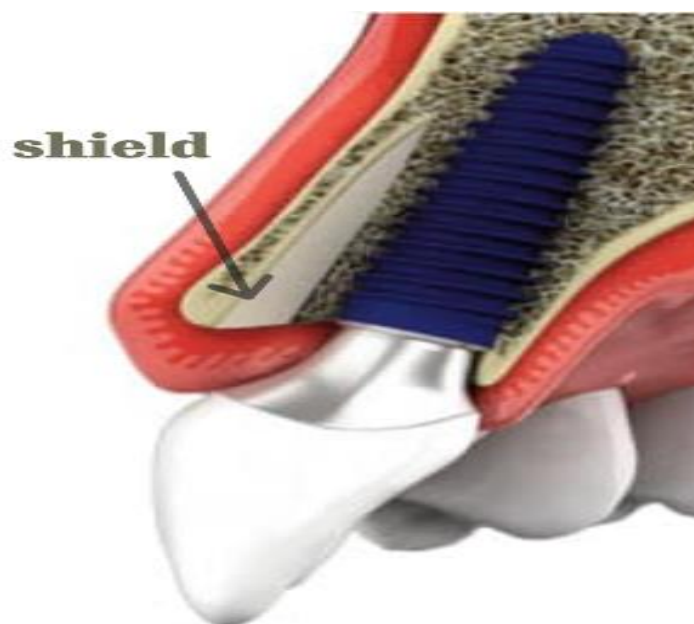


Figure 1: Diagram of socket shield technique.

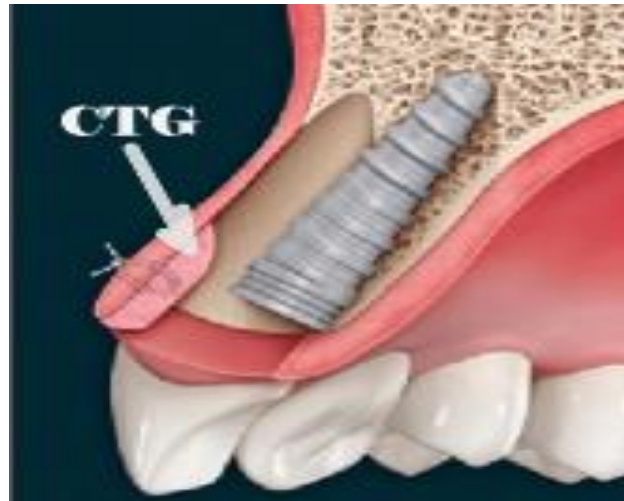

Figure 2: Diagram of connective tissue grafts buccally to dental implant.

Table 1: Roles and mechanisms of (SST) and (SCTG)

Aspect	Socket Shield Technique (SST)	Subepithelial Connective Tissue Graft (SCTG)
Primary Purpose	Hard-tissue preservation through maintaining the buccal root fragment.	Soft-tissue augmentation to increase mucosal thickness and volume.
Biological Mechanism	Maintains the periodontal ligament (PDL), preserving vascular supply and preventing bundle bone resorption.	Provides dense connective tissue that increases the thickness of peri-implant mucosa and supports tissue stability.
Effect on Buccal Plate	Prevents collapse of the thin labial plate and minimizes horizontal/vertical bone resorption.	Protects the buccal plate indirectly by providing a thicker and more resilient soft tissue barrier.
Effect on Buccal Plate	Prevents collapse of the thin labial plate and minimizes horizontal/vertical bone resorption.	Protects the buccal plate indirectly by providing a thicker and more resilient soft tissue barrier.
Esthetic Benefits	Preserves natural ridge contour and supports long-term facial esthetics.	Improves esthetic volume and soft-tissue symmetry, enhancing implant esthetics in the anterior zone.
Impact on Marginal Bone Loss	Reduces bone loss by preserving bundle bone and labial plate structure.	Studies show reduced marginal bone loss when ≥ 2 mm keratinized mucosa is achieved.
Tissue Stability Over Time	Promotes long-term stability by preventing post-extraction remodeling.	Creates a thicker, more resilient mucosa that resists shrinkage and recession.
Overall Clinical Benefit	Provides a biological anchor that preserves hard tissues critical for esthetic outcomes in immediate implants.	Establishes a robust mucosal barrier essential for soft-tissue health and long-term esthetic stability.

3. Conclusions

Immediate implant placement presents two key challenges: physiological bone loss and subsequent soft tissue contraction, both of which often require a combined surgical approach. The Socket Shield Technique serves as the indispensable biological anchor by maintaining the vital PDL bundle bone complex, thereby preventing buccal wall collapse. Concurrently, the Subepithelial Connective Tissue Graft provides the essential volumetric augmentation needed to establish a thick and resilient mucosal barrier that shields the underlying bone, supports the gingival margin, and ensures long term esthetic stability. The synergistic use of SST and SCTG represents an advanced and evidence-based protocol for achieving optimal structural and esthetic outcomes in the aesthetically demanding anterior.

References

- [1] J.Y.K. Kan, K. Rungcharassaeng, M. Deflorian, T. Weinstein, H.L. Wang, T. Testori. (2018). Immediate implant placement and provisionalization of maxillary anterior single implants. *Periodontology 2000*. 77(1): 197-212.
- [2] G.B. Menchini-Fabris, P. Toti, U. Covani, S. Trasarti, S. Cosola, R. Crespi. (2023). Volume assessment of the external contour around immediate implant with or without immediate tooth-like crown provisionalization: A digital intraoral scans study. *Journal of Stomatology, Oral and Maxillofacial Surgery*. 124(4): 101418.
- [3] M.G. Araújo, J. Lindhe. (2005). Dimensional ridge alterations following tooth extraction. An experimental study in the dog. *Journal of clinical periodontology*. 32(2): 212-218.
- [4] X. Yang, T. Zhou, N. Zhou, Y. Man. (2019). The thickness of labial bone affects the esthetics of immediate implant placement and provisionalization in the esthetic zone: A prospective cohort study. *Clinical implant dentistry and related research*. 21(3): 482-491.
- [5] M.B. Hürzeler, O. Zuhr, P. Schupbach, S.F. Rebele, N. Emmanouilidis, S. Fickl. (2010). The socket-shield technique: a proof-of-principle report. *Journal of clinical periodontology*. 37(9): 855-862.
- [6] H. Gluckman, M. Salama, J. Du Toit. (2018). A retrospective evaluation of 128 socket-shield cases in the esthetic zone and posterior sites: partial extraction therapy with up to 4 years follow-up. *Clinical implant dentistry and related research*. 20(2): 122-129.
- [7] O. Zuhr, P. Staehler, M. Huerzeler. (2020). Complication Management of a Socket Shield Case After 6 Years of Function. *International Journal of Periodontics & Restorative Dentistry*. 40(3).
- [8] P. Staehler, S.M. Abraha, J. Bastos, O. Zuhr, M. Hürzeler. (2020). The socket-shield technique: a step-by-step protocol after 12 years of experience. *Int J Esthet Dent*. 15(3): 288-305.
- [9] B. Howard Gluckman. A decade of the socket-shield technique: a step-by-step partial extraction therapy protocol. Department of Periodontics, Columbia College, 2020.
- [10] Z. Tastan Eroglu, D. Ozkan Sen, E. Oncu. (2024). Association of peri-implant keratinized mucosa width and mucosal thickness with early bone loss: a cross-sectional study. *Journal of Clinical Medicine*. 13(7): 1936.
- [11] D.S. Thoma, B. Buranawat, C.H. Hämmerle, U. Held, R.E. Jung. (2014). Efficacy of soft tissue augmentation around dental implants and in partially edentulous areas: a systematic review. *Journal of clinical periodontology*. 41: S77-S91.
- [12] O. Zuhr, S. Fickl, H. Wachtel, W. Bolz, M. Hürzeler. (2007). Covering of gingival recessions with a modified microsurgical tunnel technique: case report. *International Journal of Periodontics and Restorative Dentistry*. 27(5): 457.
- [13] D. Chele, G. Motelica, N. Chele, I. Dabija, D. Socolan, F.C. Badea. (2024). Gingival phenotype role in early peri-implant bone remodeling. *Journal of Stomatological Medicine*. 168-173.