

***In Vitro* Antioxidant and *In Vivo* Hepatoprotective Activity of *Lantana camara* in Paracetamol-Induced Liver Injury in Experimental Rats**

Mahendar Boddupally^{*1}, S. Shobha Rani²

¹Research scholar, Centre for Pharmaceutical science, Jawaharlal Nehru Technological University, kukatpally
Hyderabad-500 085, Telangana, India.

²Professor, Department of Pharmaceutical Analysis, Centre for Pharmaceutical science, Jawaharlal Nehru Technological
University, kukatpally, Hyderabad-500 085, Telangana, India.

Abstract

Liver disease is a major public health threat, particularly in developing countries. Several medicinal plants and formulations have been claimed to have liver protective activities. The present study aimed to evaluate in vitro antioxidant and in vivo hepatoprotective activities of methanolic extract of *Lantana camara*. In vitro anti-oxidant activity of crude extract plant was conducted using the DPPH assay, ABTS radical scavenging Activity and Metal chelating assay. Hepatoprotective activities of the crude extract and solvent fractions of the plant were carried out based on paracetamol-induced liver damage in Rat. Serum biomarkers (SGOT, SGPT & ALP, BIT, BID & ALB) were assessed to find out the effect. Histopathological examination was also carried out for all groups of Rat to further confirm the findings. Antioxidant assay revealed that the MELC exhibited free radical scavenging activity. Pretreatment of the rats with the MELC significantly. The hepatoprotective activities of the plant extracts were confirmed by serum biomarkers and histopathological studies. From this study, it can be concluded that the crude extract and solvent fractions of *lantana camara* demonstrated antioxidant and hepatoprotective activities.

Keywords: antioxidant, hepatoprotective, *Lantana camara*, paracetamol, biochemical parameters, liver damage

Full-length article

*Corresponding Author, e-mail: mahipharmacist@gmail.com

1. Introduction

Liver diseases are among the global health problems; In which, liver cirrhosis is the ninth leading cause of death in western Nations. [1] Toxic chemicals, xenobiotics, alcohol consumption, malnutrition, anemia, medications, autoimmune disorders, and viral infections [2,3] are some major causes of liver disease; among which, medications are the most common contributing factors. [4] Drug-induced liver damage accounts for more than 60% of all cases in the United States of America, and it is the leading cause of acute liver failure [5]. Paracetamol is a commonly available over-the-counter analgesic and antipyretic drug which is associated with acute liver damage. The hepatotoxicity associated with paracetamol is mainly due to excessive accumulation of its toxic metabolite, N-acetyl-p-benzoquinone imine (NAPQI), which oxidizes liver tissue macromolecules such as lipid or -SH group of protein causing oxidative stress and hepatic necrosis. [6, 7, 8]

The modern drugs available for the treatment of liver ailments are less effective, less safe and, expensive. [9] This indicates the need for new better drugs. Several medicinal plants and formulations have been claimed to have liver protective activities, about 160 phytoconstituents from 101 plants have been suggested to possess hepatoprotective activity. [10] Among them, the methanol extract of *Senna singueana* demonstrated hepatoprotective activity against D-galactosamine-induced liver damage in rats by its antioxidant and anti-apoptotic effects. [11] Additionally, tannin-containing extracts from *Lanneastuhlmannii* and *Lannea humilis* exhibit hepatoprotective activities against D-galactosamine-induced hepatic injury in rats. The hepatoprotective activity of the extracts was due to the antioxidant and anti-apoptotic effects of tannins and proanthocyanidins. [12] As a result, highest priority has been given globally to investigate plant-based hepatoprotective drugs effective against different liver diseases.

Lantana camara is a species of flowering plant within the verbena family (Verbenaceae), native to the American tropics. Other common names of *L. camara* include Big-sage, wild-sage, red-sage, white-sage, tick berry, West Indian lantana, and umbelanterna. *L. camara* was probably introduced before 19th century. Currently *L. camara* is distributed throughout India where there is a moderate to high summer rainfall and well-drained sloping sites. *L. camara* is a well-known medicinal plant in traditional medicinal system and recent scientific studies have emphasized the possible use of *L. camara* in modern medicine. Phytochemical investigation of this plant was indicated by the presence of essential oil i.e., Sabiene (19.6-21.5%), 1, 8- Cineole (12.6- 14.8%), β - caryophyllene (12.7-13.4%), α -humulene (5.8-6.3%), two rare sesqui terpenoids humulene epoxide-III and 8-hydroxy bicyclogermacrene 11, 1, 8-cineol (15.8%), sabinene (14.7%) and caryophyllene (8.9%). Phytochemical screening revealed that leaf, stem and root of *Lantana camara* contained tannin, catechin, saponin, steroids, alkaloids, phenol, anthroquinone, protein, several tri-terpenoids, flavonoids, alkaloids, glycosides and reducing sugar. which are mainly responsible for exerting diverse biological activities. The leaves of lantana camara are known to possess highest antioxidants chemical constituents like flavonoids, vitamin c.

2. Materials and Methods

2.1. Plant Material Collection

Lantana camara leaves were obtained from the local places of tirupati, ap. *Lantana camara* leaves plants was authenticated by Dr. K. Madhava Chetty, M.Sc., M.Ed., M.Phil., Ph.D., PG DPD, Assistant professor, Department of Botany, srivenkateshwara university, Thirupathi, A. P.

2.2. Extraction by maceration

Fresh leaves of *lantana camara* leaves washed with water to get rid of contaminants like dirt and other impurities and were shade-dried. These dried leaves and fruits were ground and sieved to get a uniform coarse powder. Powdered plant material was weighed (1kg) and is immersed in methanol and kept for maceration for a period of 7 days with occasional stirring. On the 8th day, the solvent was filtered by pressing with a muslin cloth and was evaporated in a rotary evaporator at 40°C. The resultant extract was put in a desiccator to remove any ethanol left in it. The dried methanolic extract of *lantana camara* (MELC) was packed in an air-tight bottle and put in a dry place for further studies.

2.3. Phytochemical screening

Phytochemical screening of the leaves of *lantana camara* was carried out using standard protocols. Plants were screened for carbohydrates, proteins, amino acids, alkaloids, phenolic compounds, tannins, flavonoids, steroids, saponins and glycosides [13,14].

2.4. Experimental animals

Male Wistar albino rats weighing 200 to 250 g body weight each were maintained at standard laboratory conditions such as temperature at (25-27°C), humidity (45-55%) and 12 h light-dark cycle with proper access to the standard rat pellet diet and water, *ad libitum*. Post Boddupally et al., 2023

acclimatization, the animals were divided into 5 groups, each group with 6 rats.

2.5. Determination of Antioxidant Activity (DPPH) Assay

The free radical scavenging activity of the crude extract and solvent fractions of root bark extracts of *Lantana Camara* was determined *in vitro* by 2, 2-diphenyl-1-picrylhydrazyl (DPPH) assay according to the standard method described by Braca et al, (2001). [15] Initially, 3 mL of 0.004% DPPH in methanol was mixed with 1 mL of various concentrations (200, 100, 50, 25, 12.5 μ g/mL) of the crude extract and solvent fractions of *Lantana Camara* separately. Mixtures were incubated for 30 minutes incubation at room temperature in a dark place. The absorbances of the mixtures in the samples were measured using a spectrophotometer at 517 nm against methanol as blank. The percentage of radical scavenging activities of the samples were evaluated compared with a control (3 mL DPPH solution and 1 mL methanol). Each sample was measured in triplicate and the average was calculated. The percentage of radical scavenging activity (RSA) was calculated using the following formula:

$$\% \text{ RSA} = [(A_0 - A_1)/A_0] \times 100$$

where A_0 is the absorbance of the control, and A_1 is the absorbance of samples after 30 minutes. The free radical scavenging activity of the plant extracts was expressed as IC₅₀. The IC₅₀ value is defined as the concentration (in μ g/mL) of a sample that inhibits 50% of the DPPH radical.

2.6. ABTS radical scavenging Activity

ABTS 2 mM (0.0548 gm in 50ml) and potassium per sulphate 70 mM (0.0189 gm in 1ml) were prepared in distilled water. Next, 200 ml of potassium per sulphate and 50 ml of ABTS were mixed and kept aside for 2 hrs. This solution was used for assessing ABTS radical scavenging activity. To the 1 ml of various concentrations of plant extract or standard, 0.6 ml of ABTS radical cation and 3.4 ml of phosphate buffer pH 7.4 were added and the absorbance was measured at 734 nm. The experiment was performed in triplicate. Ascorbic acid was used as standard. The percentage of inhibition (I %) was calculated using following formula and lower IC₅₀ value indicates high antioxidant capacity [16].

$$I \% = \frac{(\text{Abs}_{\text{control}} - \text{Abs}_{\text{sample}})}{\text{Abs}_{\text{control}}} \times 100$$

2.7. Metal chelating assay

In this assay, 10 ml of plant extract or standard, 0.2 ml of 2 mM ferric chloride and 0.4 ml of ferrozine solution were mixed and kept aside for 10 min at room temperature with continuous shaking. The absorbance was measured at 562 nm. The experiment was performed in triplicate. EDTA was used as standard. The percentage inhibition was calculated using following formula and lower IC₅₀ value indicates high antioxidant capacity.

$$I \% = \frac{(\text{Abs}_{\text{control}} - \text{Abs}_{\text{sample}})}{\text{Abs}_{\text{control}}} \times 100$$

$$\frac{\text{Abs (sample)}}{\text{Abs control}} \times 100$$

2.8. Assessment of Hepatoprotective Activity

2.8.1. Evaluation of hepatoprotective activity in paracetamol-induced hepatotoxicity

In case of paracetamol-induced hepatotoxicity, the rats were divided into 5 groups of 6 rats each: Group I: Vehicle treated rats were kept on normal diet and served as control for 15 days. Group II: Rats received paracetamol (500 mg/kg b. w/day, orally) for 15 days. Group III: Rats received Silymarin (25 mg/kg b. w/day, orally) and paracetamol as group II, for 15 days. Group IV: Rats received MELC (200 mg/kg b. w/day, orally) and paracetamol as group II, for 15 days. Group V: Rats received MELC (400 mg/kg b. w/day, orally) and paracetamol as group II, for 15 days. This period of treatment, the rats were maintained under normal diet and water. The blood was collected from the retro orbital plexus of the rats of all groups 24 h after the last dose administration, under light anesthetic ether. The blood samples are centrifuged at 3000rpm for 30min to separate the serum. The serum was analyzed for various biochemical parameters such as SGOT, SGPT, ALP, BIT, BID and ALB. Liver was dissected out and subjected for morphological study such as liver weight and liver volume of each animal. Further the liver was placed in 10% formalin solution for histopathological study [17,18].

2.8.2. Estimation of serum bio-chemical parameters [19-21]

Different biochemical parameters were estimated like SGOT, SGPT, ALP, bilirubin and albumin.

2.8.3. Histopathological Examination

After the collection of the blood, the Rat were sacrificed and the liver was dissected out, and weighed. Then, it was preserved in a 10% formalin solution. A portion of liver tissue from the right lobe of the liver was taken and dehydrated in different grades of ethanol (40%, 70%, 80%, 95%, and 100%) and cleared with xylene. Xylene was also cleared using paraffin wax using an automatic tissue processing machine. The tissues were embedded with paraffin wax and blocked in the coronal plane. Sections of 4–5 micrometer thickness of the tissue was made using a microtome and stained with hematoxylin and eosin dye, and a histological observation was made under a light microscope.

2.8.4. Statistical Analysis

Results were expressed as means \pm Standard Errors of Mean (SEM). The analysis was carried out using Graph pad instat 3 software. One-way analysis of variance (ANOVA) was applied to test for significance of biochemical data of the different groups. Significance was set at $P \leq 0.05$.

3. Results and Discussion

3.1. In vitro antioxidant assays

3.1.1. DPPH radical scavenging assay

It is an extensively used, relatively rapid and accurate method for the assessment of free radical scavenging activity. DPPH is a stable free radical and accepts an electron or hydrogen radical to become a stable diamagnetic molecule. Antioxidant donates the electron or hydrogen atom after interaction with DPPH radical and thus neutralizing free radical character of the DPPH and convert it to 1-1, diphenyl-2-picryl hydrazine and the degree of discoloration indicates the scavenging activity of the drug. The reduction capacity of DPPH radical is determined by the decrease in its absorbance at 517 nm induced by antioxidants. The decrease in absorbance of DPPH radical caused by antioxidants because of the reaction between antioxidant and radical progress which results in the scavenging of the radical by hydrogen donation. It is visually evident as change in color from purple to yellow. Hence DPPH is usually used as a substance to evaluate the antioxidant activity. The IC₅₀ values of the Methanolic extraction of *Lantana camara* (MELC) was found to be 204.3 $\mu\text{g/ml}$. IC₅₀ value for the Vitamin C (Standard) was found to be 8.5 $\mu\text{g/ml}$ and also presented in **Table 1**.

3.1.2. ABTS radical scavenging assay

It is one of the most commonly used assays in food industry for the measurement of antioxidant ability of foods. In this, ABTS is converted to its radical cation by addition of potassium per sulfate. This radical cation is blue in color and absorbs light at 734 nm. The ABTS radical cation is reactive towards most antioxidants including polyphenols, thiols and ascorbic acid. During this reaction, the blue ABTS radical cation is converted rear to its colorless neutral form. The IC₅₀ values of the Methanolic extraction of *Lantana camara* (MELC) were found to be 327.1123 $\mu\text{g/ml}$ respectively. IC₅₀ value for the Vitamin C (Standard) was found to be 10.57 $\mu\text{g/ml}$ and also presented in Table 2.

3.1.3. Metal chelating assay

Ferrous iron can initiate lipid peroxidation by the Fenton reaction as well as accelerating peroxidation by decomposing lipid hydro peroxides into peroxy and alkoxy radicals. Ferrozine can make complexes with ferrous ions. From the result it was evident that BOB and ASP extracts possessed Fe²⁺ chelating activity and might play a protective role against oxidative damage induced by metal catalyzed decomposition reactions. The IC₅₀ values of the Methanolic extraction of *Lantana camara* (MELC) were found to be 306.69 $\mu\text{g/ml}$ respectively. IC₅₀ value for the EDTA (Standard) was found to be 76.15755 $\mu\text{g/ml}$ and also presented in Table 3.

3.2. Biochemical parameters

3.2.1. Effect of MELC fruits on SGOT, SGPT & ALP levels in paracetamol-induced hepatotoxic rats

Rats treated with paracetamol developed a significant hepatic damage observed as elevated serum levels of hepatospecific enzymes like SGPT, SGOT and ALP when compared to normal control. Treatment with Silymarin had showed good protection against Alcohol induced toxicity to liver. Groups treated with MELC showed significant effect which can be comparable with toxic control.

Table 1: DPPH radical scavenging assay of MELC

Extract/Standard	Concentration(µg/ml)	% Inhibition	IC ₅₀ Value
Methanolic extraction of <i>Lantana camara</i> (MELC)	100	32.43±1.32	204.3 µg/ml
	200	51.24±2.43	
	300	68.65±3.42	
	400	73.76±2.42	
	500	85.43±2.65	
Ascorbic acid	1	15.23±1.32	8.5 µg/ml
	2	21.56±1.54	
	4	28.88±2.43	
	6	37.65±2.65	
	8	45.32±2.76	
	10	58.79±2.76	

Table 2: ABTS radical scavenging assay of MELC

Extract/Standard	Concentration (µg/ml)	% Inhibition	IC ₅₀ value
Methanolic extraction of <i>Lantana camara</i> (MELC)	100	20.32±1.32	327.1123 µg/ml
	200	32.54±2.43	
	300	45.65±2.65	
	400	57.75±2.76	
	500	75.43±2.54	
Ascorbic Acid	10	32.43±1.43	10.57 µg/ml
	20	51.24±1.32	
	30	68.65±1.76	
	40	73.76±2.76	
	50	85.43±2.53	

Table 3: Metal chelation assay of MELC

Extract/Standard	Concentration (µg/ml)	% Inhibition	IC ₅₀ value
Methanolic extraction of <i>Lantana camara</i> (MELC)	100	23.17	306.69 µg/ml
	200	39.14	
	300	48.73	
	400	61.7	
	500	74.28	
EDTA	10	18.92	76.1575µg/ml
	20	25.43	
	40	33.41	
	60	41.64	
	80	52.31	
	100	60.23	

Table 4: Liver weight and liver volume in paracetamol induced hepatotoxic rats

Group	Liver weight gm/100gm	Liver volume ml/100gm
Control	3.42±0.65	5.75±0.15
Toxic control	4.76±0.86	9.64±0.18
Silymarin	3.63±0.42**	6.53±0.10**
MELC (200mg)	3.98±0.12**	7.98±0.06**
MELC (400mg)	3.68±0.51**	6.59±0.08**

Values are expressed as mean ± SEM; n=6

* p<0.05, **p<0.01 and***P<0.001. Comparison with toxic control

Table 5: SGOT, SGPT & ALP levels in paracetamol induced hepatotoxic rats

Group	SGOT (IU/L)	SGPT (IU/L)	ALP (IU/L)
Control	116.54±1.43	98.65±4.75	97.54±3.23
Toxic control	391.24±3.65	289.87±5.25	367.43±2.65
Silymarin	134.65±2.67**	109.21±2.25**	134.54±2.43**
MELC (200mg)	187.26±2.76**	178.56±1.65**	212.31±3.53**
MELC (400mg)	142.42±2.76**	121.75±2.54**	141.54±3.63**

Values are expressed as mean ± SEM; n=6

* p≤0.05, **p≤0.01 and***P<0.001. Comparison with toxic control

Table 6: BIT, BID & ALB levels in paracetamol induced hepatotoxic rats

Group	BIT (mg/dl)	BID (mg/dl)	ALB(g/dl)
Control	0.76±0.02	0.31±0.03	4.54±0.43
Toxic control	2.78±0.32	2.19±0.24	2.26±0.65
Silymarin	0.81±0.02**	0.41±0.03**	4.43±0.65**
MELC (200mg)	1.34±0.01**	1.12±0.02**	3.76±0.54**
MELC (400mg)	1.06±0.05**	0.96±0.02**	3.98±0.87**

Values are expressed as mean ± SEM; n=6

* p≤0.05, **p≤0.01 and***P<0.001. Comparison with toxic control

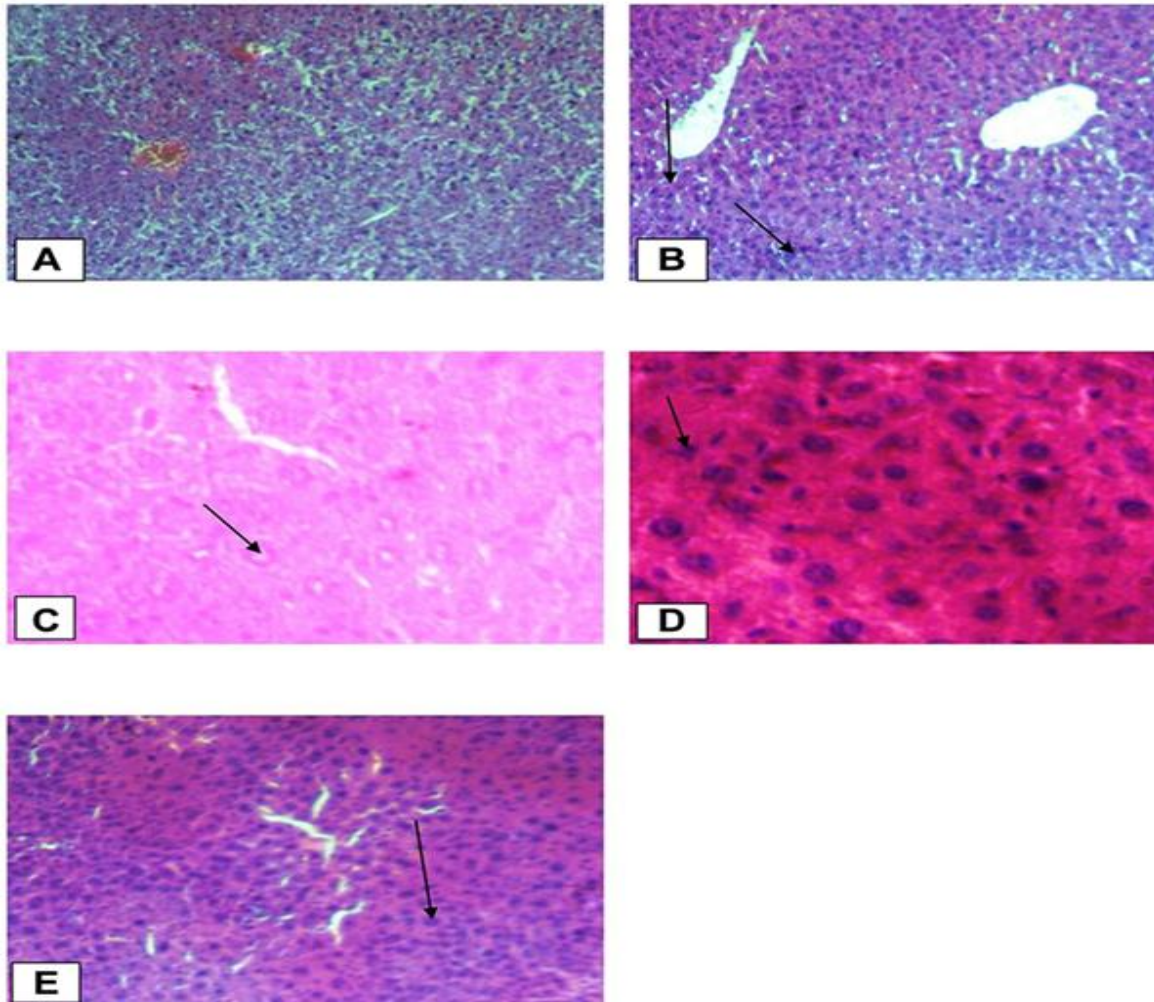


Figure 1: Histopathological changes of liver tissues (10x and 40x). (A) Normal control group (Normal hepatic cells with normal liver architecture) (B) paracetamol group (Necrotic hepatocytes, severe degeneration, hyperaemic/condensed blood vessels and cells with inflammation); Black arrow shows damaged hepatocytes. (C) Standard group (Liver architecture normal, cells with mild inflammation); Black arrow shows normal hepatocytes (D) Crude extract 200 mg/kg (Aggravated necrotic cells); Black arrow shows necrotized cells. (E) Crude extract 400 mg/kg (More necrotic hepatocytes and regenerated cells); Black arrow shows regenerated cells.

Dunnet's test indicates a significant reduction in elevated serum enzyme levels with extract treated animals compared to toxic control animals. Results were showed in Table 5. The total bilirubin concentration was found to increase in animals with liver damage by paracetamol. In standard group, Silymarin administration reduced total bilirubin and animals treated with MELC have exhibited dose dependent significant reduction in total bilirubin compared to toxic control group. Paracetamol treated groups But the treatment with Silymarin has shown significant increase while MELC have shown dose dependent increase in serum albumin level compared to toxic control group. Results were showed in Table 6.

3.2.2. Effects of the MELC on Liver Histology

The liver tissues in the normal control group showed normal parenchymal architecture with no cellular necrosis (A), but the liver tissues of Rat administered with paracetamol only, showed necrotic hepatocytes, hyperaemic/congested blood vessels and infiltration of inflammatory cells (B). Liver tissues of the Rat treated with 400mg/kg showed normal hepatocytes and regeneration of liver cells were observed. Regeneration of the liver cells was evidenced by observing mitosis indicators in the liver tissues (Figure 1).

4. Discussion

As many of the chemicals pass through the liver to enter the general circulation; the liver is at a higher risk to be damaged than other organs. [22] Hepatotoxicity is a significant problem in patients taking paracetamol intentionally or accidentally; causing acute liver failure.[23] The evaluation of protective activity in liver damage induced by paracetamol has been widely used for hepatoprotective drug screening. Hepatotoxicity with paracetamol is due to its highly reactive metabolite, NAPQI.[24] Increase in NAPQI quantity leads to glutathione depletion, which finally causes an alteration in homeostasis, an increase in the permeability of the cell membrane with a consequent cellular swelling, karyolysis, vacuolization of hepatocytes and an elevation of liver enzymes. [25].

The main enzyme levels elevated during liver injuries are SGOT, SGPT & ALP, BIT, BID & ALB. The reason is that these enzymes are mainly found in the liver and are released into the blood as a result of liver injury. There is also a reduction in the total protein and albumin levels due to disruption and dissociation of polyribosomes on endoplasmic reticulum resulting in decreasing the biosynthesis of protein.[26]. In the present study, the plant extracts showed a dose-dependent free radical scavenging activity; by which the crude extract showed antioxidant activity with IC₅₀ of 204.3 µg/mL. The antioxidant activity may be attributed due to the presence of secondary metabolites including flavonoids, polyphenols, and coumarins. This is in agreement with the previous findings reported by Alghazeer et al (2018); Sharma et al (2016); Teshome et al (2015); Torres et al (2006). [27, 28,29,30] The variation in antioxidant activities of the plant extracts could be due to a difference in the amount and kind of phytochemicals present in the crude extract and solvent fractions of the plant.

Boddupally et al., 2023

significantly elevated direct bilirubin concentration in animals by inducing hepatic damage compared to normal animals. But treatment with standard drug Silymarin showed good reduction in direct bilirubin concentration. Groups treated with MELC significantly reduced direct bilirubin level in respective groups. Induction of liver damage by administration of paracetamol significantly reduced serum albumin level in positive control group animals when compared to normal animals.

An increase in liver weight is an indication of liver injury.[31] In the present study, liver weight of the Rat administered with paracetamol alone significantly increased compared to the normal control group (P<0.01). The reason is that water is retained in the cytoplasm of hepatocytes leading to enlargement of liver cells, resulting in increased total liver mass. [32] In our study, the MELC administered at a dose of 400 mg/kg reduced liver weight of the Rat significantly (P<0.05). Pretreatment of the Rat with different doses of the crude extract and solvent fractions combined with paracetamol demonstrated hepatoprotective activities against paracetamol-induced liver injury; reducing the elevated levels of SGOT, SGPT & ALP, BIT, BID & ALB (P<0.001).

As explained by Trifunski et al (2015), the hepatoprotective activities of the plant extracts could be due to their free radical scavenging activity. [33] Additionally, their anti-inflammatory activity could contribute to their hepatoprotective activity, as paracetamol toxicity produces inflammatory mediators such as monocytes, neutrophils and cytokines (interleukin-6 and tissue necrosis factor α). [34] Other liver protective activities of the plant extracts could be; (1) inhibition of metabolism of paracetamol; because, metabolism of paracetamol with cytochrome P450 enzymes specifically, CYP2E1, is implicated in the hepatotoxicity of paracetamol by producing toxic metabolite, NAPQI. As a result, inhibition of this enzyme by the plant extracts could possibly reduce the toxic effects of paracetamol; [35] and (2) an increase in glutathione level, which is reduced during paracetamol overdose due to production of excess NAPQI level. Excess NAPQI alkylates and oxidizes intracellular glutathione resulting in liver glutathione depletion subsequently leads to increased lipid peroxidation and liver damage. [36] Thus, administration of the crude extract and solvent fractions might increase the glutathione level as a mechanism to protect paracetamol-induced liver damage in Rat.

Hepatoprotective activities of the plant extracts could be due to the presence of phytochemicals such as polyphenols, alkaloids, flavonoids, saponins and coumarins which possess' hepatoprotective activity either alone or in combination. These findings agree with other studies that have shown the hepatoprotective activity of these phytoconstituents. The mechanism of these phytochemicals for their hepatoprotective activity is mainly due to their free radical scavenging activity since the plant extracts contain different phytoconstituents which possess free radical scavenging activity. Additionally, the phytochemical flavonoid could maintain cell membrane stability or could protect cell membrane leakage up on damage by paracetamol as evidenced by a reduction in the liver biomarkers. This is in line with the findings of Tarahovsky et al (2014) [37]. Furthermore, the anti-inflammatory effect

of the secondary metabolites such as alkaloids, saponins, coumarins and flavonoids could be the means for their hepatoprotective activity. This finding concurs with other studies that have shown the anti-inflammatory activity of these phytochemicals.

Histopathologic findings revealed protective activities of the crude extract and solvent fractions against paracetamol-induced liver damage which is in good agreement with the results of the biochemical activities of the plant extracts and Silymarin. The section of the paracetamol intoxicated liver tissue demonstrates hepatic necrosis, condensed blood vessels and aggregation of inflammatory cells. This may be a result of the formation of free radicals and oxidative stress induced by paracetamol. These pathological changes were lesser in the Rat administered with the different doses of the plant extracts and Silymarin followed by simultaneous administration of paracetamol. This indicates that treatment of the Rat with the plant extracts and Silymarin may prevent paracetamol-induced liver damage.

5. Conclusion

In conclusion, the present results show that the crude extract of *Lantana Camara* demonstrated antioxidant and hepatoprotective activities. The hepatoprotective activities of the plant extracts could be due to their free radical scavenging and antioxidant activities, resulting from the presence of some phytochemicals including polyphenols, flavonoids, saponins and alkaloids. Furthermore, the exact phytoconstituents and their mechanism of hepatoprotection should be studied. Additionally, these findings could justify the traditional use of the root bark of *Lantana Camara* in liver disorders; and suggest the possible utilization of the root bark of the plant as a source of new compounds for hepatoprotective activity.

References

- [1] T.Y. Park, M. Hong, H. Sung, S. Kim, K.T. Suk. (2017). Effect of Korean *Red ginseng* in chronic liver disease. *Journal of Ginseng Research*. 41(4):450–455. doi:10.1016/j.jgr.2016.11.004
- [2] S.I. Alqasoumi, M.S. Abdel-Kader. (2012). Screening of Some Traditionally Used Plants for Their Hepatoprotective Effect, Phytochemicals as Nutraceuticals - Global Approaches to Their Role in Nutrition and Health. *InTech*. 256–278.
- [3] A. Kumar. (2012). A review on hepatoprotective herbal drugs. *International Journal of Research in Pharmacy and Chemistry*. 2(1):96–102.
- [4] L. Yin, L. Wei, R. Fu et al. (2014). Antioxidant and hepatoprotective activity of *Veronica ciliata* fisch. extracts against carbon tetrachloride-induced liver injury in Rat. *Molecules*. 19(6):7223–7236. doi:10.3390/molecules19067223
- [5] H. Jaeschke. (2015). Acetaminophen: dose-dependent drug hepatotoxicity and acute liver failure in patients. *Digestive Diseases*. 33(4):464–471. doi:10.1159/000374090
- [6] L. Hussain, J. Ikram, K. Rehman, M. Tariq, M. Ibrahim, M.S.H. Akash. (2014). Hepatoprotective effects of *Malva sylvestris l.* against paracetamol-induced hepatotoxicity. *Turkish Journal of Biology*. 38(3):396–402. doi:10.3906/biy-1312-32
- [7] V. Jannu, P.G. Baddam, A.K. Boorgula, S.R. Jambula. (2012). A review on hepatoprotective plants. *International Journal of Drug Development and Research*. 4(3):1–8.
- [8] E. Sabiba, M. Rasool, M. Vediet al. (2013). Hepatoprotective and antioxidant potential of *Withaniasomnifera* against paracetamol-induced liver damage in rats. *International Journal of Pharmacy and Pharmaceutical Sciences*. 5(2):648–651.
- [9] S.K. Jain, S. Rajvaidy, P. Desai, G. Singh, B.Nagori. (2013). Herbal extract as hepatoprotective-a review. *Journal of Pharmacognasy and Phytochemistry*. 2(3):170–175.
- [10] C. Manjunath, T. Balasubramannian, D. Gnanasekaran, A.U. Kumar, Y.Brahmaiah. (2012). Evaluation of hepatoprotective activity of *Haldinia cordifolia* against paracetamol induced liver damage in rats. *Der Pharmacia Letter*. 4(3):768–774.
- [11] M. Sobeh, M.F. Mahmoud, R.A. Hasan, H. Cheng, A.M. El-Shazly, M. Wink. (2017). *Senna singueana*: antioxidant, hepatoprotective, anti-apoptotic properties and phytochemical profiling of a methanol bark extract. *Molecules*. 22(9):1502. doi:10.3390/molecules 22091502
- [12] M. Sobeh, M.F. Mahmoud, R.A. Hasan et al. (2018). Tannin-rich extracts from *lanneastuhlmannii* and *lannea humilis* (anacardiaceae) exhibit hepatoprotective activities in vivo via enhancement of the anti-apoptotic protein Bcl-2. *Scientific Reports*. 8(1):1–6. doi:10.1038/s41598-018-27452-8
- [13] Harborne. (1973). *Phytochemical Methods: A Guide to Modern Techniques of Plant Analysis*. United States of America: Chapman and Hall. 1–276.
- [14] T. Teshome, B. Sintayehu, H. Yohannes et al. (2015). Radical scavenging activity and preliminary phytochemical screening on aerial part extracts of *Cineraria abyssinica* Sch. Bip. *Journal of Pharmacognosy and Phytochemistry*. 3(6):239–243.
- [15] A. Braca, N.D. Tommasi, L. Di Bari, C. Pizza, M. Politi, I. Morelli. (2001). Antioxidant principles from *Bauhinia tarapotensis*. *Journal of Natural Products*. 64(7):892–895. doi:10.1021/np0100845
- [16] Y. Gong, X. Liu, W.H. He, H.G. Xu, F. Yuan, Y.X. Gao. (2012). Investigation into the antioxidant activity and chemical composition of alcoholic extracts from defatted marigold (*Tagetes erecta L.*) residue. *Fitoterapia*. 83:481–489.
- [17] M.I. Qadir, M. Ali, M. Saleem, M. Hanif. Hepatoprotective activity of aqueous methanolic extract of *Viola odorata* against paracetamol-induced liver injury in Rat. *Bangladesh Journal of Pharmacology*. 9(2):198–202.
- [18] M. Saleem, B. Ahmed, M. Karim et al. (2014). Hepatoprotective effect of aqueous methanolic extract of *Rumex dentatus* in paracetamol-induced

- hepatotoxicity in Rat. Bangladesh Journal of Pharmacology. 9(3):284–289. doi:10.3329/bjp.v9i3.18874
- [19] B. Auddy, M. Ferreira, F. Blasina, L. Lafon, F. F. Arredondo. Dajas, P.C. Tripathi, T. Seal, and Mukherjee B. Screening of Antioxidant Activity of Three Indian Medicinal Plants Traditionally used for the Management of Neurodegenerative Diseases. Journal of Ethnopharmacology. 84:131–38.
- [20] R. Walker, W. Cate. (2007). Liver diseases. Clinical Pharmacy and Therapeutics. Churchill Living Stone: 4th edition; London: 221–22,
- [21] U. Satyanarayana, Chalrapani. (2008). Liver Function Tests. Fundamentals of Biochemistry Kolkata; 2006: 453–58, Deb AC. Liver Function Tests. Fundamentals of Biochemistry. 8th edition; Kolkata. 6:581.
- [22] M. Saleem, B. Ahmed, and M. Karim M, et al. (2014). Hepatoprotective effect of aqueous methanolic extract of *Rumex dentatus* in paracetamol-induced hepatotoxicity in Rat. Bangladesh Journal of Pharmacology. 9(3):284–289. doi:10.3329/bjp.v9i3.18874
- [23] N.S. Uchida, S.E. Silva-Filho, G.F.E. Cardia et al. (2017). Hepatoprotective effect of *Citral* on acetaminophen-induced liver toxicity in Rat. Evidence-Based Complementary and Alternative Medicine. 1–9. doi:10.1155/2017/1796209
- [24] B. Ramu, K. Kaushal, P. Chandrul, S. Pandiyan. (2021). Using 24 Factorial Designs optimization of Repaglinide Gastroretentive Drug Delivery System. Research Journal of Pharmacy and Technology. 14(2):725–729.
- [25] R. Tittarelli, M. Pellegrini, M. Scarpellini et al. (2017). Hepatotoxicity of paracetamol and related fatalities. European Review for Medical and Pharmacological Sciences. 21(1):95–101.
- [26] T. Teshome, B. Sintayehu, H. Yohannes et al. (2015). Radical scavenging activity and preliminary phytochemical screening on aerial part extracts of *Cineraria abyssinica* Sch. Bip. Journal of Pharmacognasy and Phytochemistry. 3(6):239–243.
- [27] R. Alghazeer, S. Elgahmasi, A.H. Elnfati et al. (2017). Antioxidant activity and hepatoprotective potential of flavonoids from *Arbutus pavarii* against CCl₄ induced hepatic damage. Biotechnology Journal International. 21(1):1–12. doi:10.9734/BJI/2018/39528
- [28] S. Sharma, S. Rana, V. Patial, M. Gupta, S. Bhushan, Y. Padwad. (2016). Antioxidant and hepatoprotective effect of polyphenols from *Apple pomace* extract via apoptosis inhibition and Nrf2 activation in Rat. Human and Experimental Toxicology. 35(12):1264–1275. doi:10.1177/0960327115627689
- [29] R. Torres, F. Faini, B. Modak, F. Urbina, C. Labbé, and J. Guerrero. (2006). Antioxidant activity of coumarins and flavonols from the resinous exudate of *Phytochemistry*. 67(10):984–987. doi:10.1016/j.phytochem.2006.03.016
- [30] N. Mahmood, S. Mamat, F. Kamisan et al. (2014). Amelioration of paracetamol-induced hepatotoxicity in rat by the administration of methanol extract of *Muntingia Calabura* L. leaves. BioMed Research International. 1–10.
- [31] W.A. Mulla, V.R. Salunkhe, S.B. Bhise. (2009). Hepatoprotective activity of hydroalcoholic extract of leaves of *Alocasia indica* (Linn.). Indian Journal of Experimental Biology. 47(10):816–821.
- [32] S.I. Trifunski, M.F.F. Munteanu, D.G. Ardelean, M. Orodan, G.M. Osser, R.I. Gligor. (2015). Flavonoids and polyphenols content and antioxidant activity of *Ficus carica* L. extracts from romania. Matica Srpska Journal of Natural Sciences. 128(128):57–65. doi:10.2298/ZMSPN1528057T
- [33] H. Yoshioka, H. Usuda, H. Fujii, T. Nonogaki. (2017). *Sasa veitchii* extracts suppress acetaminophen-induced hepatotoxicity in Rat. Environmental Health and Preventive Medicine. 22(1):1–10. doi:10.1186/s12199-017-0662-3
- [34] M. Sharma, G. Sharma, V. Vishal, B. Ranjan. (2015). Hepatotoxicity: a major complication with critical treatment. MOJ Toxicology. 1(3):1–7.
- [35] C. Rao, A. Singh, G. Kumar, S. Gupta, S. Singh, A. Rawat. (2015). Hepatoprotective potential of *Ziziphus oenoplia* (L.) mill roots against paracetamol-induced hepatotoxicity in rats. Advanced Journal of Phytomedicine and Clinical Therapy. 3(1):064–078.
- [36] Y.S. Tarahovsky, Y.A. Kim, E.A. Yagolnik, and E.N. Muzafarov. (2014). Flavonoid–membrane interactions: involvement of flavonoid–metal complexes in raft signaling. Biochemistry and Biophysics Acta. 1838(5):1235–1246. doi:10.1016/j.bbame.2014.01.021.