



Prevalence of oral dermatological conditions diagnosed with clinical and histopathological examination in a rural tertiary care

Sweta S. Kumar ¹, Geeta Maurya ², Sanjeev Kumar Singh ³, Sanjay Kumar Kannaujia ^{4*},
Rashmi ⁵

¹Associate Professor, Department of Dermatology, Venerology and Leprology, UPUMS, SAIFAI, UP India

^{2,4*,5}Associate Professor, ³Professor Junior grade, Department of Pathology, UPUMS, SAIFAI, UP India

Abstract

Oral health is the overall reflection of internal well-being. Oral mucosal lesions are seen in various dermatological diseases and systemic diseases. Sometime oral lesions are the early precursor of my chronic conditions & nutritional status. Hence dermatological examination is incomplete without mucosal examination. The present study was conducted to find out the prevalence, diversity & clinical characteristic of various mucosal lesions in patients attending dermatology OPD. All the patients having oral mucosal lesions fulfilling the inclusion & exclusion criteria, attending the dermatology OPD was included in the study. Detailed clinical history, thorough physical examination & clinical photographs were recorded for all the patients. In present study, the overall prevalence of oral mucosal lesions was 0.6% (152/25,000). Out of 152 patients, 63 were males and 89 were female with M:F ratio is 0.7:1. Majority of patients fall in age group 41-60 years. The prevalence rate of oral mucosal involvement is relatively low. But any lesion in oral mucosa should not be neglected as it could be the early predictor of underlying diseases. And number of times, it was missed by Dermatologist, Dental & ENT surgeons. Hence, multidisciplinary approach will surely help in better outcome of patients.

Keywords: Oral mucosal lesions, Pemphigus vulgaris, Histopathology, Tobacco Chewer.

Full length article *Corresponding Author, e-mail: sanjaykannaujia1@gmail.com

1. Introduction

The oral cavity plays an important role in mastication, digestion, speech and immunologic defense. Since ages, oral mucosa has been considered as mirror of overall general health. The oral cavity occupies a unique position in the human body, with respect to its development, structure, micro biology function and disease. The oral mucosa is very important as skin and mucosa both originates from the ectoderm. The tongue has a dual origin the anterior 2/3rd is formed by oral ectoderm & the posterior 1/3rd from endoderm. The oral cavity can play a pivotal role in the diagnosis of oral as well as systemic diseases. The oral cavity should be examined in a systemize manner including the lips, gingio-buccal sulcus, buccal mucosa, gingival, teeth, palate, tongue and oropharynx. In various systemic diseases, oral mucosal lesions may be the presenting complains to establish the diagnosis. Mucocutaneous lesions are mainly observed in dermatology, ENT & Dental practices [1]. Abnormalities or diseases of oral cavity are either localized or confined to the oral mucosa, gingival tongue, palate and teeth or are signs and symptoms of systemic, acquired, or inherited disorders and

genodermatoses. Conditions affecting the oral mucosa may be normal variant, congenital abnormalities, restricted to oral mucosa, infections, a reactive process or neoplasia. Many skin diseases are associated with oral mucosal lesions like, autoimmune disorders, pigmentary disorders, infections, dermatitis, drug reactions nutritional deficiencies, sexually transmitted diseases and cancers etc. The oral mucosal lesions clinically appear as erythematous, ulcerative area painful or painless, excessive drooling of saliva, crusting, desquamation with associated keratosis. The diagnosis of mucocutaneous disorders is clinical, but histology & immune fluorescence are required, because lesions used to resemble each other. These investigations allow early diagnosis, treatment monitoring of disease activity in patients having life – threatening disorders. Special care & consideration are required in mucocutaneous disorders due to morbidity & mortality factors, an early intervention should be planned [2]. This interdisciplinary approach reinforces the treatment standards as well as better prognosis of the disease may be expected.

In our literature search regarding oral lesions, we have found only three published papers about the prevalence of

mucosal lesions in skin diseases. Goncatres et al., in 2009, included 88 patients with frequency of oral mucosal lesions was 36.7%. Silliman et al in 2001, observed 57.9% Sudanese population have oral mucosal lesions with dermatological diseases [3]. Ramirez – Amador et al., in 2000 suggested the frequency of oral mucosal lesions was 2.8% [4]. The present study was done to document the frequency & diversity of oral mucosal lesions in patients with dermatological diseases and diagnoses were confirmed by Histopathological examination wherever, required.

2. Materials and Methods

This was a prospective, cross-sectional study conducted among 152 patients who had oral lesions irrespective of age, gender and duration of illness attending dermatology OPD UPUMS, Saifai, for the duration of the study was from 1st July 2021 till 31st Dec 2022 (18 Months). Patients were thoroughly examined for skin & mucosal lesions. The examination includes evaluation of musculoskelton and soft tissues of head and neck including lymph nodes, thyroid and salivary gland and complete mucocutaneous examination. All routine Hematological, Histopathological, KOH mount scraping, Tzanck smear, Immunofluorescence diagnostic procedures were carried out wherever required clinical photographs were taken after informed consent.

2.1. Inclusion Criteria

All patients having oral mucosal lesions attending dermatology OPD were included in this study.

2.2. Exclusion Criteria

1. Patients who were not willing to participate in the study.
2. Patients having restricted mouth opening.

All patients fulfilling inclusion & exclusion criteria were enrolled; written consent was obtained from all the patients willing to participate in the study. All the clinical data were entered in a standard preformed Performa. The results were analyzed by SPSS software version 21.0 (NY, Armonk) and presented descriptive statistics, correlation between skin & mucosal lesion was statistically analyzed by person's correlation test $CP > 0.05$ were considered as statically significant.

3. Results

This study was conducted on 25,000 patients who attended the dermatology OPD in UPUMS, Saifai. All the patients were specifically screened for oral mucosal lesions, out of them 152 had oral lesions with a prevalence of 0.6%. Out of 152 patients, 63 were males and 89 were female with M:F ratio is 0.7:1. The mean age of patient was $27-34 \pm 21-30$. The maximum number of patients was in the age group of 41-60 years 32.89% (Table 1). The patients were distributed in the younger (< 40 years) and older (> 40 Years). The age and disease distribution are statistically significant with ($P < 0.001$) (Table 1) (Graph 1). Out of 152 patients 41 (26.92%) patients gave history of tobacco and Bettle nutuse and 101 (66.4%) did not give any such history. Twenty-six (17.1%) had diabetes mellitus and 09 (5.9%) had HIV. The majority of patients were Farmers 47 (30.9%) followed by housewives 30 (19.77%) (Table 2). Distribution of patients

according to occupational status as employed and unemployed showed statistical significance results with ($P < 0.001$) (Table 3). Eleven children were excluded as they cannot be classified in any occupation status. In our study, out of 152 patients, 26 (17.1%) patients had oral candidiasis (Fig. 1) followed by apthous ulcer 20 (13.15%) (Fig. 2), oral lichen planus 19 (12.5%) (Fig. 3), Mucosal vitiligo 18 (11.8%) (Fig. 4) and Fordyce spots 9 (5.92%) (Fig. 5) (Table 3). Out of 152 patients 113 (74.3%) had skin & oral mucosal lesions, whereas 48 (31.5%) had only oral mucosal lesions (Table 4).

4. Discussion

Many dermatological conditions are associated with oral mucosal lesions, but few specific skin disorders could involve only oral mucosa. The etiology behind could be autoimmune, infectious or an adverse drug event. Out of 25,000 patients with dermatological diseases 152 patients had oral lesions with a prevalence of 0.6% this was comparable to previous other studies done by Roy et.al. and Ramirez – Amador et al reported that the prevalence of 1.26 % and 1.8 % respectively. The prevalence of oral mucosal lesions is influenced by genetic predisposition, geographic distribution and sample size. In our study 13.81 patients were laborers; this was similar with the results of Libu et al. The contributory factor could be personal hygiene, socio-economic status and less health conscious. In our study M:F ratio was 7:1, Females outnumber Males which was discordant with studies done by Anand et al and Shiva Kumar et al. showed Male & Female ratio 1.4:1. The mean age of our study population is 27.34 ± 21.30 which is similar to studies done by Keswani et al with a mean age of 32.7. According to our study 14% of patients have positive history of Tobacco Chewing and 12% of patients had history of beetle nut consumption. According to study done by Shiv Kumar et al history of Tobacco use was 26.92% which is comparable to our study, similar study was done by Mishra et al, history of smoking was there in 34.7% and history of chewing beetle nut was 17.3% which is almost similar to our study. In our study, out of 152 patients with oral lesions 113 (74.3%) has mucocutaneous manifestations, whereas 39 (25%) had only oral mucosal lesions [5-6]. According to study done by Ramirez et al. Oral diseases were seen in (35%) Patient which was slightly higher than our study. But our study was similar to studies done by Keswani et al., and Shiv kamar et al. The percentage of patients with oral lesions ranging from (21% - 23%). In our study among 152 patients with oral lesions oral candidiasis was found in 26 patients (17.10%) & oral LP in 19 patients (12.5%) patient which is similar to studies done by Roy et al in which oral candidiasis was seen in (16.07%) and oral LP was seen in 12.7 % patients [7-8]. In our study apthous ulcer was seen in 13.15% which is much higher as compared to other studies done by Mathew et al and Ramirez et al whose results are 2.2% and 6.9% respectively. According to Keswani and Roy the percentage of apthous ulcers are 31.4% and 28.57% respectively which is much higher as compared to present study. In our study Leukoplakia was seen in one patient which is much lower than studies done by Mathew et al, and Gulati et al in which Leukoplakia was seen in 1.59% and 1% respectively.

However, study done by Keda et al. on Japanese patients, Leukoplakia was seen in 25% patients which is much higher than present study. Mostly patients were in age group more than 50 years. Dorey et al., found in his study that

Leukoplakia was mostly seen in age group 50- 70 years and men have slightly more preponderance than females [9]. Mostly patients had history of Tobacco chewing & smoking. In our study 14 patients having lichen planus with both mucocutaneous manifestations, out of 14, 6 patients have only oral lesions. These results are in concordance with the study done by Babu et al., who showed 72 patients with lichen planus, and 12 patients showed mucosal lesions. The most common variant was reticular type with female preponderance. Out of 12 patients of pemphigus having skin and oral manifestations, 4 patients have only oral mucosal involvement. These results are similar to studies done by Olireira Alres et al., which showed that the prevalence of pemphigus was 6% with female out number males [10-12]. Tharnhill et al., found that Histopathological features of pemphigus are very characteristics, but may might be not specific. Majority patients fall in age group 30-40 years with female predilection? The mucosal lesions start as papule or vesicle, which ruptures with ulcerative painful, erythematous area with exercise drooling of saliva & difficulty in swallowing. Cytological examination under microscope reveals acantholytic cell, track cells in Hematoxylin & eosin stain. Perilesional, skin biopsy showed acantholytic; supra-basal splitting, Basal cells are arranged in tombstone pattern. Direct Immunofluorescence showed Immunoglobulin (IgG)

deposition in fish net manner. This is in concordance with study done by Shamim et al., where oral lesions were the main site of predilection with severe ulceration. Anuradha et al., showed that IgG deposition in fish net manner in 86% patients and C3 positive in 14% of patients. Staley et al., founded specific histopathological features in pemphigus-vulgaris, acantholytic and blister formation in suprabasal layer. In over study, 21 patients of drug reaction with both skin and oral manifestations. 13 (61.9%) patients having drug reaction, there were only involvement of oral mucosa. The oral lesions are erosive, painful, erythematous present over lower lip, buccal mucosa, tongue and soft palate. Out of 152 patients, Stevens Johnson syndrome was observed in 0.6% patients. This finding is consistent with the study done by Singh et al., who stated that Stevens Johnson syndrome was seen in 0.3% of patients taking oral nevirapine within 4-6 weeks of ART initiation. Mason et al., found that oral lesions occurred after 28 days of drug intake [13-14]. Most common offending drug for drug reaction was Norflox, NSAIDS, Antiepileptic drugs, Antipsychotic drugs. Patients of drug reactions have HLA susceptibility. Namayanja et al., in 2005 stated that those persons having HLA BW44, HLA DQB1 and HLA B12 are more susceptible for toxic epidermolysis necrosis and Stevens Johnson syndrome and erythema multiform.

Table 1: Age Distribution.

Age (in years)	No of Patient				Total	Percentage out of 152 cases
	Males		Females			
	Number	%age	Number	%age		
0-20	08	15.09	13	14.60	21	13.81
20-40	17	26.98	31	34.83	48	31.57
40-60	23	36.50	27	30.33	50	32.89
>60	15	23.80	18	20.22	33	21.71
Total	63		89		152	100

Table 2: Distribution of study population according to age category by Binomial Test.

Age in two categories	Category	Number	Observed Prop	Test Prop	Exact significant (2 – failed)
Younger	< 40 Years	69	0.38	0.50	0.001*
Older	>40 Years	83	0.42		0.001*
P * < 0.01					

Table 3: Distribution of study population according to occupational status by binomial test.

Sr. No.	Occupation	No of Persons (152)	Percentage
1.	Farmer	47	30.9 %
2.	Laborers	21	13.81 %
3.	Driver	13	8.55 %
4.	Students	9	5.9 %
5.	Housewives	31	19.7 %
6.	Business	7	4.6 %
7.	Service	14	9.21 %

Occupational Status	Number	Observed Prop	Test Prop	Exact significant (2 – failed)
Unemployed	61	0.33	0.50	0.001*
Employed P * < 0.01	91	0.67		0.001*

Table 4: Frequency of various oral lesions in study population.

Sr. No.	Oral Mucosal Lesions	No of Patients (152)	Percentage (%)
1.	Oral Candidiasis	26	17.10 %
2.	Oral LP	19	12.5 %
3.	Apthous Ulcers	20	13.15 %
4.	Herpes Labials	19	12.5 %
5.	Leukoplakia	1	0.65 %
6.	Angular Cheilitis	9	5.92 %
7.	Pemphigus Vulgaris	11	7.23 %
8.	Fixed Drug Eruption	13	8.55 %
9.	Adverse Drug Reaction	4	2.63 %
10.	Mucosal Vitiligo	18	11.84 %
11.	Fordyce Spots	9	5.92 %
12.	Granulomatous Cheilitis	3	1.92 %

Table 5: Percentage of oral mucosal lesions with respective dermatological lesions.

Sr. No.	Lesions	No. of Pts with skin & oral manifestations 113 (68%)	No. of Pts with oral manifestations 39 (32%)	% age
1	Lichen Planus	14	06	42.8 %
2.	Vitiligo	18	09	50 %
3.	SLE	04	01	25 %
4.	Pemphigus	12	04	33.3 %
5.	Drug Reaction	21	13	61.90 %
6.	Viral Exanthema	36	06	16.66 %
	Total	104	39	

Table 6: Distribution of patients based on the oral manifestations.

Sr. No.	Distribution of pts based on oral mucosal lesions with respective dermatological lesions	Frequency	%age	Valid %age	Cumulative %age	Significant (two failed)	Persons correlate analysis (r value)
1.	No of pts with oral manifestations	39	7	7	100	0.001	0.432*
2.	No of pts with skin oral manifestations	113	109	1.9	100	0.001	0.432*

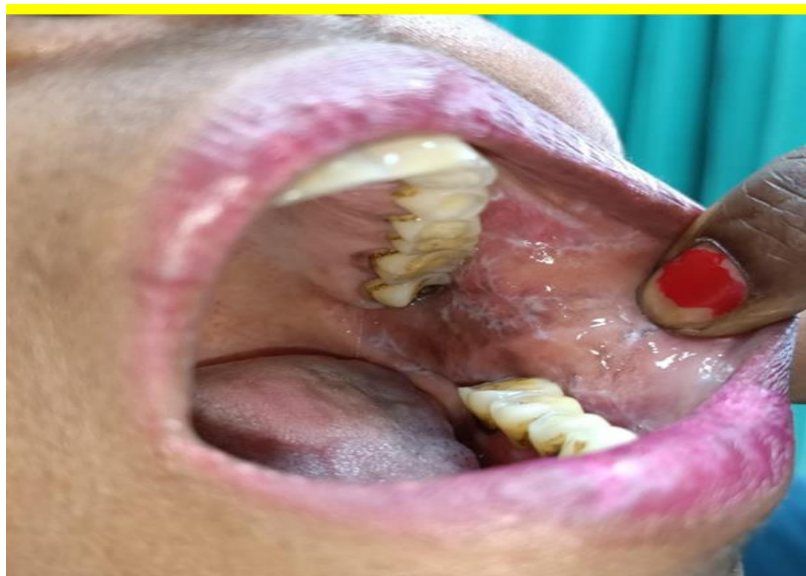

Fig. 1. Patients of oral Lichen Planus.

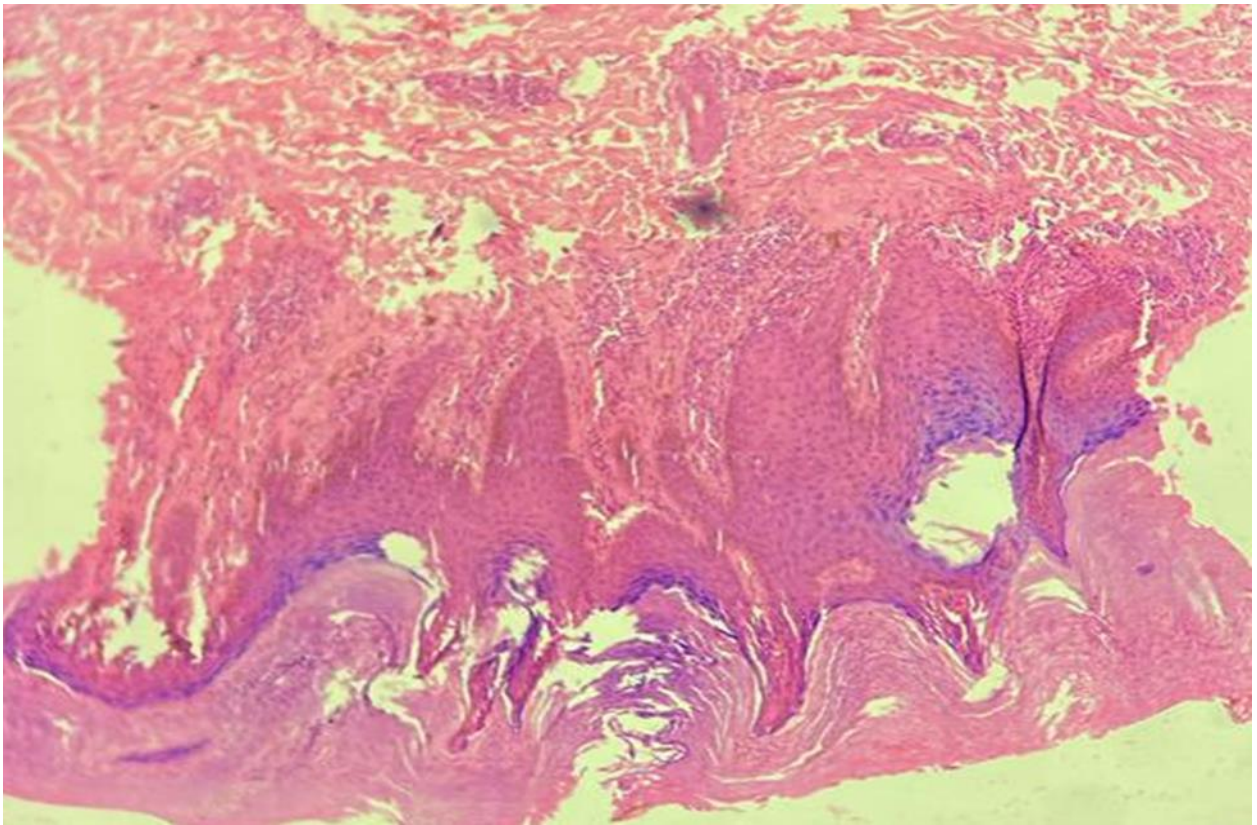


Fig. 2. Histopathological slide of lichen planus showed irregular epidermal hyperplasia forming a characteristic saw-tooth appearance with wedge-shaped hypergranulosis. The basal layer of the epidermis exhibits vacuolar degeneration with typically prominent necrosis of individual keratinocytes.

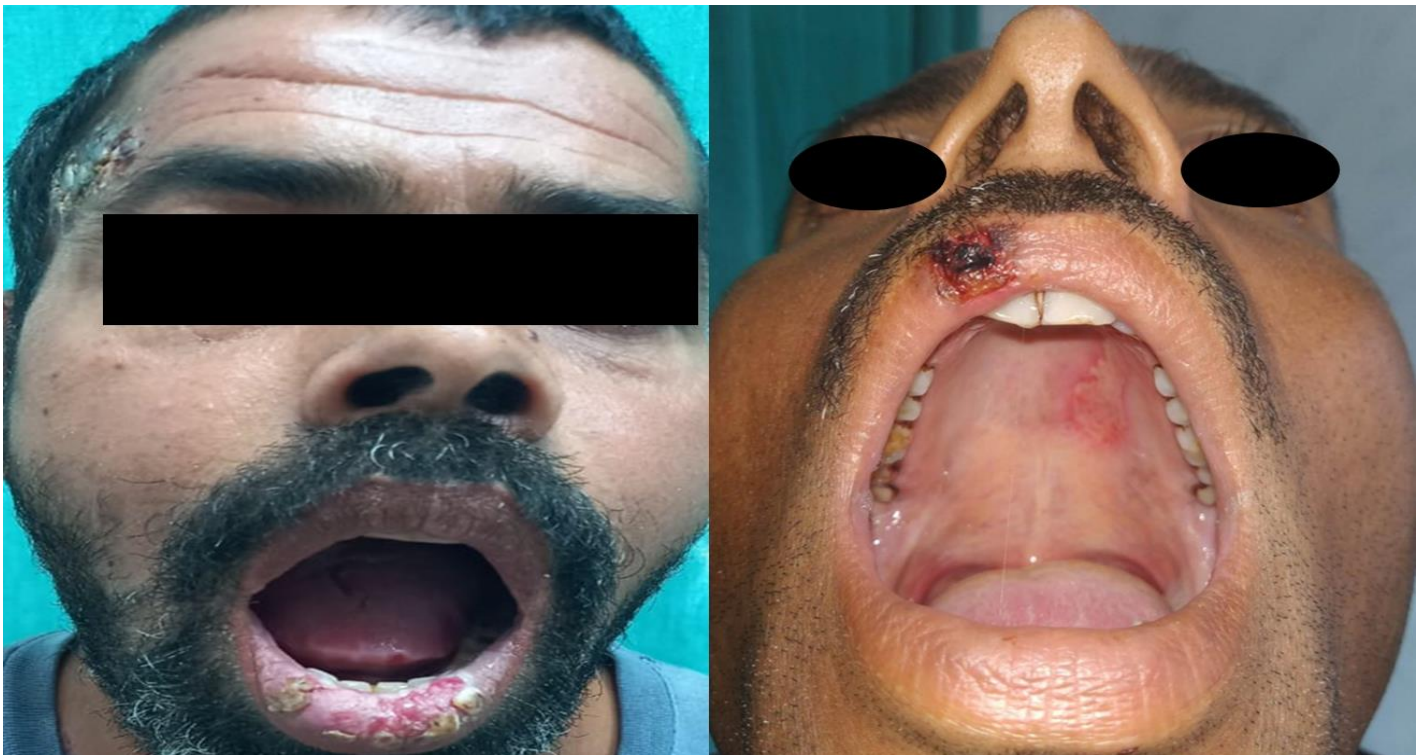

Fig. 3. Patients of Pemphigus Vulgaris.

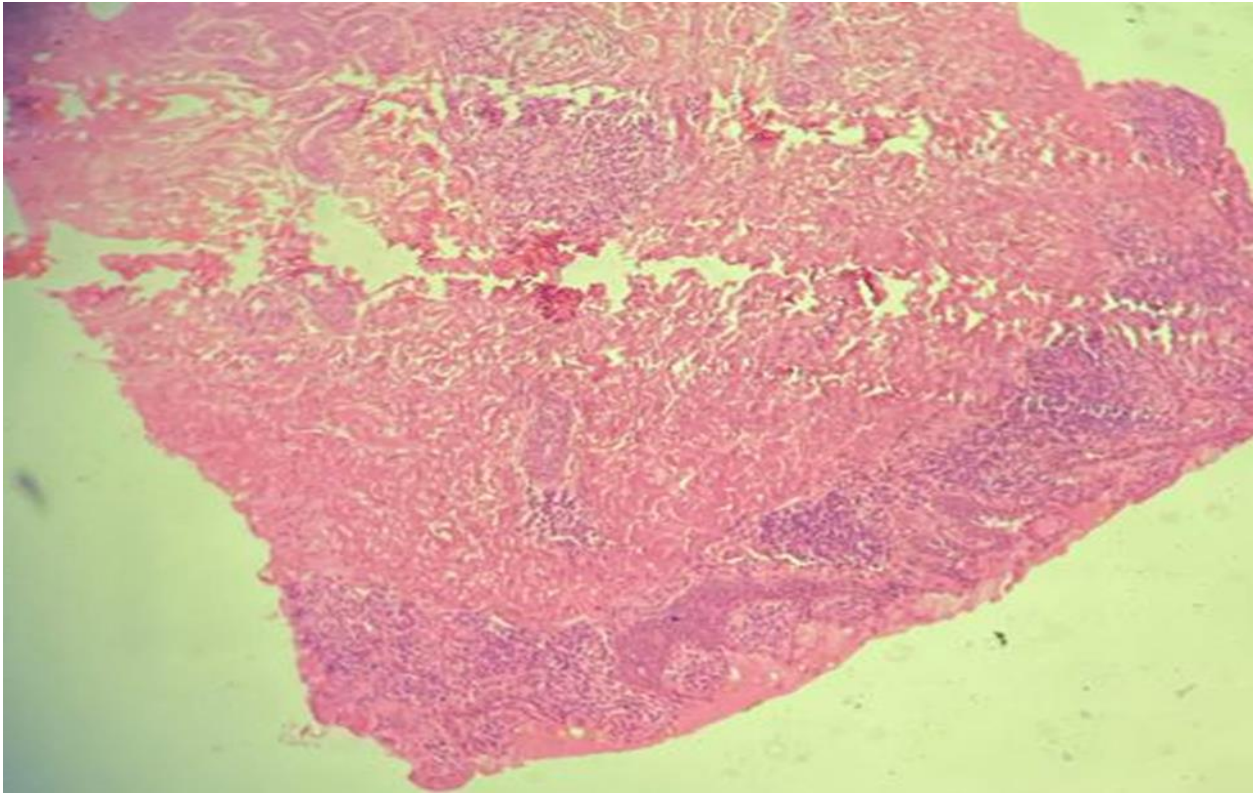


Fig. 4. Histopathological slide of pemphigus vulgaris showed suprabasal epidermal acantholytic, clef ting and blister formation. The blister cavity containing inflammatory cells including eosinophils.

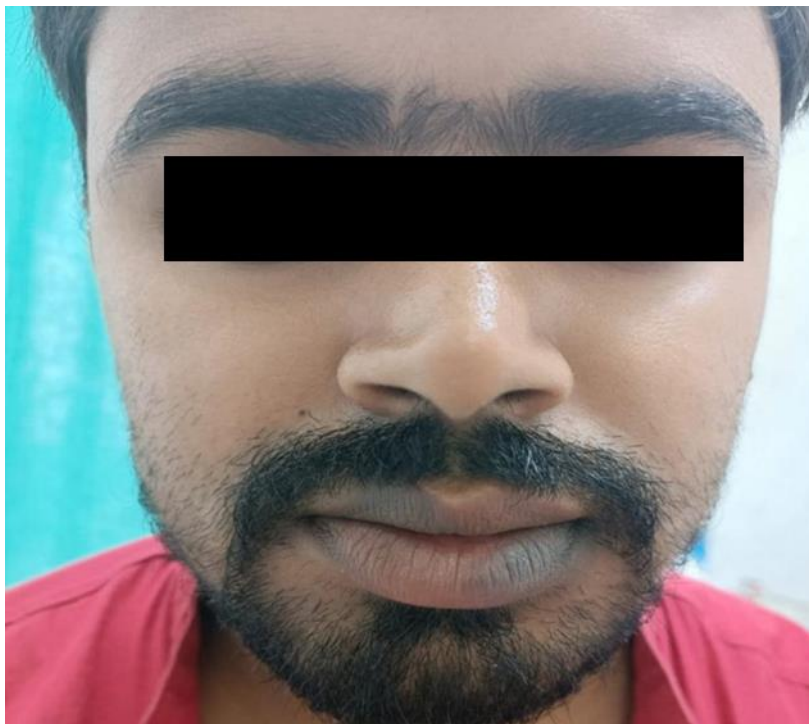

Fig. 5. Patient having FDE due to Norflox -Tz.

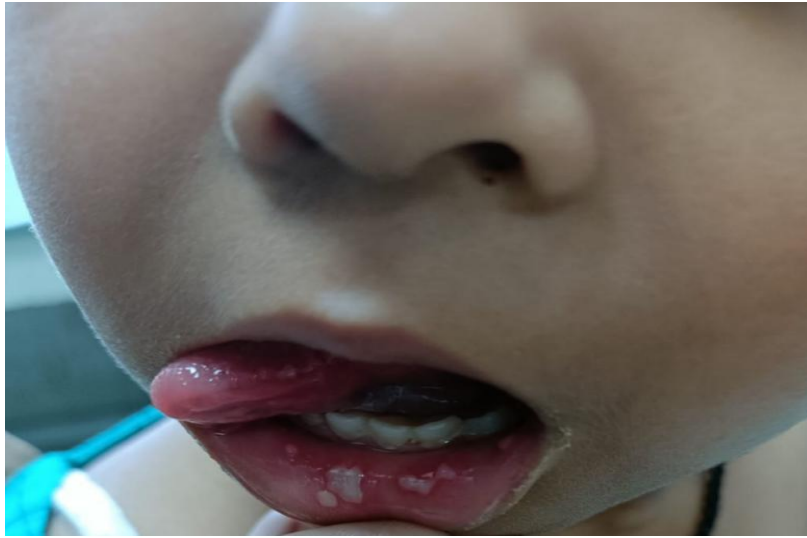

Fig. 6. Aphthous ulcer in 3-year-old baby.

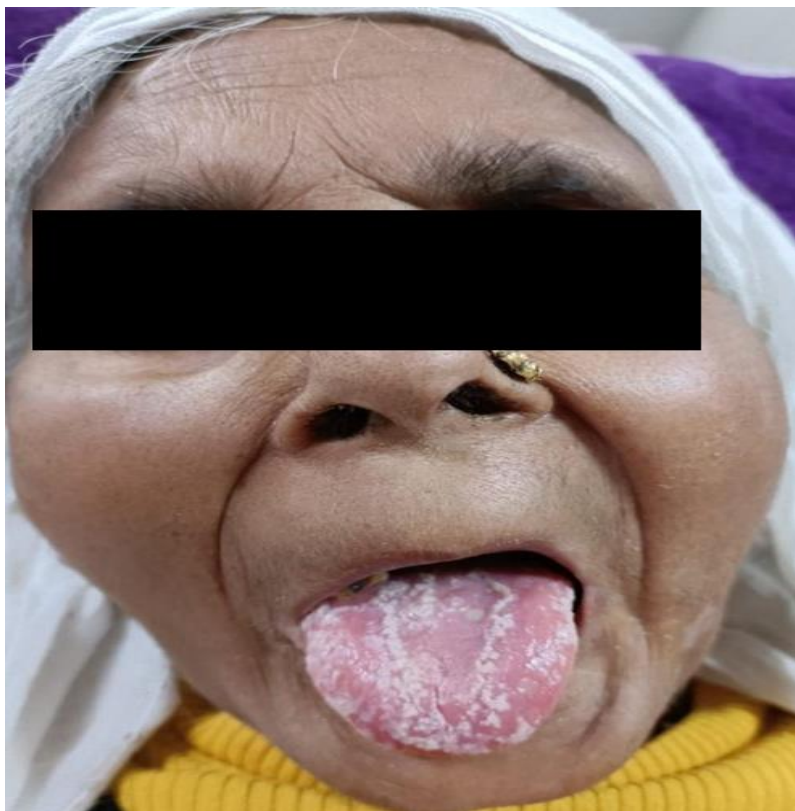

Fig. 7. Oral candidiasis in a female.

4. Conclusions

Oral mucosal lesions can be seen in wide variety of dermatosis and many systemic disorders. Oral mucosal examination should be the part any systemic examination, as many sign and symptoms of oral mucosa is missed by even dermatologist, ENT and dental surgeon. Further, large scale studies on prevalence of oral lesions should be conducted to know the burden of these diseases, widespread panoramic vision for the early diagnosis and prompt treatment. Hence multi-disciplinary approach is the need of the hour for better outcome for patients. Workup of the patients with oral complains requires an organized approach consisting of obtaining complete medical, dental dermatologic family, social and medication history and allergic reactions.

References

- [1] K. Pagrut, T. R. Ambade, & A. J. Asia. (2016). Mucosal lesions in patients attending Skin and STD Outpatient Department. Analysis of a Cohort of 300 cases. IOSR Journal of Dental and Medical Sciences. 16: 6-7.
- [2] P. M. Benson. (2004). Mucocutaneous manifestations of viral diseases: Stephen K. Tyring, MD, editor, New York, 2002, Marcel Dekker, Inc. 574 pages. \$195.00. ISBN 0-82-470450-9. Journal of the American Academy of Dermatology. 51 (1): 151.
- [3] D. Eisen, D. P. Lynch, & K. A. Arndt. (1998). The mouth: diagnosis and treatment. (No Title).
- [4] A. K. Pithawa. (2007). Sleisenger and Fordtran's Gastrointestinal and Liver Disease: pathophysiology, diagnosis, management. Medical Journal, Armed Forces India. 63 (2): 205.
- [5] B. E. Monk. (1993). Fordyce spots responding to isotretinoin therapy. British Journal of Dermatology. 129 (3): 355-355.
- [6] M. W. Adler. (1980). Variation in the diagnosis and notification of sexually transmitted diseases. Journal of Public Health. 2 (2): 109-119.
- [7] T. L. Ray. (1987). Oral candidiasis. Dermatologic clinics. 5 (4): 651-662.
- [8] M. Schiødt. (1984). Oral manifestations of lupus erythematosus. International journal of oral surgery. 13 (2): 101-147.
- [9] S. Roy, & S. Varshney. (2013). Oral dermatological conditions: A clinical study. Indian Journal of Otolaryngology and Head & Neck Surgery. 65: 97-101.
- [10] R. C. Jordan, T. E. Daniels, J. S. Greenspan, & J. A. Regezi. (2002). Advanced diagnostic methods in oral and maxillofacial pathology. Part II: immunohistochemical and immunofluorescent methods. Oral Surgery, Oral Medicine, Oral Pathology, Oral Radiology, and Endodontology. 93 (1): 56-74.
- [11] P. Caccianiga, G. Caccianiga, & G. Caccianiga. (2017). Photo-bio-modulation in orthodontics in order to promote proliferation and differentiation of keratinocytes: an in vitro study. European Journal of Musculoskeletal Diseases. 6 (2): 35-40.
- [12] C. Scully, O. Paes De Almeida, S. R. Porter, & J. J. H. Gilkes. (1999). Pemphigus vulgaris: the manifestations and long-term management of 55 patients with oral lesions. British Journal of Dermatology. 140 (1): 84-89.
- [13] M. G. Oliveira Alves, J. D. Almeida, I. Balducci, & L. A. Guimarães Cabral. (2010). Oral lichen planus: A retrospective study of 110 Brazilian patients. BMC research notes. 3 (1): 1-4.
- [14] S. Balasundaram, K. Ranganathan, K. Umadevi, R. Gunaseelan, N. Kumaraswamy, S. Solomon, ... & P. Ambrose. (2011). Oral lesions associated with nevirapine-related Stevens Johnson syndrome: A report of four cases. Journal of Oral and Maxillofacial Pathology: JOMFP. 15 (1): 39.