



# Acromioclavicular and coracoclavicular reconstruction by nylon tape sling versus hooked plate in management of acute acromioclavicular dislocation

*Mohamed Ibrahim Elwasifi, Ahmed Amin Galal, Mohamed Yousef\*, Sherif Hamdy  
Zawam*

*Department of Orthopedic Surgery, Faculty of Medicine, Cairo University, Egypt.*

## Abstract

The aim of this study was to compare between 2 modalities (Nylon Tape sling versus Hooked plate) for management of acute AC dislocations to reveal advantages and disadvantages of each modality. Sixty cases with acute acromioclavicular dislocation (Rockwood types III and V) were included in this study and were divided into 2 groups. **Group A** was treated using nylon tape sling and included 30 patients “28 males and 2 female” while **group B** was treated by using hooked plate and included 30 males. Constant score and American Shoulder and Elbow Surgeons (ASES) score were used to evaluate the results at six weeks, three months and 1 year after surgery. There was no statistically significant difference between group A & B as regard the Constant score and ASES score measured pre and post-treatment. But within each group, the scores showed statistically significant improvement after operation among groups A and B. Both AC and CC reconstruction by nylon tape showed good results without the need for implant removal and without complications linked to implants and graft source morbidity. Minimally invasive methods that may improve clinical outcome remain to be evaluated in further future studies.

**Keywords:** Acromioclavicular, Nylon tape, hooked plate, Constant score, ASES.

**Full length article** \*Corresponding Author, e-mail: [ptrservices2022@gmail.com](mailto:ptrservices2022@gmail.com)

## 1. Introduction

Acute acromioclavicular (AC) separation is a common injury among young individuals following direct trauma to the shoulder or a fall on an outstretched hand with the arm adducted [1]. AC joint dislocations account for 12% of all dislocations about the shoulder and are five times more common in males than in females [2]. Although this injury is highly prevalent, there is no consensus about its optimal treatment [3]. Commonly used methods include fixation of the AC joint with a K-wire or hook plate, dynamic muscle transfer, fixation between the clavicle and the coracoid with the use of a coracoclavicular screw, Weaver-Dunn procedure, and coracoclavicular (CC) ligament reconstruction by grafts, end buttons, non-absorbable sutures or tight rope [4]. The hooked plate is an effective method for fixation of acromioclavicular dislocation but it can cause disturbances over the plate end, acromial osteolysis, and migration of osteosynthesis material. Post-operative complaints of shoulder pain and limitation of movements are concerns, so its recommended to remove plate after healing to prevent impingement or rotator cuff and potential irritation of the acromion [4]. To

achieve reduction of an AC joint separation, novel procedures aim to restore maximum stability and, hence, early function by restoring the native AC and CC anatomy without any metal fixation. One of these procedures is nylon tape sling [5]. Coracoclavicular fixation using a sling was comparable with the intact CC ligament in terms of strength demonstrating less than 30% the stiffness of the native CC ligament. Despite satisfactory clinical reports, the use of non-absorbable slings has been associated with coracoid and clavicular erosion and infection in rare cases [6]. We focused in this study on young active people aging from 18-40 years old.

## 2. Materials and methods

This was a prospective randomized controlled clinical trial conducted on a total of 60 patients with acute acromioclavicular joint Dislocation. We included patients with Rockwood types III and V AC dislocations, patients with acute trauma for less than six weeks and with no history of AC joint pain but we excluded patients with Rockwood types I, II, IV and VI injuries or patients with

evidence of any AC arthrosis, or patients with any associated injury of the upper or with cervical radiculopathy.

### 2.1 Patients

sixty patients subdivided randomly by envelope method into 2 groups, 30 patients for each group. Group A included patients treated by Nylon tape and group B included Patients treated by hooked plate. This study was conducted after obtaining the hospital Research Ethics Committee approval and written informed consents from the patients.

### 2.2 Methods

All included patients were subjected to history taking that included age, sport and occupation and were subjected to complaint analysis that included the affected and dominant side, mode of trauma, with analysis of the pain by calculating ASES and Constant scores. The clinical examination included general examination and local examination of the neck and whole upper limb the local examination included inspection (inspection of the affected shoulder to detect any evidence of abrasions, skin tenting, muscle wasting or any deformities), palpation (tenderness over the AC joint), range of motion (ROM)(active and passive ROM and calculating the ROM by goniometer), neurovascular examination and provocative tests (e.g. cross arm adduction test was especially useful in patients with type I and II injuries in which visible or palpable deformity may not be present).

### 2.3 Scoring Systems

- 1- The American Shoulder and Elbow Surgeons Score
- 2- Constant score

### 2.4 Radiological Evaluation

Plain X-rays: A-P shoulder, Zanca view, stress A-P (showing both shoulders) and axillary lateral views. CC distance difference (between the upper border of the coracoid process and the inferior cortex of the clavicle).

### 2.5 Laboratory investigations

Routine preoperative lab tests to assess patient general condition and fitness for surgery.

### 2.6 Operative technique

Thirty patients were managed by nylon tape technique (Group A), while other 30 were managed by hooked plate (Group B). Both techniques have the same approach and patient position. All patients received general anesthesia with an endotracheal intubation. Beach chair position was used in all the cases. A surgical marking pen was used to accurately outline bony landmarks of the shoulder. Sterilization and draping were done, giving free access for surgery from the medial clavicular area to the upper one-third of the arm. An anterosuperior transverse skin incision is made, starting lateral at the AC joint and ending medial at the junction of the outer and middle thirds of the clavicle. The deltoid muscle (with the attached periosteum) was elevated off the anterior edge of the distal third of the clavicle. The deltoid was slightly inferiorly retracted until the coracoid process was exposed.

#### **In group A (AC and CC reconstruction by nylon tape)**

The clavicular insertions of the trapezoid and conoid ligaments are identified and marked on the upper clavicular surface with cautery. A nylon tape 70 cm x 6 mm (Ethicon) is passed around and flushes with the coracoid base by use of a right-angled clamp from the medial to lateral aspect. Two drill holes are made with a 2 mm drill bit at the conoid and trapezoid points from the superior to inferior aspect of the clavicle. The conoid hole is medial and posterior, usually 45 mm from the lateral end clavicle. While, the trapezoid hole is lateral and central, usually 25 mm from the lateral end clavicle. Both nylon tape ends are passed through these holes. After reduction of the AC joint, the nylon tape ends are tied above the clavicle, leaving one limb of the tape long enough for the rest of the procedure. A third drill hole is made through the acromion from the superior to anterior aspect (1 cm lateral to the AC joint) and a fourth drill hole made through the clavicle from anterior to superior (1 cm medial to the AC joint). The remaining long limb of the nylon tape is passed through the third hole as a superior AC ligament. Then, it is passed through the fourth hole anterior to the AC joint as an anterior AC ligament to make a second knot with the other limb of the tape.

#### **In group B (hooked plate is used):**

After exposing the acromioclavicular joint and identification of acromioclavicular ligaments and capsule and conoid and trapezoid ligaments if possible, by vicryl for later on repair, reduction of AC joint in place was done by transfixing of the joint with k-wire then applying a hooked plate with suitable height of its blade by plate holder then we took a c- arm image after removing of k-w, if reduction was accurate start drilling screws and then removal of plate holder, then starting repair of ligaments and capsule closure of deltopectoral fascia subcutaneous and skin.

### 2.7 Follow up strategy

Assessment was performed once at 6 weeks postoperative, then at 3 months and one year. This assessment included clinical and functional assessment (constant core and American Shoulder and Elbow Surgeons score), radiological assessment (plain radiograph at each visit: A-P shoulder (showing both shoulders), Zanca, and axillary lateral views. The CC distance was measured on either side and the difference will be estimated) and Complications assessed such as impingement, loss of reduction, infection...etc.

## 3. Results and discussion

The present study is randomized clinical trial that is carried out on 60 cases with acute acromioclavicular dislocation 30 cases were done by nylon tape & the other 30 cases were done using hooked plate to compare between 2 modalities. There was no statistically significant difference of age and sex of the studied groups with mean (SD) age of group A is 34.93 years Versus 33.67 years for group B. All cases in group B versus 93.3% of group A are males (table 1). Acromioclavicular (AC) joint dislocations are common injuries in young athletes, representing approximately 12% of all dislocations about the shoulder [7]. AC joint dislocations typically occur after either indirect force from a fall on an outstretched arm or by a direct impact to the shoulder and mainly affect active patients involved in contact sports. This leads to bulging of the lateral aspect of the clavicle, pain, and impaired shoulder function [8].

It is generally accepted that types I and II acromioclavicular (AC) joint injuries, as classified by Rockwood, 1990 are best managed conservatively, whereas types IV, V, and VI injuries generally require operative intervention [9]. The ideal acute treatment for grade III injuries remains controversial [10]. Commonly used methods include fixation of the AC joint with a K-wire or hook plate, dynamic muscle transfer, fixation between the clavicle and the coracoid with the use of a coracoclavicular screw [11]. Recent AC joint reconstruction techniques have been modified focusing on anatomic restoration of the coracoclavicular (CC) ligaments, either by use of the auto grafts, synthetic grafts, end Buttons, non-absorbable sutures, suture anchors or the tight rope system [12]. For each of these techniques, benefits, disadvantages, and/or complications have been reported [13]. Therefore, the current study aimed to compare between 2 modalities (Nylon Tape for reconstruction of cc and ac ligaments versus hooked plate) for management of acute AC dislocations to reveal advantages and disadvantages of each modality. The current study was carried out on 60 cases with acute acromioclavicular dislocation; 30 cases were done using nylon tape (group A) & the other 30 cases were done by hooked plate (group B).

The current study showed that there was no statistically significant difference of age and sex between the studied groups with mean age of group A is 34.93 years Versus 33.67 years for group B. All cases in group B versus 93.3% of group A were males. The current study showed no statistically significant difference between group A & B as regard total constant score measured pre and post treatment. But within each group, total score showed statistically significant improvement after operation among group A and B with increasing mean total score from (35.47 to 88.69) after operation for group A and from (37.73 to 86.87) for group B. The current study showed no statistically significant difference between groups A & B as regard ASES score measured pre and post treatment. But within each group, ASES scores showed statistically significant improvement after operation among group A and B with increasing mean ASES score. The current study showed no statistically significant difference between group A & B as regard CC distance measured pre and immediate post-treatment. As regard post-operative complications distribution among groups. four cases of subluxation (partial loss of reduction, 50 % of the preoperative CC distance difference), all occurred in group A (nylon tape) with no further intervention needed. Impingement occurred in six patients in group B (hooked plate) with limitation of range of motion of abduction and forward flexion at 3 months post operative these patients were treated by early removal of plate at 6 months post operative after one year follow up gaining full range of motion four cases with wound infection, two in group A managed by wound dressing and intravenous antibiotics till improvement. Two cases developed Frozen shoulder and were treated by physiotherapy the other two cases in group B needed debridement twice. In agreement with our results, *Khalil et al* performed a prospective randomized study on 30 cases with acute AC injuries, divided into two equal groups: group A underwent AC and CC reconstruction by nylon tape and group B underwent coracoclavicular screw. The results showed that there was a statistically highly significant

*Elwasifi et al., 2023*

improvement (p-value < 0.001) between the pre-operative and one year postoperatively in group A. Regarding functional scores, *Khalil et al* showed that group A showed better one year postoperative Constant and ASES scores however the difference was not statistically significant between both groups (p-value = 0.8 & 0.39 respectively). There was a statistically highly significant improvement (p-value < 0.001) between the pre-operative and one year postoperatively in both groups (nylon tape group and CC screw group), as regard complication post operatively They reported that 2 cases of subluxation in group A (nylon tape) with no further intervention needed and one case in group A. Frozen shoulder and was treated by physiotherapy [14].

Sobhy in 2012 did a prospective case-series study on 17 cases compromised of 11 male patients and 6 female patients, with a mean age of 31 years treated by anatomic reconstruction of the AC ligaments and CC ligaments using nylon tape with a mean follow up period of 28 months. Patients showed statistically significant improvements in the mean VAS score (from 6.4 to 2.4 points), ASES score (from 25.3 to 81.7 points), and Constant score (from 21.2 to 84.9 points). In addition, patients showed statistically significant improvements in ROM scored as part of the Constant score (from 11.5 to 27.4 points) [5]. Sobhy in 2012 reported a major advantage of treating cases with types III to V AC injuries using nylon tape, which has been providing anatomic stabilization of both injury components with a simple technique that can be performed in any operating room without the need for expensive tools. In addition, it carries a low risk of migration, breakage, hardware problems, or clavicular fractures [5]. Gültaç et al conducted their study on a total of 35 consecutive patients who were operated on for AC joint dislocation. Twenty-one patients operated on using the tight rope (TR) technique were categorized as group 1, and 14 patients treated with the hook plate technique formed group 2. Functional results were evaluated using the Constant shoulder scoring system; no statistically significant difference was observed between type 3 and 5 AC separation. The mean Constant scores of type 3 and 5 injuries were 82.96 and 88.6, respectively. A significant relationship was noted between reduction quality and functional scores. A statistically significant difference was found between the two groups in terms of surgery duration (p < 0.05). Also, authors demonstrated that postoperative osteoarthritis was seen in 12 (57.14%) patients in group 1 and 7 (50.00%) patients in group 2 [15]. *Lädemann et al.*, evaluated thirty-seven patients with acute type III to V AC joint disruption underwent open coracoclavicular (CC) and AC stabilization with non absorbable sutures. Evaluation of the DASH and pain score results revealed good overall outcomes. There was no significant difference in clinical score results (Constant, DASH, and VAS pain scores) between patients with Rockwood III, IV, and V injuries. Thirty-two patients were very satisfied, 3 satisfied, and 2 unsatisfied. All patients returned to their previous work and 81% returned to their pre-injury level of sports. Postoperative complications included 1 patient with skin irritation from suture knots that required revision, and another patient who developed a transitory postoperative plexus lesion. The latter patient did not have an interscalene block [13].

**Table 1:** Comparison of demographic characteristics between the studied groups

	<b>Group A n=30</b>	<b>Group B n=30</b>	<b>Test of significance</b>
<b>Age/years Mean ±SD</b>	34.93±12.31	33.67±8.18	t=0.332 p=0.742
<b>Sex</b>	N(%)	N(%)	
<b>Male</b>	28(93.3)	30(100)	FET=1.03
<b>Female</b>	2(6.7)	0	P=1.0

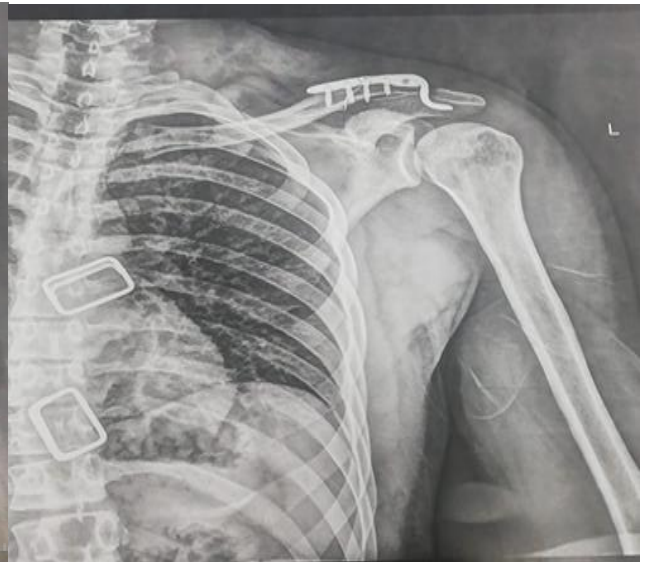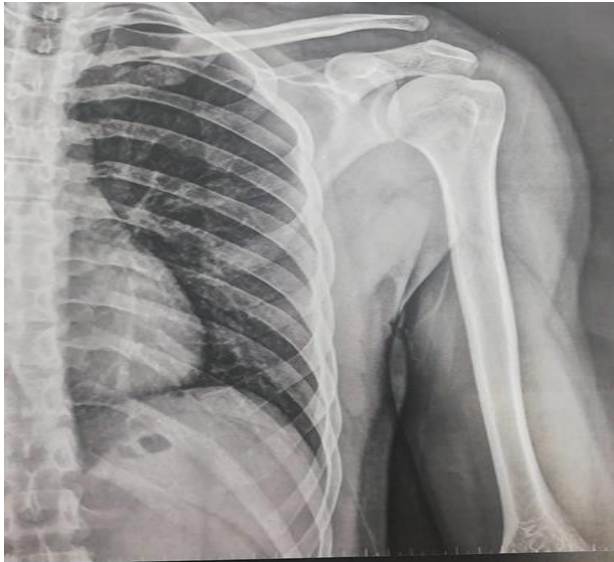t:Student t test FET:Fischer exact test

**Table 2:** Comparison of total constant score and ASES between the studied groups

	<b>total score</b>	<b>Group A n=30</b>	<b>Group B n=30</b>	<b>Test of significance Mann Whitney U test</b>
<b>Constant Score</b>	<b>Pre</b>	35.47±8.94	37.73±9.01	z=1.17 p=0.252
	<b>Post</b>	88.69±7.83	86.87±15.61	z=1.09 p=0.287
	<b>Wilcoxon signed rank test</b>	z=3.18 p=0.001*	z=3.36 p=0.001*	
	<b>% of improvement</b>	150%	130%	
<b>ASES</b>	<b>Pre</b>	30.20±8.38	32.8±5.05	z=1.03 p=0.313
	<b>Post</b>	84.07±25.34	84.80±21.16	z=0.084 p=0.933
	<b>Wilcoxon signed rank test</b>	z=3.24 p=0.001*	z=3.36 p=0.001*	
	<b>% of improvement</b>	178%	158%	

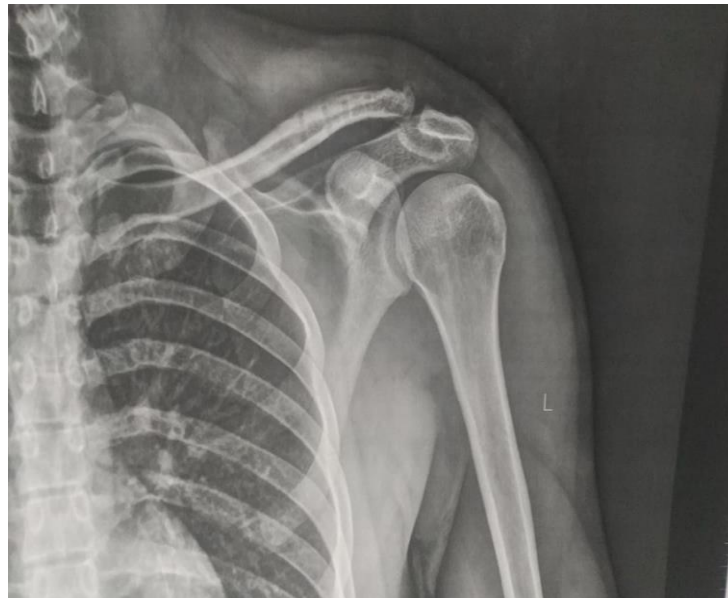**Table 31:** Comparison of CC distance between the studied groups

<b>CC distance</b>	<b>Group A n=30</b>	<b>Group B n=30</b>	<b>Test of significance Mann Whitney U test</b>
<b>Pre</b>	13.80±2.86	10.67±3.04	z=2.91 p=0.007*
<b>Immediate post operative</b>	0.67±0.72	0.33±0.49	z=1.88 p=0.0178
<b>Last</b>	2.27±1.44	2.13±2.42	z=1.67 p=0.107
<b>Friedman test</b>	=26.76 p<0.001*	=28.20 p<0.001*	
<b>% Improvement</b>	%1=93.3 %2=27.9	%1=98.1 %2=95.6	



**Figure 1:** Preoperative x-rays of case 1.

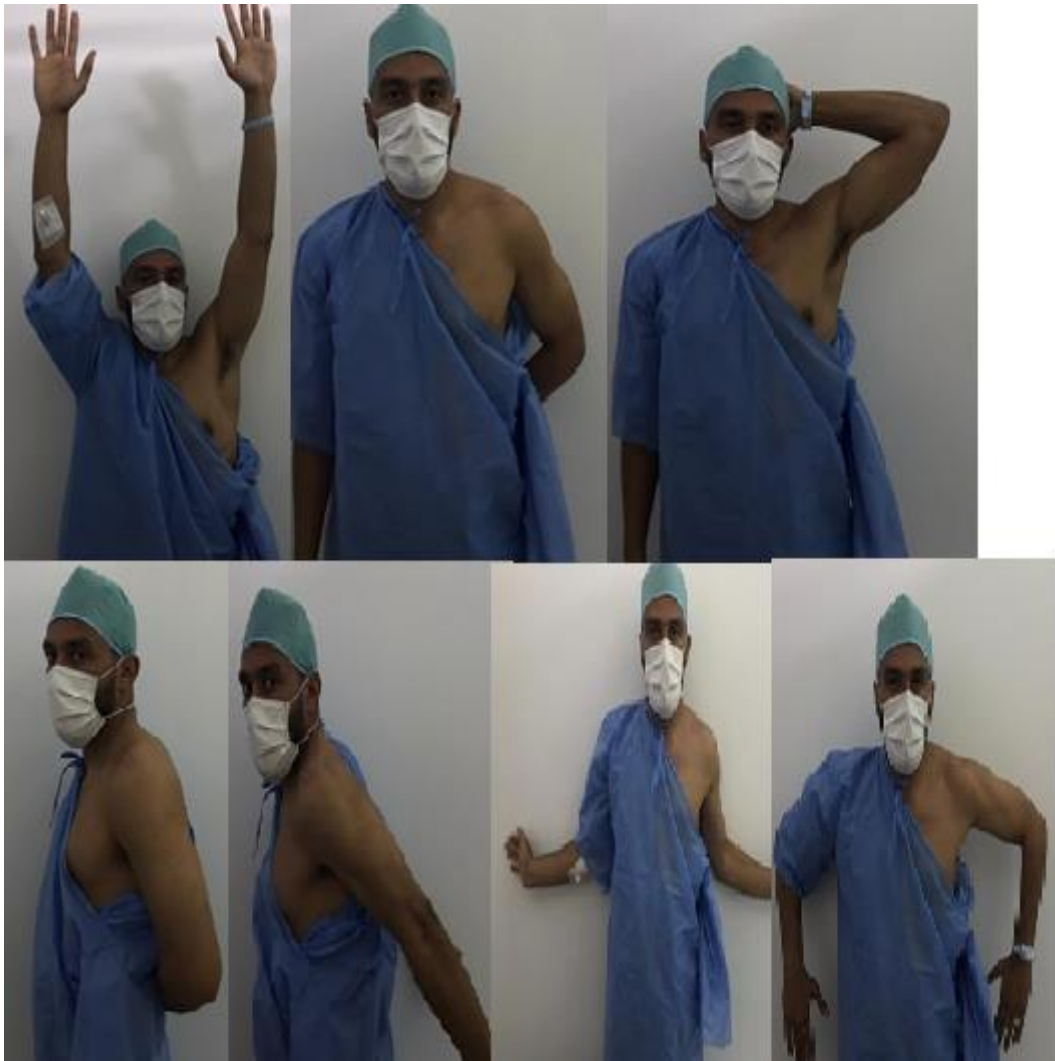**Figure 2:** Immediate postoperative imaging of case 1.



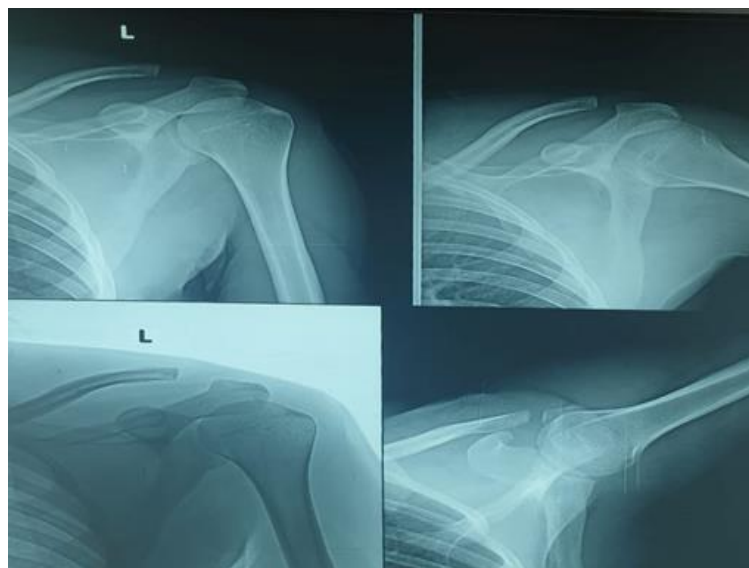**Figure 3:** Last follow up x-ray of case 1.

**Table 4:** Summary of postoperative complications.

postoperative complications	No.	Group	%	P value
No complications	26		76.6%	
Subluxation	4	A	6.7%	0.14
superficial wound infection/ frozen shoulder	2	A	3.3%	0.309
Infection	2	B	3.3%	0.309
Impingement	6	B	10%	0.07

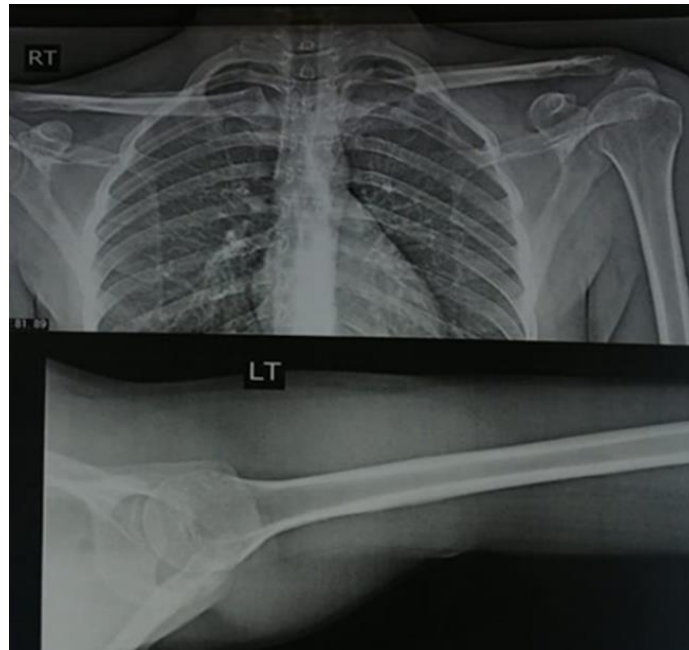


**Figure 4:** Last follow up ROM of case 1.

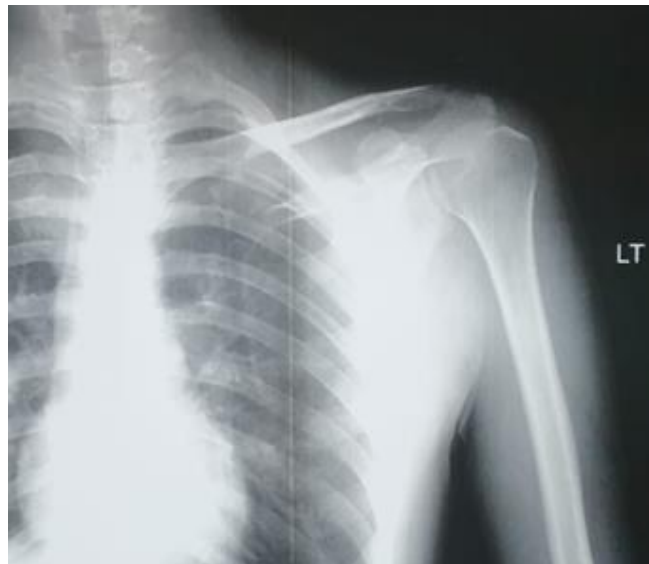


**Figure 5:** Preoperative x-rays of case 2.

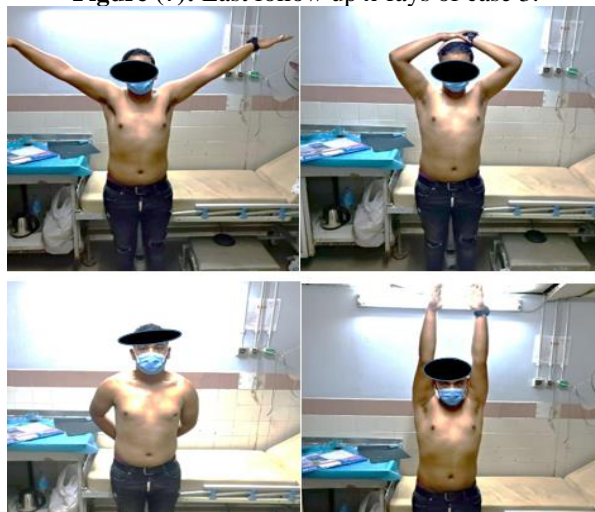



**Figure 6:** Immediate postoperative x-rays of case 2.



**Figure (7):** Last follow up x-rays of case 3.



**Figure 8:** Last follow up ROM of case 3.

The discrepancies in findings of the mentioned studies can be explained by a few factors including degree of AC joint dislocation, the efficacy of the surgical procedure, dissimilar populations, selection of patients and limited sample size. In group A mean preoperative Constant score was 35.47 (+8.94) that improved to 88.69 (+7.83) at one year postoperatively. In group B mean preoperative Constant score was 37.73 ( $\pm 9.01$ ), that improved to 86.87 ( $\pm 15.61$ ) at one year postoperatively. There was a statistically highly significant improvement (p-value < 0.001) between the pre-operative and one year postoperatively in both groups, Group A showed better one-year postoperative Constant score however the difference was not statistically significant between both groups postoperatively (p-value = 0.8). In group A mean preoperative ASES score was 30.20 ( $\pm 8.38$ ) that improved to 84.07 ( $\pm 25.34$ ) at one year postoperatively. In group B mean preoperative ASES score was 32.8 ( $\pm 5.05$ ), that improved to 84.80 ( $\pm 21.16$ ) at one year postoperatively. There was a statistically highly significant improvement (p-value < 0.001) between the pre-operative and one year postoperatively in both groups, Group A showed better one-year postoperative ASES score however the difference was not statistically significant between both groups postoperatively (p-value = 0.39) (Table 2). Regarding radiological evaluation, in group A mean preoperative CC distance difference (mm) was 13.80 that improved to 0.67 immediately post-operative then at the last follow up reaches 2.27. In group B mean preoperative CC distance difference (mm) was 10.67, that improved to 0.33 immediately post-operative then at the last follow up reaches 2.13. There was a statistically highly significant improvement (p-value < 0.001) between the pre-operative and one year postoperatively in both groups, Group B showed better one-year postoperative CC distance difference (mm) however the difference was not statistically significant between both groups postoperatively (p-value = 0.86) (table 3). Regarding Complications, four cases had subluxation, and this occurred in group A (nylon tape) with no further intervention needed. Impingement occurred in six patients in group B (hooked plate) with limitation of range of motion of abduction and forward flexion at 3 months post operative these patients were treated by early removal of plate at 6 months post operative. After one year follow up, they gained full range of motion. four cases with wound infection, two in group A managed by wound dressing and intravenous antibiotics till improvement, they developed Frozen shoulder occurred in these cases and were treated by physiotherapy. The other cases in group B needed debridement twice (Table 4).

#### 4. Conclusions

This study added evidence of an attractive alternative in stabilization of acute AC joint dislocations. Both AC and CC reconstruction by nylon tape showed good to excellent results without the need for implant removal and without complications linked to implants and graft source morbidity. Minimally invasive methods that may improve clinical outcome remain to be evaluated in future studies.

#### References

- [1] H.S. Elgohary, N.M. Selim. (2014). Mini-open approach for stabilization of acute complete acromioclavicular dislocation. The Egyptian Orthopaedic Journal. 49(4): 320-325.
- [2] J. Fraser-Moodie, N. Shortt, C. Robinson. (2008). Injuries to the acromioclavicular joint. The Journal of Bone & Joint Surgery British Volume. 90(6): 697-707.
- [3] L. Weiser, J.V. Nüchtern, K. Sellenschloh, K. Püschel, M.M. Morlock, J.M. Rueger, M. Hoffmann, W. Lehmann, L.G. Großterlinden. (2017). Acromioclavicular joint dislocations: coracoclavicular reconstruction with and without additional direct acromioclavicular repair. Knee Surgery, Sports Traumatology, Arthroscopy. 25: 2025-2031.
- [4] D. Tiren, A.J. van Bommel, D.J. Swank, F.M. van der Linden. (2012). Hook plate fixation of acute displaced lateral clavicle fractures: mid-term results and a brief literature overview. Journal of orthopaedic surgery and research. 7: 1-8.
- [5] M.H. Sobhy. (2012). Midterm results of combined acromioclavicular and coracoclavicular reconstruction using nylon tape. Arthroscopy: The Journal of Arthroscopic & Related Surgery. 28(8): 1050-1057.
- [6] R.I. Harris, A.L. Wallace, G.D. Harper, J.A. Goldberg, D.H. Sonnabend, W.R. Walsh. (2000). Structural properties of the intact and the reconstructed coracoclavicular ligament complex. The American journal of sports medicine. 28(1): 103-108.
- [7] R.M. Frank, E.J. Cotter, T.S. Leroux, A.A. Romeo. (2019). Acromioclavicular joint injuries: evidence-based treatment. JAAOS-Journal of the American Academy of Orthopaedic Surgeons. 27(17): e775-e788.
- [8] D.E. Kramer, T. Wusu. (2019). Footballer's Shoulder. Upper Extremity Injuries in Young Athletes. 7-20.
- [9] C.A. Rockwood. (1990). Disorders of the acromioclavicular joint. The shoulder. 413-476.
- [10] R.J. Warth, F. Martetschläger, T.R. Gaskill, P.J. Millett. (2013). Acromioclavicular joint separations. Current reviews in musculoskeletal medicine. 6: 71-78.
- [11] G. Moatshe, B.M. Kruckeberg, J. Chahla, J.A. Godin, M.E. Cinque, M.T. Provencher, R.F. LaPrade. (2018). Acromioclavicular and coracoclavicular ligament reconstruction for acromioclavicular joint instability: a systematic review of clinical and radiographic outcomes. Arthroscopy: The Journal of Arthroscopic & Related Surgery. 34(6): 1979-1995. e8.
- [12] Z. Hou, J. Graham, Y. Zhang, K. Strohecker, D. Feldmann, T.R. Bowen, W. Chen, W. Smith. (2014). Comparison of single and two-tunnel techniques during open treatment of acromioclavicular joint disruption. BMC surgery. 14(1): 1-7.
- [13] A. Lädermann, M. Grosclaude, A. Lübbecke, P. Christofilopoulos, R. Stern, T. Rod, P. Hoffmeyer. (2011). Acromioclavicular and coracoclavicular cerclage reconstruction for acute acromioclavicular joint dislocations. Journal of Shoulder and Elbow Surgery. 20(3): 401-408.
- [14] T.M. Khalil, A. Elsoud, M.M. Samy, W.A.M. Nassar, M.H. Sobhy, A.M. El Seddawy, A.E.M. Khaled. (2020). Acromioclavicular and coracoclavicular reconstruction by nylon tape versus coracoclavicular screw in management of acute acromioclavicular dislocation. Ain Shams Medical Journal. 71(1): 89-99.
- [15] E. Gültaş, F.İ. Can, C.Y. Kılınç, H. Aydoğmuş, F.E. Topsakal, A.E. Açıkan, N.H. Aydoğan. (2022).



Comparison of the radiological and functional results of tight rope and clavicular hook plate technique in the treatment of acute acromioclavicular joint dislocation. *Journal of Investigative Surgery.* 35(3): 693-696.