

# Aortic valve neocuspidization “ozaki procedure” in small aortic annulus: early short-term mansoura university experience

Mohamed Ahmed Gabr<sup>1</sup>, Usama Ali Hamza<sup>1</sup>, Sameh Mostafa Amer<sup>1\*</sup>

Mohammed Sanad,<sup>1</sup>

<sup>1</sup> Faculty of Medicine, Mansoura University, Mansoura, Egypt.

## Abstract

Small aortic annulus (SAA) in the context of an aortic valve replacement (AVR) represents a major challenge to the cardiac surgeon and carries high risk for the patient. The aortic valve neocuspidization (AVNeo) has emerged as an innovative solution in the surgical armamentarium for SAA with promising outcomes. The aim of this study was to assess the feasibility, safety and the short-term outcomes of the AVNeo in setting of SAA. From October 2021, AVNeo was performed for 19 patients with different aortic valve pathologies, of them 6 patients (31.6%) had a SAA with mean echocardiographic aortic annular diameter of  $19.17 \pm 1.16$  mm with mean indexed aortic valve area (AVA<sub>i</sub>) of  $0.55 \pm 0.50$  cm<sup>2</sup>, mean gradient of  $61 \pm 31$  mmHg and left ventricular mass index (LVMI) of  $140.07 \pm 52.62$  g/m<sup>2</sup>. Patients were operated on, data collected and recorded prospectively then retrospectively retrieved and analyzed. The majority of patients were females (83.3%) mean age of  $50.50 \pm 14.29$  years, 66.7% had aortic stenosis (AS) with 66.7% of rheumatic etiology. Bicuspid aortic valves (BAV) constituted 50%. Only treated autologous pericardium was used for neo-leaflets reconstruction following the Ozaki's protocol. Postoperative clinical and echocardiography follow up was done at discharge, 1 month, 3 months, 6 months, 12 months and then annually. There was no operative conversion from AVNeo to SAVR and no aortic root enlargement (ARE) technique was done. After meticulous annular decalcification, mean surgical aortic annular diameter was of  $18.50 \pm 0.54$  mm. Neo-commissures created in 50% of patients. Mean aortic cross clamp and bypass times were  $110 \pm 14$  minutes and  $139 \pm 9$  minutes, respectively, no operative mortality, no permanent pacemaker implantation (PPI). There was immediate intraoperative improvement in mean and peak gradients, AVA and AVA<sub>i</sub> ( $1.38 \pm 0.16$  cm<sup>2</sup>/m<sup>2</sup>) without PPM. At mean follow up of  $14.75 \pm 7.44$  months (longest 23 months), there were stable pressure gradients, AVA, no occurrence of PPM, 100% survival, 100% freedom from sever AR and 100% freedom from reoperation with significant reduction in LVMI to g/m<sup>2</sup>. AVNeo is safe, feasible and reproducible procedure with excellent hemodynamic results in the context of SAA and it should be considered in the arsenal of solutions for SAA. Nevertheless, long-term follow up and multi-center randomized trials are needed for final verification.

**Keywords:** AVNeo, Aortic root enlargement, Small aortic annulus, Aortic stenosis, LV mass.

**Full length article** \*Corresponding Author, e-mail: [dr.mogabr@mans.edu.eg](mailto:dr.mogabr@mans.edu.eg).

## 1. Introduction

### 1.1 Background

The definition of a “surgically” small aortic annulus (SAA) is that an aortic annulus that can't accommodate an aortic prosthesis  $>21$  mm [1-3] and the percentage of patients who underwent surgical aortic valve replacement (SAVR) and received an aortic prosthesis  $\leq 21$  mm ranges from 22-44% in united states and Northern Europe [4-6]. Patients with SAA represent a major challenge to the cardiac surgeons [3, 6]; due to the high surgical risk and the increased perioperative morbidity and mortality [7] due to the occurrence of PPM with the resultant residual high transaortic pressure gradients [8] with its imposed left ventricular (LV) negative impacts [9, 10] and reduced long-term survival [11].

Over the time, cardiac surgeons worked on this problem and now there's a large armamentarium for mitigating this problem [1] including aortic root enlargement (ARE) techniques [12-14], stentless valves, sutureless valves [6, 15], newer generation-mechanical valves with improved hemodynamic performance [16] and transcatheter AVR (TAVR) [17]. AVNeo that entails the independent reconstruction of the AV leaflets by Glutaraldehyde treated autologous pericardium, developed by Professor Ozaki in 2007 showed very promising results since its application [18]. The AVNeo resulted in excellent hemodynamic outcomes in form of low pressure gradients, large effective orifice area with no or very low incidence of PPM, no occurrence of heart block, low peri-procedural

morbidity and mortality [19-27]. Moreover, the AVNeo due to the lack of an annular fixing ring, unlike the prosthetic valves, it maintains the normal aortic annular dynamism and deformation throughout the cardiac cycle [28, 29], resulting in laminar flow across the valve similar to the normal valves [30-32]. This property is of paramount importance in SAA patients with invaluable imposed left ventricular effects in terms of accelerated LV reverse remodeling evident from reduction in the LVMI [33]. Due to all of these outcomes, AVNeo is considered a new tool in the box for SAA [23, 27].

## 2. Methods

### 2.1 Study design

This study was a prospective study started from October, 2021, carried out in the Cardiothoracic Surgery Department – Cardiothoracic and Vascular Surgery Center (CVSC) – Mansoura University. We obtained the approval of the Mansoura Faculty of Medicine-Institutional Research Board (MFM-IRB) (Code Number: MD.21.09.529) and a written informed consent was obtained from patients. Data was collected and recorded prospectively and retrospectively analyzed.

### 2.2 Patients` characteristics

During the study period, 19 patients underwent AVNeo, from them 6 patients had SAA. The baseline characteristics of this group of patients are shown in table 1. The mean echocardiographic annular diameter was of  $19.17 \pm 1.16$  mm. The majority of patients were females (83.3%), mean age of  $50.50 \pm 14.29$  years and body surface area (BSA) of  $1.7 \pm 17m^2$ . The most prevalent indication for AVNeo was sever aortic stenosis (AS) (66.7%) with rheumatic pathology the commonest (66.7%). Preoperative echocardiographic data shown in table 2. Bicuspid aortic valve (BAV) represented 50%, the mean AVA and AVAi were of  $0.95 \pm 0.78$  cm<sup>2</sup> and  $0.55 \pm 0.50$  cm<sup>2</sup>/m<sup>2</sup>, respectively with the mean transaortic peak and mean gradients were  $99 \pm 49$  and  $61 \pm 31$  mmHg, respectively. The baseline mean LV mass (LVM) and LVMI were of  $240.22 \pm 93.99$  g and  $140.07 \pm 52.62$  g/m<sup>2</sup>, respectively, reflecting the severity of LV remodeling due to severity of the AV disease.

### 2.3 Surgical technique (fig. 1)

We meticulously followed the precise protocol described by Ozaki [20, 34]. After a standard median sternotomy, a sufficient area of autologous pericardium (at least  $7 \times 8$  cm) was resected carefully after removal of all growth fat, then stretched over a special metal tray and another attempt of careful removal and excision of all fatty tissue and fibers over the pericardium removed carefully. After that, the stretched piece of the autologous pericardium is immersed within a 100 mL of 0.6% Glutaraldehyde solution in a specific tray for 10 minutes for fixation, followed by the rinsing within a physiological (0.9%) Saline solution three times each one for 6 minutes. During this process, the routine setup for the cardiopulmonary bypass (CPB) was being performed. Before aortic cross clamping, we marked the aortotomy site by a sterile surgical skin marker at a distance of 1.5 cm above the right coronary artery ostium, then aortic cross clamping (ACC) done and Custodiol® (Bretschneider HTK, Bensheim, Germany) cardioplegic solution administered in an antegrade manner

in the root in cases of AS, whereas in cases with non-holding AV, we performed aortotomy followed by direct intra-coronary cardioplegia administration and the LV was vented through a right superior pulmonary vein vent catheter. After transverse aortotomy, retraction sutures were placed for facilitation of valve exposure, complete valve excision and careful, meticulous annular decalcification done. We used the standard Ozaki sizers for sizing the neo leaflets by sizing the inter-commissural distance as described by Ozaki [20] and in cases of BAV, we achieved tricuspidization through the creation of a neo-commissure. The neo leaflets were drawn on the smooth side of the pericardium (by a sterile surgical marker) according to the corresponding window in the plastic template, followed by cutting the leaflets by scissors. The next step was suturing the individual leaflet to the native aortic annulus following the Ozaki sequence (Right, Left, Non-coronary), we started suturing at the leaflet`s nadir`s midpoint with the smooth side towards the left ventricular outflow tract (LVOT) and the rough side towards the aorta, suturing was continued upwards towards the commissure (using polypropylene suture 4/0 13 mm needle). Then, each commissure joining contiguous leaflets was secured to the aortic wall through fixing the 2 adjacent leaflets` wing extensions to  $5 \times 10$ -mm pledgets on the aortic wall externally. The final step was visual inspection of the neo-valve to ensure symmetrical same-level tri-leaflet coaptation under negative pressure made by the LV vent. Aortotomy was closed through a single layer- polypropylene suture followed by deairing and standard weaning off CPB, standard TEE examination was performed by our anesthesiologists for assessment of the neo-valve function (fig. 2).

### 2.4 Follow up

Professor Ozaki recommended only Aspirin 100 mg/day for 6 months after the operation and discontinued after that, unless needed and Warfarin was used in patients with an indication for its use. Patients were followed up clinically at the outpatient clinic (OPC) in the CVSC – Mansoura University at 2 weeks, 1 months, 3 months, 6 months and 12 months PO. Echocardiography done at regular intervals at 1 months, 3 months, 6 months and 12 months then annually.

### 2.5 Statistical analysis

Was performed using Statistical Package for the Social Sciences (SPSS) statistical software version 27 (SPSS, Inc, Chicago, IL, USA). Continuous variables are presented as mean  $\pm$  standard deviation (SD). Categorical data are presented as n (%). The differences between the pre-operative and post-operative data values were evaluated by Paired T-Test. P values  $< 0.05$  were considered to indicate a statistically significant difference.

## 3. Results and Discussion

### 3.1 Intraoperative data (table 3)

There was no operative conversion from AVNeo to SAVR and only autologous pericardium was used. The mean surgical aortic annular diameter was of  $18.50 \pm 0.54$  mm, equal three cusps` sizes was achieved in 66.7% of cases and neo-commissures created in 50% of the patients. The mean ACC and CPB times were of  $110 \pm 14$  minutes and  $139 \pm 9$  minutes, respectively. There were no need for

temporary pacemaker or permanent pacemaker insertion and no operative mortality occurred. Post-CPB TEE examination revealed immediate improvement in all aortic valve indices and AVA without any degree of PPM (defined as AVAi of  $\leq 0.85 \text{ cm}^2/\text{m}^2$  according to [9]) (table 4).

### 3.2 Postoperative data (table 5)

There was no postoperative mortality and morbidity (table 5) was in the form of right sided hemopneumothorax in one patient that mandated inter-costal tube insertion that lasted for three days and one patient developed postoperative atrial fibrillation (AF) that was pharmacologically controlled by Amiodarone and required anticoagulation by Warfarin, the need for PPI was 0%. mean duration of intensive care unit (ICU) and hospital stay were of  $3 \pm 1.26$  and  $5.53 \pm 1.32$  days, respectively, with no mortality. When comparing the baseline and on-discharge AV indices (table 6 and fig. 3 and 4), there was a statistically significant improvement in the AVA, AVAi, MPG, PPG and  $V_{max}$ .

### 3.3 Clinical and Echocardiographic follow up

At a mean follow up duration of  $14.75 \pm 7.44$  months (minimum 0.25 and maximum of 23 months) with the least follow up of 6 months after the last patient, we found 100% survival, 100% freedom from sever AR and 100% freedom from reoperation. When comparing the baseline and last-follow up AV indices (table 7), there was a statistically significant increase in the mean AVA from  $0.95 \pm 0.78 \text{ cm}^2$  to  $2.29 \pm 0.16 \text{ cm}^2$  ( $P = 0.005$ ) and AVAi from  $0.55 \pm 0.50 \text{ cm}^2/\text{m}^2$  to  $1.33 \pm 0.66 \text{ cm}^2/\text{m}^2$  ( $P = 0.006$ ) and statistically significant reduction in the transaortic pressure gradients and maximum transaortic velocity; MPG decreased from  $99 \pm 49 \text{ mmHg}$  to  $7.16 \pm 1.7 \text{ mmHg}$  ( $P = 0.008$ ), PPG decreased from  $61 \pm 31 \text{ mmHg}$  to  $13.50 \pm 3.3 \text{ mmHg}$  ( $P = 0.007$ ) and the  $V_{max}$  decreased from  $4.27 \pm 2 \text{ m/s}$  to  $1.18 \pm 0.98 \text{ m/s}$  ( $P = 0.014$ ) and none of our patients at latest follow up had more than a trivial AR. As regard to the LV effects of AVNeo, the mean LVM and LVMI also had a statistically significant reduction from the baseline values; the LVM decreased by  $90.47 \pm 71.87 \text{ g}$  ( $P = 0.027$ ) and the LVMI decreased by  $53.80 \pm 41.40 \text{ g/m}^2$  ( $P = 0.24$ ) (table 8). The principal findings in our study are the excellent hemodynamic performance of AVNeo in the setting of SAA with no PPM, the safety profile of the procedure with very low operative and postoperative morbidity and mortality and the excellent LV outcomes. Patients with small aortic annuli are at higher probability to receive too small prosthetic valve in relation to their BSA during AVR [35, 36], the result is the serious problem of prosthesis-patient mismatch (PPM) [9, 37], PPM is linked to high postoperative morbidity and mortality [38] with deleterious outcomes in the form of less LV mass regression, high incidence of HF, high incidence of PPI, recurrent hospitalization, high long-term mortality and low survival [4, 39].

The prediction of PPM before the AVR is important for planning of the solution to mitigate such a problem, the traditional ways to solve the problem of predicted PPM included the aortic root enlargement (ARE) procedures [40], supra-annular bioprosthesis [41], stentless bioprosthesis [42], sutureless valves [6, 15] and TAVR was applied in the setting of SAA [43, 44]. In a large meta-analysis by Sá, *et al.*, [45] included 13174 patients between

2002 and 2016, the authors found that patients who had a combined AVR and ARE had higher risk of perioperative morbidity and mortality when compared to an AVR alone, but the addition of ARE resulted in higher AVAi and less PPM. However, in the retrospective study of Haunschild *et al.*, [46] and Yu *et al.*, [47] they concluded that AVR and ARE is a safe procedure and doesn't carry higher risk of perioperative morbidity and mortality when compared to AVR only, moreover, the ARE had larger AVAi with less PPM. The stentless valves due to the lack of the rigid sewing ring offered larger AVAi in SAA patients with no PPM due to the preservation of the annular dynamics with the imposed LV effects [1, 48]. Sutureless valves achieved breakthrough development in aortic bioprosthesis, their implantation in SAA was recommended by international experts [49] due to their excellent outcomes in this category of patients due to the lack of the sewing ring.

The AVNeo developed by Ozaki is an innovative and creative tool for mitigating the SAA, the independent leaflet reconstruction without any rings or stents leads to preservation of the inherent dynamism of the aortic annulus, offers a large AVA and AVAi and translates into excellent hydrodynamics across the LVOT and AV [31, 32]. In the study of Akiyama *et al.*, [27] that included 34 Japanese patients with sever AS and SAA between 2011 and 2017, the mean annular diameter was  $18.4 \pm 1.1 \text{ mm}$  with AVAi of  $0.45 \pm 0.14 \text{ cm}^2/\text{m}^2$ , following AVNeo, the authors reported significant increase in the AVAi to  $1.02 \pm 0.26 \text{ cm}^2/\text{m}^2$  at one week with mean gradient of  $11.7 \pm 6.0 \text{ mmHg}$  and at mid-term follow up, the AVAi and mean gradient were of  $1.18 \pm 0.35 \text{ cm}^2/\text{m}^2$  and  $9.3 \pm 5.4 \text{ mmHg}$ , respectively.

Sá, *et al.*, [23], in their multicenter study that included 106 patients with SAA from three centers between 2017 and 2019, the mean annular diameter was of  $19.8 \pm 1.1 \text{ mm}$  with 97.2% has AS, mean AVAi and mean gradient of  $0.4 \pm 0.2 \text{ cm}^2/\text{m}^2$  and  $46.0 \pm 12.2 \text{ mmHg}$ , respectively. The postoperative mean AVAi of and mean gradient of  $1.3 \pm 0.3 \text{ cm}^2/\text{m}^2$  and  $7.3 \pm 3.5 \text{ mmHg}$ , respectively and the authors didn't observe ant PPM in their patients with no patient suffered sever AR. The merit of the AVNeo in the setting of SAA is the maintained annular motion. Secinaro and his colleagues [32] evaluated the hemodynamics of the aortic root and ascending aorta by cardiac four-dimensional (4D) magnetic resonance imaging (MRI) following AVNeo and compared them with the Ross procedure in 20 patients (10 AVNeo versus 10 Ross). The authors found normal central blood flow in both groups with no difference in the wall shear stress between both groups with a slight increased maximum velocity in the AVNeo group due to the smaller AVAi in them.

**Table: 1 Baseline Characteristics of Patients (n=6)**

Variable	Count	Mean	Standard Deviation	Minimum	Maximum
Age		50.50	14.29	23	62
Sex	Male	1 (16.7%)			
	Female	5 (83.3%)			
Indication For Surgery	Sever AS	4 (66.7%)			
	Sever AR	1 (16.3%)			
	Sever ASR	1 (16.3%)			
Pathology	Rheumatic	4 (66.7%)			
	Degenerative	2 (33.3%)			
NYHA Class	NYHA Class I	0 (0%)			
	NYHA Class II	2 (33.3%)			
	NYHA Class III	4 (66.7%)			
	NYHA Class IV	0 (0%)			
Comorbidities	AF	0 (0%)			
	CKD	1 (16.3%)			
	COPD	0 (0%)			
	DM	1 (16.3%)			
	Hypertension	1 (16.3%)			
	IHD	0 (0%)			
	Smoker	1 (16.3%)			
EUROSCORE II		0.88	0.17	0.67	1.19

AS: aortic stenosis, AR: aortic regurgitation, ASR: aortic steno-regurgitation, NYHA: New York Heart Association, AF: atrial fibrillation, CKD: chronic kidney disease, COPD: chronic obstructive pulmonary disease, DM: diabetes Miletus, IHD: ischemic heart disease.

**Table: 2 Baseline Echocardiographic Data of Patients (n=6)**

Variable	Count	Mean	Standard Deviation	Minimum	Maximum	
AV Type	TAV	3 (50%)				
	BAV	3 (50%)				
Aortic Diameters (mm)	Annulus		19.17	1.16	18	21
	SoV		29.83	5.74	24	38
	STJ		26.67	1.75	24	28
	Ascending		31.67	5.20	25	40
AVA (cm <sup>2</sup> )		0.95	0.78	0.40	2.50	
AVAi (cm <sup>2</sup> /m <sup>2</sup> )		0.555	0.500	0.240	1.560	
PPG (mmHg)		99	49	22	166	
MPG (mmHg)		61	31	11	99	
Vmax (m/s)		4.27	2.00	1.00	6.40	
EF %		60.83	11.30	40	72	
FS %		30.50	6.53	20	37	
EDD (mm)		48.67	11.41	34	60	
ESD (mm)		33.00	10.11	21	48	
IVS Thickness (mm)		13.00	2.28	13	15	
PWT (mm)		11.83	1.94	9	14	
LV Mass (LVM) (g)		240.22	93.99	138.77	387.87	
LV Mass Index (LVMI) (g/m <sup>2</sup> )		140.07	52.62	77.09	228.16	

TAV: tricuspid aortic valve, BAV: bicuspid aortic valve, SoV: sinus of Valsalva, STJ: sinotubular junction, AVA: aortic valve area, AVAi: indexed aortic valve area, PPG: peak pressure gradient, MPG: mean pressure gradient, V<sub>max</sub>: maximum velocity, EF: ejection fraction, FS: fractional shortening, ESD: end systolic dimension, EDD: end diastolic dimension, IVS: interventricular septal thickness, PWT: posterior wall thickness, LVM: left ventricular mass, LVMI: left ventricular mass index.

**Table: 3 Operative Data of Patients (n=6)**

Variable	Count	Mean	Standard Deviation	Minimum	Maximum
Annular Decalcification	No	1 (16.7%)			
	Mild	2 (33.3%)			
	Extensive	3 (50%)			
Surgical Annular Diameter by SJM <sup>®</sup> Mechanical Valve Sizer (mm)	6 (31.6%)	18.50	0.548	18	21
Neo-valve cusps sizes:					
RCC Size (mm)		24.00	2.09	21	27
LCC Size (mm)		24.00	2.09	21	27
NCC Size (mm)		23.67	1.63	21	25
Equal Three Cusp Sizes (Cusp Symmetry)	4 (66.7%)				
Neo-commissure Creation	3 (50%)				
Aortic Cross Clamping Time (ACCT) (minutes)		110	14	95	130
Cardiopulmonary Bypass Time (CPBT) (minutes)		139	9	130	150
Need for Temporary Pacemaker	0 (0%)				
Permanent Pacemaker Implantation	0 (0%)				
Mortality	0 (0%)				

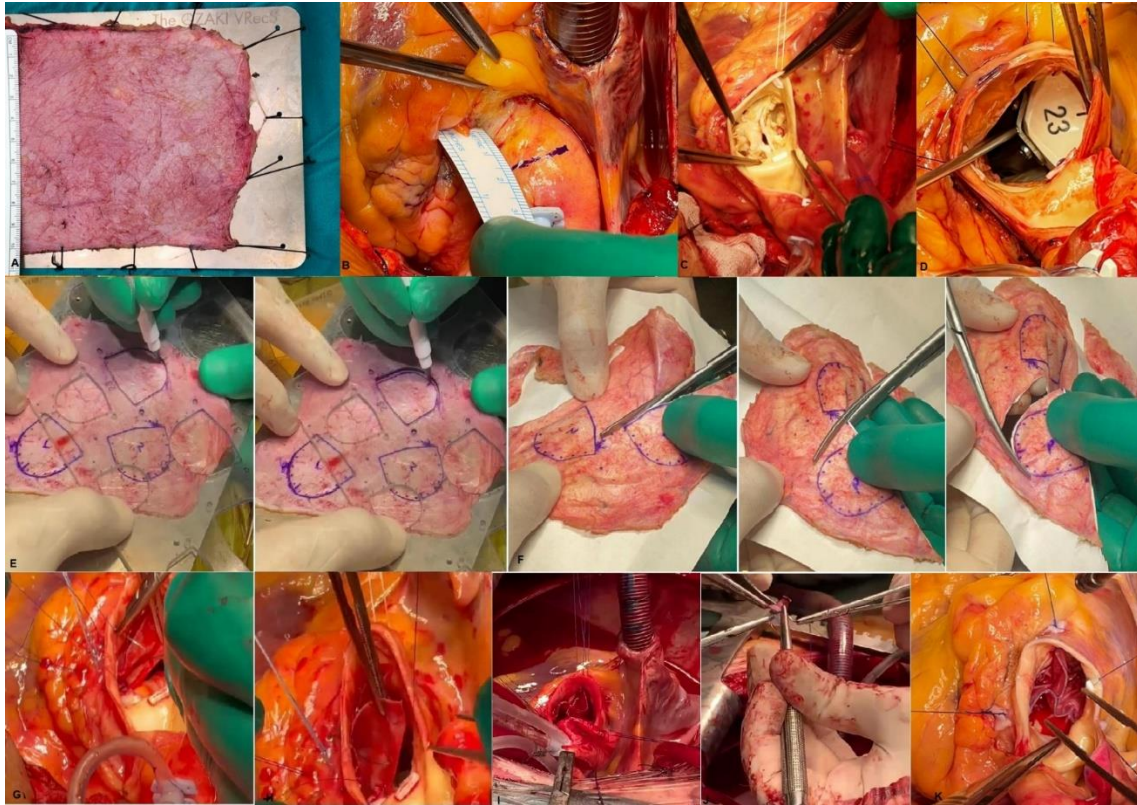
RCC: right coronary cusp, LCC: left coronary cusp, NCC: non-coronary cusp.

**Table: 4 Post-CPB Echocardiography Data of Patients (n=6)**

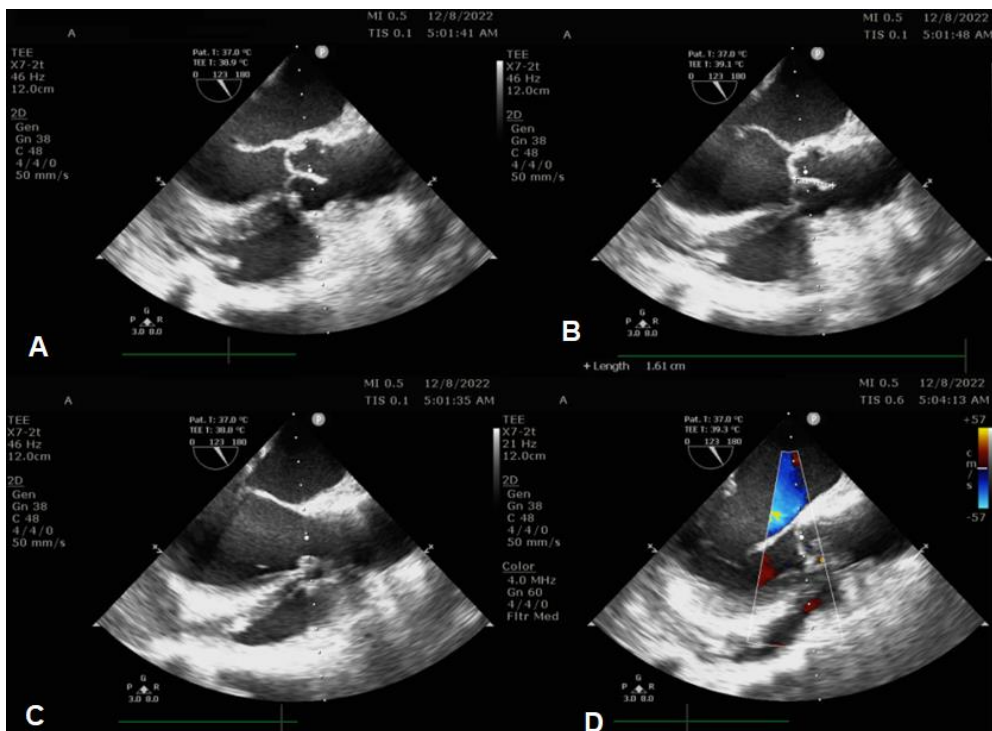
Variable	Count	Mean	Standard Deviation	Minimum	Maximum
AVA (cm <sup>2</sup> )		2.28	0.24	2.00	2.50
AVAi (cm <sup>2</sup> /m <sup>2</sup> )		1.38	0.16	1.11	1.56
Patient-Prosthesis Mismatch (PPM)	0 (0%)				
PPG (mmHg)		15.33	3.93	9.00	20.0
MPG (mmHg)		7.50	2.42	3.00	10.0
V <sub>max</sub> (m/s)		1.40	0.14	1.20	1.60
Coaptation Height (mm)		13.76	1.21	13	16
Effective Height (mm)		18.17	1.32	16	20
Degree of AR	None	6 (100%)			
EF %		66.33	8.50	57	80
FS %		30.50	6.56	20	38
ESD (mm)		31.33	6.26	23	40
EDD (mm)		47.00	9.44	35	59

CPB: cardiopulmonary bypass, AVA: aortic valve area, AVAi: indexed aortic valve area, PPG: peak pressure gradient, MPG: mean pressure gradient, V<sub>max</sub>: maximum velocity, EF: ejection fraction, FS: fractional shortening, ESD: end systolic dimension, EDD: end diastolic dimension.

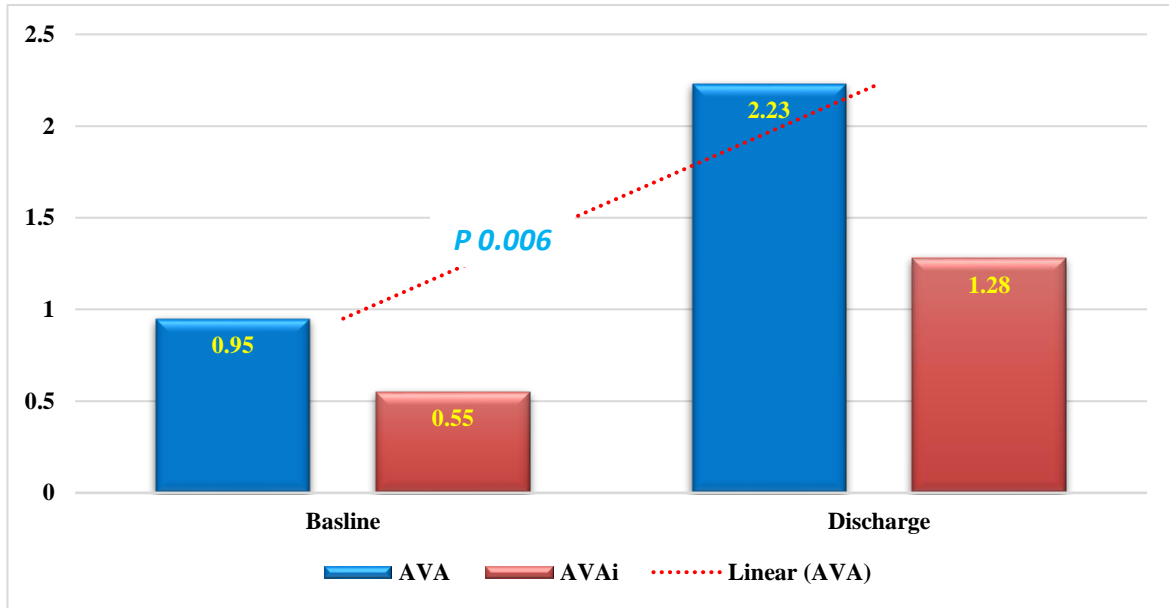




**Figure 1:** The surgical technique of AVNeo: A: the stretched pericardium, B: Aortotomy site marking, C: traction sutures exposing the AV, D: sizing the inter-commissural distance, E: drawing of the leaflets, F: trimming of the neo-leaflets, G, H suturing of the leaflet, I: Fixing the commissures and K: the final view of the neo-valve.



**Figure 2:** Post-CPB TEE assessment of the neo-valve: A: 2D-long axis view in diastole, B: the coaptation height (16 mm), C: 2D-long axis view in systole and D: color Doppler long axis view.



**Figure 3:** Clustered column chart showing the difference between the mean of aortic valve area and indexed AVA at baseline and on discharge ( $p$  0.006 and 0.007, respectively).

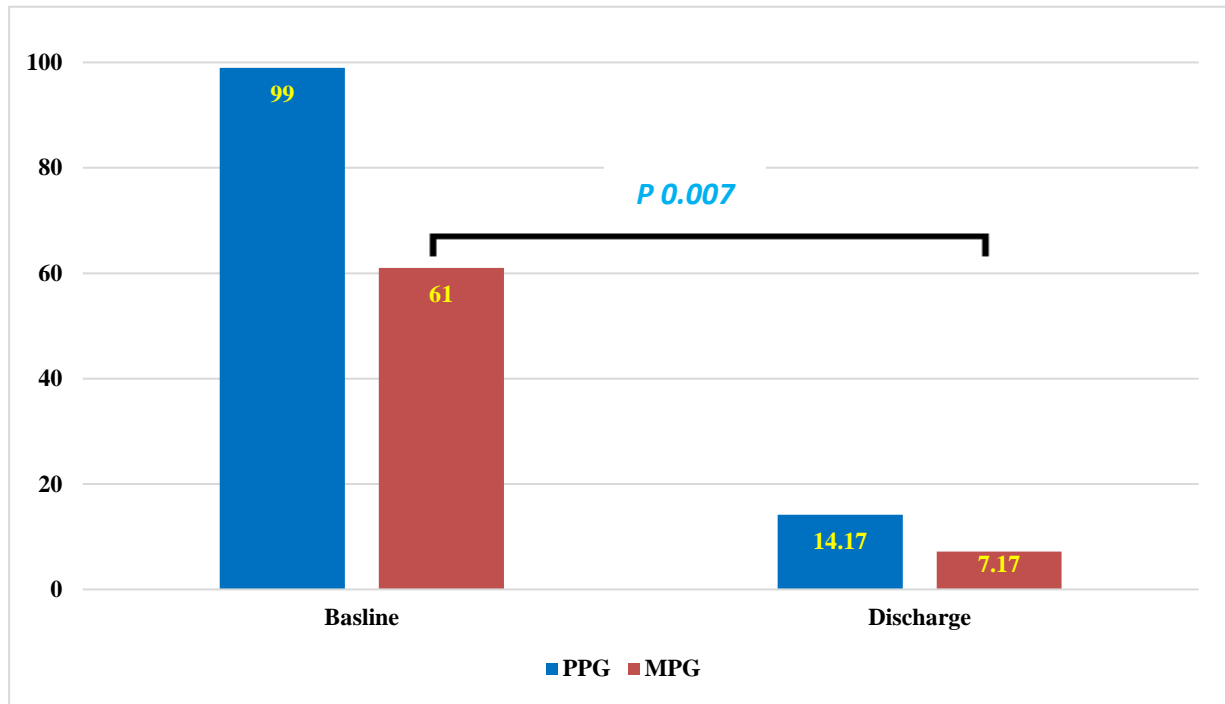
**Table: 5 Post-operative Data of Patients (n=6)**

Variable	Count	Mean	Standard Deviation	Minimum	Maximum
Mechanical Ventilation Duration (hours)		4.17	1.94	2	7
Pulmonary Complications	None	5 (83.3%)			
	Pleural Effusion	0 (0%)			
	Hemo-pneumothorax	1 (16.7%)			
Atrial fibrillation (AF)	1 (16.7%)				
Need For Temporary Cardiac Pacing	0 (0%)				
Permanent Pacemaker Implantation (PPI)	0 (0%)				
Cerebrovascular Stroke	0 (0%)				
Infective Endocarditis (IE)	0 (0%)				
Deep Sternal Wound Infection (DSWI)	0 (0%)				
Sepsis	0 (0%)				
Acute Kidney Injury (AKI)	0 (0%)				
Cumulative Bleeding Amount (mL)		466.67	186.19	200	700
Reoperation For Bleeding	0 (0%)				
Duration of ICU Stay (days)		3.00	1.26	1	5
Duration of Hospital Stay (days)		5.53	1.32	4	7
Mortality	0 (0%)				

**Table: 6 Comparison of The Baseline and Discharge ECHO AV Indices:**

Variable	Baseline Mean (SD)	Discharge Mean (SD)	Mean Difference	95% Confidence Difference Lower	Interval of the Upper	P (2-tailed)
AVA	0.95 (0.78)	2.23 (0.22)	1.28	0.570	1.99	.006
AVAi	0.55 (0.50)	1.28 (0.17)	0.72	0.305	1.15	.007
PPG	99 (49)	14.17 (3.54)	85	35.16	134.83	.007
MPG	61 (31)	7.17 (1.72)	53.83	22.55	85.11	.007
$V_{max}$	4.27 (2.0)	1.40 (0.14)	2.86	0.715	5.01	.019

AVA: aortic valve area, AVAi: indexed aortic valve area, PPG: peak pressure gradient, MPG: mean pressure gradient,  $V_{max}$ : maximum velocity.



**Figure 4:** Clustered column chart showing the difference between the mean of PPG and MPG at baseline and on discharge ( $p$  0.007).

**Table: 7 Comparison of The Baseline and Last Follow Up ECHO AV Indices:**

Variable	Baseline Mean (SD)	Last Follow Up Mean (SD)	Mean Difference	95% Confidence Interval of the Difference		p (2-tailed)
				Lower	Upper	
AVA	0.95 (0.78)	2.29 (0.16)	1.34	0.635	2.048	<b>0.005</b>
AVAi	0.55 (0.50)	1.33 (0.12)	0.77	0.348	1.208	<b>0.006</b>
PPG	99 (49)	13.50 (3.33)	85.66	35.19	136.13	<b>0.007</b>
MPG	61 (31)	7.16 (1.72)	53.83	21.27	86.39	<b>0.008</b>
$V_{max}$	4.27 (2.0)	1.18 (0.09)	3.08	0.943	5.223	<b>0.014</b>

AVA: aortic valve area, AVAi: indexed aortic valve area, PPG: peak pressure gradient, MPG: mean pressure gradient,  $V_{max}$ : maximum velocity.

**Table: 8 Comparison of The Pre-operative And Last Follow Up ECHO LV Indices:**

Variable	Baseline Mean (SD)	Last Follow Up Mean (SD)	Mean Difference	95% Confidence Interval of the Difference		p (2-tailed)
				Lower	Upper	
EF	60.83 (11.30)	64 (6.32)	3.16	-5.36	11.70	0.384
FS	30.50 (6.53)	33.83 (6.27)	3.33	-3.456	10.12	0.263
EDD	48.67 (11.41)	45 (4.14)	3.66	-6.369	13.70	0.391
ESD	33.00 (10.11)	28.16 (6.30)	4.83	-4.748	14.41	0.251
IVS	13.00 (2.28)	10 (0.89)	3	1.24	4.75	<b>0.007</b>
PWT	11.83 (1.94)	9.50 (0.54)	2.33	0.269	4.39	<b>0.034</b>
LVM	240.22 (93.99)	149.74 (31.42)	90.47	15.04	165.90	<b>0.027</b>
LVMI	140.07 (52.62)	86.27 (15.26)	53.80	10.35	97.25	<b>0.024</b>

EF: ejection fraction, FS: fractional shortening, ESD: end systolic dimension, EDD: end diastolic dimension, IVS: interventricular septal thickness, PWT: posterior wall thickness, LVM: left ventricular mass, LVMI: left ventricular mass index.

Moreover, Iida *et al.*, [28] compared the annular dimensions and motion following AVNeo (25 patients) to the normal valve, they found normal, maintained annular



dimensions following the procedure with physiological annular dynamics in the form of increased annular area with systole which is a physiological response reflecting the maintained annular dynamism which is abolished in AVR. The excellent hemodynamic performance was reflected on the LV, we found a statistically significant reduction in the LVMI in our patients from a baseline of  $140.07 \pm 52.62 \text{ g/m}^2$  to  $86.27 \pm 15.26 \text{ g/m}^2$  at last follow up, this infers the process of LV reverse remodeling and the regression in the LV mass which was evaluated in the study of Yamamoto et al., [51]. All of these positive outcomes with AVNeo results in better quality of life of the patients beside being free from the long-life anticoagulation [52] which is of extreme importance in the young and middle-aged patients.

#### 4. Limitations

Our study has limitations in the form of the small number of SAA cases (only 6 patients) and this was due to the early adoption of the AVNeo procedure in our center with the fear of patients and cardiologists from the novel procedure. The short duration of follow up (maximum of 23 months) and being a single center-experience.

#### 5. Conclusion

The AVneo is safe, feasible and reproducible procedure with excellent promising outcomes in the setting of SAA and it should be included in our surgical armamentarium for SAA patients due to its promising hemodynamic outcomes.

#### References

- [1] A.B. Freitas-Ferraz, G. Tirado-Conte, F. Dagenais, M. Ruel, T. Al-Atassi, E. Dumont, S. Mohammadi, M. Bernier, P. Pibarot, J. Rodés-Cabau. (2019). Aortic stenosis and small aortic annulus: clinical challenges and current therapeutic alternatives. *Circulation*. 139(23): 2685-2702
- [2] A. Kulik, M. Al-Saigh, V. Chan, R.G. Masters, P. Bédard, B.-K. Lam, F.D. Rubens, P.J. Hendry, T.G. Mesana, M. Ruel. (2008). Enlargement of the small aortic root during aortic valve replacement: is there a benefit? *The Annals of thoracic surgery*. 85(1): 94-100.
- [3] Y.P. Vaidya, S.M. Cavanaugh, A.A. Sandhu. (2021). Surgical aortic valve replacement in small aortic annulus. *Journal of Cardiac Surgery*. 36(7): 2502-2509.
- [4] J.M. Fallon, J.P. DeSimone, J.M. Brennan, S. O'Brien, D.P. Thibault, A.W. DiScipio, P. Pibarot, J.P. Jacobs, D.J. Malenka. (2018). The incidence and consequence of prosthesis-patient mismatch after surgical aortic valve replacement. *The Annals of thoracic surgery*. 106(1): 14-22.
- [5] G. Hoffmann, S.A. Ogbamichael, A. Jochens, D. Frank, G. Lutter, J. Cremer, R. Petzina. (2014). Impact of Patient-Prosthesis Mismatch Following Aortic Valve Replacement on Short-Term Survival: A Retrospective Single Center Analysis of 632 Consecutive Patients with Isolated Stented Biological Aortic Valve Replacement. *The Thoracic and cardiovascular surgeon*. 62(06): 469-474.
- [6] A. Ghoneim, I. Bouhout, P. Demers, A. Mazine, M. Francispillai, I. El-Hamamsy, M. Carrier, Y. Lamarche, D. Bouchard. (2016). Management of small aortic annulus in the era of sutureless valves: a comparative study among different biological options. *The Journal of thoracic and cardiovascular surgery*. 152(4): 1019-1028.
- [7] M.P.B.d.O. Sá, M.M.B. de Carvalho, D.C. Sobral Filho, L.R.P. Cavalcanti, S.d.C. Rayol, R.G.S. Diniz, A.M. Menezes, M.-A. Clavel, P. Pibarot, R.C. Lima. (2019). Surgical aortic valve replacement and patient-prosthesis mismatch: a meta-analysis of 108 182 patients. *European Journal of Cardio-Thoracic Surgery*. 56(1): 44-54.
- [8] R. Bilkhu, M. Jahangiri, C.M. Otto. (2019). Patient-prosthesis mismatch following aortic valve replacement. *Heart (British Cardiac Society)*. 105(Suppl 2), s28-s33.
- [9] P. Pibarot, J.G. Dumesnil. (2006). Prosthesis-patient mismatch: definition, clinical impact, and prevention. *Heart (British Cardiac Society)*. 92(8), 1022-1029.
- [10] E. Bahlmann, D. Cramariuc, J. Minners, M.T. Lønnebakken, S. Ray, C. Gohlke-Baerwolf, C.A. Nienaber, N. Jander, R. Seifert, J.B. Chambers. (2017). Small aortic root in aortic valve stenosis: clinical characteristics and prognostic implications. *European Heart Journal-Cardiovascular Imaging*. 18(4): 404-412.
- [11] S. Dahlbacka, T. Laakso, E.-M. Kinnunen, N. Moriyama, M. Laine, M. Virtanen, P. Maaranen, T. Ahvenvaara, T. Tauriainen, A. Husso. (2021). Patient-prosthesis mismatch worsens long-term survival: insights from the FinnValve registry. *The Annals of thoracic surgery*. 111(4): 1284-1290.
- [12] J.H. Mehaffey, R.B. Hawkins, Z.K. Wegermann, M.V. Grau-Sepulveda, J.M. Fallon, J.M. Brennan, V.H. Thourani, V. Badhwar, G. Ailawadi. (2021). Aortic annular enlargement in the elderly: short and long-term outcomes in the United States. *The Annals of thoracic surgery*. 112(4): 1160-1166.
- [13] N.S. Sujith, A.N. Doddamane, C.S. Hiremath, S. Rao. (2022). Aortic root enlargement: Short-term outcomes from a decade's worth of experience. *Journal of cardiac surgery*. 37(10), 3016-3025.
- [14] V. Rao, J.A. Linick, M.J. Reardon, M.D. Vriesendorp, M. Ruel, H.J. Patel, F. Liu, R.J. Klautz. (2023). Early and late effects of aortic root enlargement: Results from the Pericardial Surgical Aortic Valve Replacement Pivotal Trial: A multicenter, prospective clinical trial. *JTCVS open*. 13: 54-74.
- [15] G.A. Chiariello, P. Bruno, E. Villa, A. Pasquini, N. Pavone, F. Cammertoni, A. Mazza, C. Colizzi, M. Nesta, M. Iafrancesco. (2019). Aortic valve replacement in elderly patients with small aortic annulus: results with three different bioprostheses. *Innovations*. 14(1): 27-36.

- [16] H. Mizoguchi, M. Sakaki, K. Inoue, T. Iwata, K. Tei, T. Miura. (2013). Mid-term results of small-sized St. Jude Medical Regent prosthetic valves (21 mm or less) for small aortic annulus. *Heart and vessels*. 28: 769-774.
- [17] T. Okuno, D. Tomii, J. Lanz, D. Heg, F. Praz, S. Stortecky, D. Reineke, S. Windecker, T. Pilgrim. (2023). 5-Year Outcomes with self-expanding vs balloon-expandable transcatheter aortic valve replacement in patients with small annuli. *Cardiovascular Interventions*. 16(4): 429-440.
- [18] S. Ozaki, I. Kawase, H. Yamashita, S. Uchida, Y. Nozawa, T. Matsuyama, M. Takatoh, S. Hagiwara. (2011). Aortic valve reconstruction using self-developed aortic valve plasty system in aortic valve disease. *Interactive CardioVascular and Thoracic Surgery*. 12(4): 550-553.
- [19] S. Unai, S. Ozaki, D.R. Johnston, T. Saito, J. Rajeswaran, L.G. Svensson, E.H. Blackstone, G.B. Pettersson. (2023). Aortic valve reconstruction with autologous pericardium versus a bioprosthesis: the Ozaki procedure in perspective. *Journal of the American Heart Association*. 12(2): e027391.
- [20] K.S. Mylonas, P.T. Tasoudis, D. Pavlopoulos, M. Kanakis, G.T. Stavridis, D.V. Avgerinos. (2023). Aortic valve neocuspidization using the Ozaki technique: A meta-analysis of reconstructed patient-level data. *American heart journal*. 255: 1-11.
- [21] M.P.B. Sá, I. Chernov, A. Marchenko, V. Chagyan, R. Komarov, M. Askadinov, S. Enginoev, B. Kadyraliev, A. Ismailbaev, M. Tcheglov. (2020). Aortic valve neocuspidization (Ozaki procedure) in patients with small aortic annulus ( $\leq 21$  mm): a multicenter study. *Structural Heart*. 4(5): 413-419.
- [22] T. Wada, S. Miyamoto, T. Shibata, K. Abe, T. Murakami. (2020). Early and Mid-term Results of Aortic Valve Reconstruction with Autologous Pericardium (Ozaki Procedure): A Multicenter Study in Japan Outside of Toho University. *Structural Heart*. 4: 136-137.
- [23] Y. Iida, S. Fujii, S. Akiyama, S. Sawa. (2018). Early and mid-term results of isolated aortic valve neocuspidization in patients with aortic stenosis. *General thoracic and cardiovascular surgery*. 66(11), 648–652.
- [24] M. Krane, J. Boehm, A. Prinzing, J. Ziegelmueller, J. Holfeld, R. Lange. (2021). Excellent hemodynamic performance after aortic valve neocuspidization using autologous pericardium. *The Annals of thoracic surgery*. 111(1): 126-133.
- [25] S. Akiyama, Y. Iida, K. Shimura, S. Fujii, H. Shimizu, S. Sawa. (2020). Midterm outcome of aortic valve neocuspidization for aortic valve stenosis with small annulus. *General thoracic and cardiovascular surgery*. 68: 762-767.
- [26] Y. Iida, S. Akiyama, K. Shimura, S. Fujii, C. Hashimoto, S. Mizuuchi, Y. Arizuka, M. Nishioka, N. Shimura, S. Moriyama. (2018). Comparison of aortic annulus dimensions after aortic valve neocuspidization with those of normal aortic valve using transthoracic echocardiography. *European Journal of Cardio-Thoracic Surgery*. 54(6): 1081-1084.
- [27] Y. Yamamoto, K. Iino, Y. Shintani, H. Kato, K. Kimura, G. Watanabe, H. Takemura. In *Comparison of aortic annulus dimension after aortic valve neocuspidization with valve replacement and normal valve*, *Seminars in thoracic and cardiovascular surgery*, 2017; Elsevier: 2017; pp 143-149.
- R. Maragna, S. Pirola, A. Baggiano, G. Mastroiacovo, A. Bonomi, S. Musthaq, A. Frappampina, A. Volpe, G. Polvani, G. Pontone. (2023). 4D flow cardiovascular magnetic resonance for the assessment of aortic valve repair with ozaki technique. *Journal of Cardiovascular Computed Tomography*. 17(4): S92.
- [28] G. Weiss, Z. Arnold, M. Grabenwöger, B. Winkler. (2023). Invited commentary to: 4D-flow cardiac magnetic resonance for the assessment of Aortic valve repair with Ozaki TEchnique. *European journal of cardio-thoracic surgery : official journal of the European Association for Cardio-thoracic Surgery*. 64(6), ezad358.
- [29] A. Secinaro, E.G. Milano, P. Ciancarella, M. Trezzi, C. Capelli, P. Ciliberti, E. Cetrano, D. Curione, T.P. Santangelo, C. Napolitano. (2022). Blood flow characteristics after aortic valve neocuspidization in paediatric patients: a comparison with the Ross procedure. *European Heart Journal-Cardiovascular Imaging*. 23(2): 275-282.
- [30] N. Yamamoto, H. Ito, K. Inoue, A. Futsuki, K. Hirano, Y. Shomura, Y. Ozu, Y. Katayama, T. Komada, M. Takao. (2022). Impact of valvuloarterial impedance on left ventricular reverse remodeling after aortic valve neocuspidization. *Journal of Cardiothoracic Surgery*. 17(1): 13.
- [31] M. Krane, A. Amabile, J.A. Ziegelmueller, A. Geirsson, R. Lange. (2021). Aortic valve neocuspidization (the Ozaki procedure). *Multimedia Manual of Cardiothoracic Surgery: MMCTS*. 2021.
- [32] S. Bleiziffer, T.K. Rudolph. (2022). Patient Prosthesis Mismatch After SAVR and TAVR. *Frontiers in cardiovascular medicine*. 9, 761917.
- M. Krane, A. Amabile, J.A. Ziegelmueller, A. Geirsson, R. Lange. (2021). Aortic valve neocuspidization (the Ozaki procedure). *Multimedia Manual of Cardiothoracic Surgery: MMCTS*. 2021.
- [33] P.T. O’Gara, R.O. Bonow, C.M. Otto. (2009). Prosthetic heart valves. *Valvular Heart Disease: A Companion to Braunwald’s Heart Disease E-Book*. 383.
- [34] J. Ternacle, P. Pibarot, H.C. Herrmann, S. Kodali, J. Leipsic, P. Blanke, W. Jaber, M.J. Mack, M.-A. Clavel, E. Salaun. (2021). Prosthesis-patient mismatch after aortic valve replacement in the PARTNER 2 trial and registry. *Cardiovascular Interventions*. 14(13): 1466-1477.
- [35] M. Dismorr, N. Glaser, A. Franco-Cereceda, U. Sartipy. (2023). Effect of prosthesis-patient mismatch on long-term clinical outcomes after

- bioprosthetic aortic valve replacement. *Journal of the American College of Cardiology*. 81(10): 964-975.
- [36] I.T. Fazmin, J.M. Al. (2023). Prosthesis-Patient Mismatch and Aortic Root Enlargement: Indications, Techniques and Outcomes. *Journal of cardiovascular development and disease*. 10(9), 373.
- [37] A. Van Linden, M. Arsalan, T. Körschgen, J. Blumenstein, J. Kempfert, F. Hecker, T. Walther. (2019). Randomized (CO) mparison of (TRI) fecta and (P) erimount Magna Ease Supraannular Aortic Xenografts—CO. TRI. P Study. *The Thoracic and cardiovascular surgeon*. 67(04): 266-273.
- [38] H.H. Dagnegård, K. Bekke, S.M. Kolseth, N. Glaser, C. Wallén, I. El-Hamamsy, K.O. Vidisson, A.S. Lie, J.B. Valentin, U. Sartipy. (2022). Survival after aortic root replacement with a stentless xenograft is determined by patient characteristics. *The Journal of thoracic and cardiovascular surgery*. 164(6): 1712-1724. e10.
- [39] P.P. Leone, D. Regazzoli, M. Pagnesi, G. Costa, R. Teles, M. Adamo, M. Taramasso, F. De Marco, A. Mangieri, F. Kargoli. (2023). Prosthesis-patient mismatch after transcatheter implantation of contemporary balloon-expandable and self-expandable valves in small aortic annuli. *Catheterization and Cardiovascular Interventions*. 102(5): 931-943.
- [40] L. Voigtländer, W.-K. Kim, V. Mauri, A. Goßling, M. Renker, A. Sugiura, M. Linder, T. Schmidt, N. Schofer, D. Westermann. (2021). Transcatheter aortic valve implantation in patients with a small aortic annulus: performance of supra-, intra-and infra-annular transcatheter heart valves. *Clinical Research in Cardiology*. 110(12): 1957-1966.
- [41] J. Haunschild, S. Scharnowski, M. Mende, K. von Aspern, M. Misfeld, F.-W. Mohr, M.A. Borger, C.D. Etz. (2019). Aortic root enlargement to mitigate patient–prosthesis mismatch: do early adverse events justify reluctance? *European Journal of Cardio-Thoracic Surgery*. 56(2): 335-342.
- [42] W. Yu, D.Y. Tam, R.V. Rocha, A. Makhdom, M. Ouzounian, S.E. Fremes. (2019). Aortic root enlargement is safe and reduces the incidence of patient-prosthesis mismatch: a meta-analysis of early and late outcomes. *Canadian Journal of Cardiology*. 35(6): 782-790.
- [43] T. Murashita, Y. Okada, H. Kanemitsu, N. Fukunaga, Y. Konishi, K. Nakamura, T. Koyama. (2014). Efficacy of stentless aortic bioprosthesis implantation for aortic stenosis with small aortic annulus. *The Thoracic and cardiovascular surgeon*. 446-451.
- [44] Gersak, B., Fischlein, T., Folliguet, T. A., Meuris, B., Teoh, K. H., Moten, S. C., Solinas, M., Miceli, A., Oberwalder, P. J., Rambaldini, M., Bhatnagar, G., Borger, M. A., Bouchard, D., Bouchot, O., Clark, S. C., Dapunt, O. E., Ferrarini, M., Laufer, G., Mignosa, C., Millner, R., ... Glauber, M. (2016). Sutureless, rapid deployment valves and stented bioprosthesis in aortic valve replacement: recommendations of an International Expert Consensus Panel. *European journal of cardiothoracic surgery : official journal of the European Association for Cardio-thoracic Surgery*, 49(3), 709-718.
- [45] H. Saisho, M. Scharfschwerdt, T. Schaller, N. Sadat, A. Aboud, S. Ensminger, B. Fujita. (2022). Ex vivo evaluation of the Ozaki procedure in comparison with the native aortic valve and prosthetic valves. *Interactive CardioVascular and Thoracic Surgery*. 35(3): ivac199.
- [46] N. Yamamoto, H. Ito, K. Inoue, A. Futsuki, K. Hirano, Y. Shomura, Y. Ozu, Y. Katayama, T. Komada, M. Takao. (2022). Impact of valvuloarterial impedance on left ventricular reverse remodeling after aortic valve neocuspidization. *Journal of Cardiothoracic Surgery*. 17(1): 13.
- [47] V. Patel, S. Unai, R. Moore, H. Layoun, S. Harb, M.Z. Tong, T. Karamlou, H.K. Najm, L.G. Svensson, J. Rajeswaran. (2023). The Ozaki Procedure: Standardized Protocol Adoption of a Complex Innovative Procedure. *Structural Heart*. 100217.