



# Functional outcome of arthroscopic release of posttraumatic stiff elbow

*Mostafa Ezzat<sup>1</sup>, Yasser El Safoury<sup>1</sup>, Ahmed Abdelsattar<sup>1\*</sup>, Ayman Mansour<sup>1</sup>*

<sup>1</sup>*Faculty of Medicine, Cairo university, Egypt.*

## Abstract

An elbow is considered stiff if its flexion is between 120 & 130 degrees & its diminution in extension exceeds 30 degrees. Elbow stiffness results in significant functional impairment. Previously, open capsular release was the accepted method of managing elbow contractures. The utilization of arthroscopic techniques on a global scale has led to documented instances of intraoperative nerve injuries. To evaluate the role of elbow arthroscopy in intra-articular visualization & management of post-traumatic stiff elbow. This prospective randomized research was performed on 35 cases with post-traumatic stiff elbows operated on with arthroscopic elbow release at Kasr El-Ainy, Faculty of Medicine, Cairo University, from April 2021 to June 2022. Disease duration has no statistically significant effect on Pre-ROMM, Immediate POST ROM, post –ROM 6 months and Mayo elbow performance score at 6 months. There was statistically significance increase between mayo score pre-operative and mayo score 6 months. There was no relationship between pre-operative flexion ROM and post-operative nerve injury. A single case with percentage of 2.9 had recurrence after 6 months and did open release and 4 cases with percentage of 11.4 had superficial infection. Arthroscopic arthrolysis restores normal elbow function, making it a viable option for the management of post-traumatic elbow rigidity.

**Keywords:** Stiff elbow, Elbow arthroscopy, Bony ankyloses.

**Full length article** \*Corresponding Author, e-mail: [asatar412@yahoo.com](mailto:asatar412@yahoo.com)

## 1. Introduction

Hand positioning in space & serving as a stabilizer through motions including carrying, throwing, pressing, drawing, and lifting are the primary functions of the elbow. For the elbow to perform its function, it must have a complete or nearly complete range of motion (ROM)[1]. The elbow typically exhibits an arc of motion spanning from 0 to 145 degrees of flexion. A biomechanical study determined that 90% of daily activities, excluding labor and athletics, can be accomplished with an arc of motion ranging from 30 to 130 degrees[2]. As a result, an elbow exhibiting a reduction in extension exceeding 30 degrees &/or a flexion falling below 120–130 degrees has been designated as a rigid elbow[3]. Elbow stiffness is a common occurrence that often results in significant functional impairment that can be difficult to treat. Thus, prevention becomes obligatory. In the event that preventive measures prove ineffective, non-operative interventions, including division or physiotherapy, are typically advised as initial therapeutic courses of action. Surgical intervention may be deemed necessary following a minimum of six months of failure with the conservative treatment approach[4]. Previously, open capsular release was the accepted method of managing elbow contractures.[5] The utilization of arthroscopic techniques on a global scale has led to documented instances of intraoperative nerve injuries. Due to the severity of these complications, certain authors have expressed grave

apprehensions regarding the safety of this procedure[8-6] . The purpose of the present work was to assess the function of elbow arthroscopy in intra-articular visualization & management of post-traumatic stiff elbow.

## 2. Patient & methods

This prospective randomized research was performed on 35 patients with post-traumatic stiff elbows operated on with arthroscopic elbow release at Kasr El-Ainy, Faculty of Medicine, Cairo University, from April 2021 to June 2022.

### 2.1 Inclusion criteria

Symptomatic stiff elbow failed conservative management for more than 6 months, extra-articular causes, previous fixation of a fracture around the elbow, and intra-articular causes.

### 2.2 Exclusion criteria

Non-symptomatic stiff elbow, infection, bony ankyloses, and arthritic elbow.

### 2.3 Method

All patients in this study were anesthetized with general anesthesia. Prophylactic broad-spectrum antibiotic (3rd generation cephalosporin) was taken with induction of anesthesia & proceeded for two days' after surgery, then switched to oral antibiotics for 10 days. The individual was

positioned in the prone position. The operative arm was placed on a 4-inch padded block, and the elbow was bent over an arm board at the cases's side, which was parallel to the table. The forearm could then be rotated internally or externally onto the arm board to allow medial or lateral access for any planned open procedure. This kept the nerves and blood vessels in the axilla from being compressed. After exsanguinating the limb, a pneumatic tourniquet was distended to a pressure of 250 mmHg and affixed to the arm. The limb was draped and prepared sterilely. In order to mitigate fluid extravasation, a compressive material was utilized to envelop the forearm and hand. Utilized were a 3.5-mm full-radius arthroscopic shaver and a 4.0-mm 30° arthroscope. A low-pressure (30–35 psi) arthroscopic compressor was utilized to enhance visibility and prevent joint overextension. An effort was made to insufflate the elbow using 30 to 50 ml of saline through a direct lateral or posterior portal. The proximal antro-medial portal was found as the first point of entry into the joint by using the medial epicondyle & medial intramuscular septum as landmarks. A scalpel incision was exclusively performed through the epidermis, and a blunt trochar was utilized to attempt penetration through the capsule. A proximal lateral portal is created through the implementation of an outside-in approach. As debridement progresses, adhesions from the radiocapitellar joint must be eliminated. The proximal anterior capsule was detached from the humerus in order to increase the space available for adequate capsular release and to facilitate greater capsular mobility. First, an anterior capsulotomy is made near the coronoid fossa. It then moves laterally until it reaches the lateral intermuscular septum. The lateral part of the arthroscope was put in place, and the capsulotomy was extended from where it had been released medially to the medial intermuscular septum. duration of capsular excision should be prolonged until the anterior structures cease to be constricted, while ensuring that it does not surpass 2 cm distally. After achieving full extension by releasing the anterior capsular ligament, a blunt trochar was used to create a posterior central portal by cutting the skin deeply through the triceps muscle and capsule into the olecranon fossa with a scalpel. A cannula was then inserted through this portal. Following debridement of the olecranon fossa, the posterior capsule was raised away from the distal humerus. Next, scar tissue and adhesions were eliminated from the medial and lateral channels. Attachments to the lateral gutter are taken off from the front to the back. The posterior radiocapitellar recess may be easier to clean out through a direct lateral portal. As instructed, posterior capsulectomy was executed, followed by posterolateral capsulectomy, & lastly, posteromedial capsulectomy.

### **2.3.1 Post-operative Instructions**

Icing was very important for 1st seven to fourteen days after operation. Anesthesia typically provides a nerve block after your surgery while you are still in the recovery room. Although it was at your discretion whether or not to undergo the nerve block, it was generally advised in order to assist with pain management. Sling Application for your convenience, a splint was fitted & deposited in the operating room. Beginning the day following surgery, you may unwind the sling's strap to elevate and flex the elbow three to four times daily.

### **2.3.2 Physical Therapy**

#### **2.3.2.1 Stage 1: Early ROM (zero to four weeks)**

A soft postpartum dressing was maintained throughout the initial week. The surgeon removed the sutures within ten to fourteen days. At night, an extension splint must be worn. Dynamic splinting is seldom implemented. Commence ROM exercises five times daily: PROM and AAROM in supination, pronation, flexion, and extension, respectively. Unrestricted elbow range of motion Strengthening and grip ROM exercises. Notify the physician ten days after surgery if drainage from the portals persists.

#### **2.3.2.2 Stage 2: Restore Function (over four weeks)**

As tolerance allows, increase both active and passive ROM. Perform light strengthening exercises on the elbow and forearm. Put the night splint away. Care of Incisions You would have a delicate dressing on your arm following surgery. During the initial week, this would persist. At your first post-operative visit (ten to fourteen days after surgery, on average), sutures were extracted. With the dressing in position, you may shower following surgery. Throughout the shower, the garment remains dry. Place your limb in a large garbage bag while draping the dressing over it. Once the dressings have been removed, it is acceptable to let water flow over the incisions or sutures. After rinsing the incision, blot it dry using a clean cloth; avoid rubbing. Bathe, swim, or use a spa until the sutures have been removed and the incisions have fully recovered to decrease the risk of skin infection. It is imperative to consistently cleanse your hands prior to examining your incisions. It is RAWITE to apply any lotions or ointments to the incisions. Bruising and swelling After surgery, edema &/or discoloration were frequently observed. This was anticipated as a result of hemorrhaging.

#### **2.3.2.3 Follow up evaluation**

The patients were followed up clinically by a Mayo score at 3 and 6 months. Patients were checked after 2 weeks for wound care & stitch removal. All patients were checked for a mayo elbow score (pain (45), motion (20), stability (10), Function tics (25) degrees) after 3 and 6 months.

### **2.3.3 Statistical analysis**

Data analysis packages used were SPSS version 21; data was coded and entered on an Excel sheet, then extracted for SPSS. Quantitative data was obtainable by mean, SD. Qualitative data was obtainable by number and percentage. Statistical tests were done for parametric numerical values (student t test and ANOVA test) and non-parametric qualitative data (Chi square with fischer exact test). Correlation with person tests were done to see relations between numerical values. The level of significance was considered if p value to or below 0.05.

### **2.3.4 Case presentation**

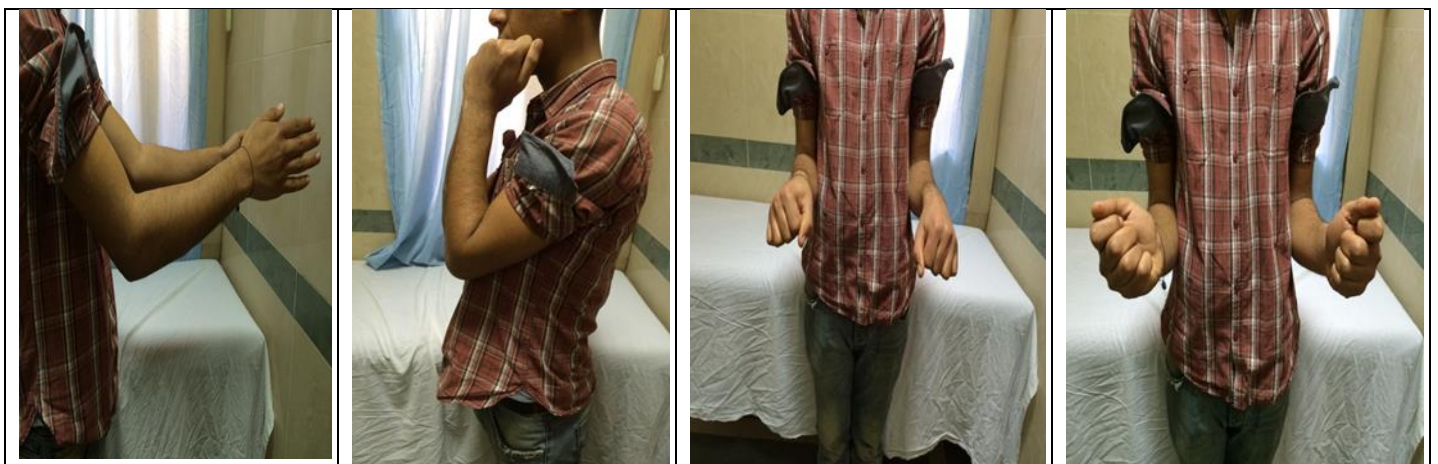22-year-old male patient presenting with Rt-sided post-traumatic stiff elbow after fracture radial head fixation in 2019 is a right-handed student. Clinical examination: Inspection: scar on lateral aspect of elbow healed with primary intention, no swelling. Palpation: no tenderness, no swelling. Ulnar nerve examination: normal, no sign of ulnar nerve entrapment. ROM: Active flexion was 110 degrees;

passive flexion was 120 degrees. Active extension was 70 degrees, and passive extension was 60 degrees. The Mayo elbow performance score was 70. Radiographs: show a united fracture of the radial head and osteophyte at the medial epicondyle.

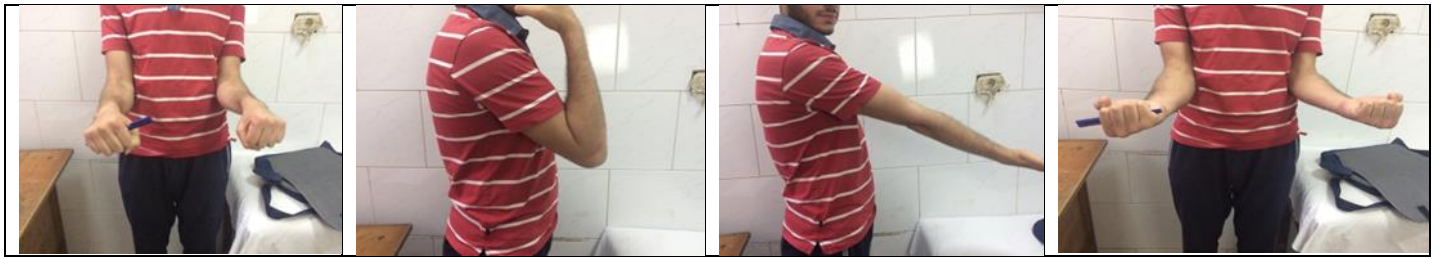### 3. Discussion

Regarding our study, we had 35 patients suffering from post-traumatic stiff elbow, 27 cases due to intra-articular pathology, and 8 cases with extra-articular pathology. In comparison with other studies, Kim et al. examined twenty-five cases suffering from motion loss due to degenerative or post-traumatic arthritis over a mean of twenty-five months of follow-up. The average gain of the arc of motion was 24 [9]. Phillips and Strasburger conducted a study on twenty-five individuals who had elbow contractures resulting from post-traumatic arthritis in fifteen instances & degenerative arthritis in ten instances. The average duration of follow-up was eighteen months. According to the authors, the post-traumatic group showed superior outcomes with an average increase of 50°, but the degenerative arthritis group only had an average increase of twenty-seven degrees [10]. Kelly et al. documented a cohort of twenty-five people who experienced restricted movement due to primary osteoarthritis in twenty-one cases, rheumatoid arthritis in one case, & post-traumatic arthritis in three cases. The average duration of follow-up was 67 months (24–123). The average arc of motion increase was 21° [11]. Our study revealed that disease duration has no statistical significant effect on Pre-ROMM, Immediate POST ROM, post –ROM 6 months and Mayo elbow performance score at 6 months. There was statistically significance increase between mayo score pre-operative and mayo score 6 months. Regarding our study complications, there was no relationship between pre-operative flexion ROM and post-operative nerve injury. A single case with a percentage of 2.9 had recurrence after 6 months and did open release, while 4 cases with a percentage of 11.4 had superficial infection.

Kelly and her colleagues conducted a study on the difficulties that occurred after 473 elbow arthroscopies. They discovered that there were only four significant issues, accounting for 0.8% of the cases, and 50 minor complications, accounting for 11% of the cases. All four main problems were joint space infections, while the mild complications varied from chronic drainage to temporary nerve palsy [12]. Haapaniemi et al. documented a case where both the median & radial nerves were completely severed in an individual with post-traumatic elbow contracture. The individual was treated with arthroscopic capsular release [13]. Gay et al. documented a case of ulnar nerve transection in an individual who received a revision arthroscopic contracture release [14]. Comparing complication rates between open and arthroscopic capsular release is difficult since there are no direct comparative studies in the literature. Historically, the literature suggests a low complication rate following open elbow capsulotomy but this data does not seem to be confirmed [15]. Table 1 showed that 18 cases were males, 17 cases were females, 30 cases were RT-handed, 5 cases were LT-handed, 26 cases were RT-sided, 9 cases were LT-sided, 27 cases were intra-articular pathology, 8 cases were extra-articular pathology, 18 cases were radial head fractures, 8 cases were ICH fractures, a single individual was a uni-condyle fracture, 3 individuals were Olecranon fractures, and 5 cases were shaft humerus fractures. Disease duration has no statistical significant effect on Pre-ROMM, Immediate POST ROM, post –ROM 6 months and Mayo elbow performance score at 6 months (Table 2). There was statistically significance increase between mayo score pre-operative and mayo score 6 months. (Table 3). **Table 4** showed that there was no relationship between pre-operative flexion ROM and post-operative nerve injury. Figure 3 showed that single case with percentage of 2.9 had recurrence after 6 months and did open release. Figure 4 showed that 4 cases with percentage of 11.4 had superficial infection.



**Figure 1:** Clinical pre-operative ROM



**Figure 2:** 6 months' Post-operative clinical photos for ROM

**Table 1:** Demographic data

		Number	%
Sex	man	18	51.4%
	woman	17	48.6%
Hand dominance	RT-handed	30	85.7%
	LT-handed	5	14.3%
Side	RT-handed	26	74.3%
	LT-handed	9	25.7%
Site of pathology	Intra-articular	27	77.1%
	Extra-articular	8	22.9%
Traumatic causes	Radial head fracture	18	51.4%
	ICH fracture	8	22.9%
	uni-condyle fracture	1	2.9%
	Olecranon fracture	4	8.6%
	shaft humerus	5	14.3%

**Table 2:** Correlation between duration of pathology and pre-operative ROM, post-ROM, Mayo elbow score

		duration of the pathology	total pre Rom	immediate post ROM	total post ROM 6 months	mayo score 6 months
duration of the pathology	Pearson Correlation	1	-.005	.070	.048	.318
	Sig. (2-tailed)		.977	.691	.786	.063
	N	35	35	35	35	35

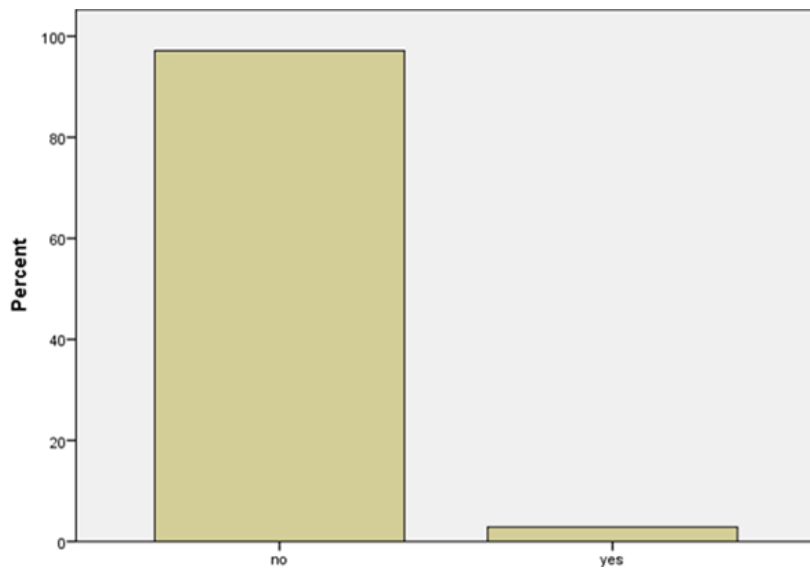
**Table 3:** Correlation between pre-operative Mayo scoring system and post-operative mayo score after 6 months

		mayo score pre-operative		
mayo score 6 months			.490**	1
		Sig. (2-tailed)	.003	
		N	35	35

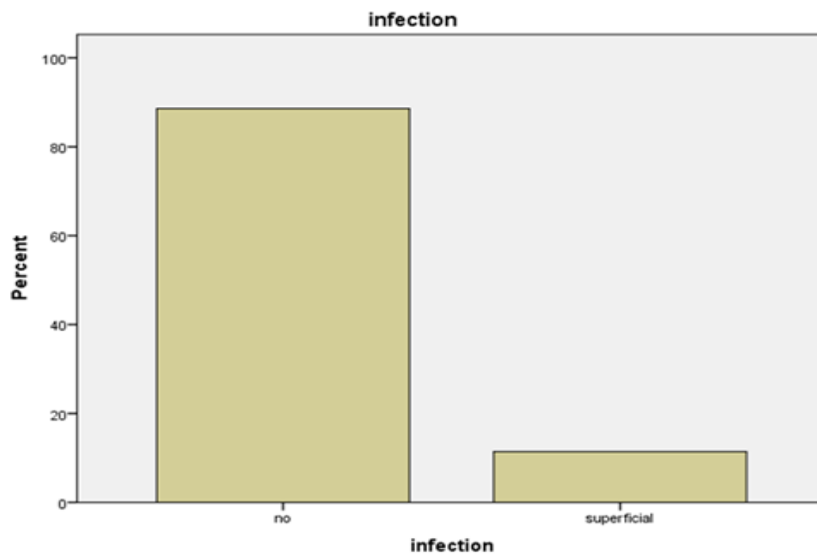
**Table 4:** Relation between pre- operative flexion range and nerve injury

T test					
	Neve injury	N	Mean	Std. Deviation	Std. Error Mean
Pre flexion rom degree	Yes	0 <sup>a</sup>	.	.	.
	No	35	99.71	12.001	2.029

a. t cannot be computed because at least one of the groups is empty.



**Figure 3:** Bar chart for recurrence rate.



**Figure 4:** Bar chart for infection rate.

#### 4. Conclusions

The present research illustrates that one year after undergoing arthroscopic arthrolysis of the elbow, patients can obtain favorable results in terms of range of motion, functional ability, and pain reduction by engaging in active and passive exercises throughout the post-operative period. Based on the favorable clinical results & low occurrence of problems, we can confidently assert that arthroscopic arthrolysis is an excellent choice for addressing post-traumatic elbow stiffness, as it effectively recovers normal elbow function.

#### References

- [1] C.L. Dunham, R.M. Castile, N. Havlioglu, A.M. Chamberlain, S.P. Lake. (2018). Temporal patterns of motion in flexion-extension and pronation-supination in a rat model of posttraumatic elbow contracture. *Clinical orthopaedics and related research*. 476(9), 1878.
- [2] B.F. Morrey, L.J. Askew, E.Y. Chao. (1981). A biomechanical study of normal functional elbow motion. *The Journal of Bone and Joint Surgery*. 63(6), 872-877.
- [3] J.O. Sojbjerg. (1996). The stiff elbow: How I do it. *Acta Orthopaedica Scandinavica*. 1;67(6):626-31.
- [4] S. Nandi, S. Maschke, P.J. Evans, J.N. Lawton. (2009). The stiff elbow. *Hand*. 4(4), 368-379.

- [5] N.L. Van Zeeland, K. Yamaguchi. (2010). Arthroscopic capsular release of the elbow. *Journal of Shoulder and Elbow Surgery*. 19(2): 13-19.
- [6] D. Blonna, E. Bellato, E. Marini, M. Scelsi, F. Castoldi. (2011). Arthroscopic treatment of stiff elbow. *International Scholarly Research Notices*. 2011.
- [7] A.F. Ahmed, O.Z. Alzobi, A.T. Hantouly, A. Toubasi, R. Farsakoury, K. Alkhelaifi, B. Zikria. (2022). Complications of elbow arthroscopic surgery: a systematic review and meta-analysis. *Orthopaedic Journal of Sports Medicine*. 10(11), 23259671221137863.
- [8] L. Pederzini, M. Tosi, M. Prandini, F. Nicoletta. (2013). Elbow arthroscopy in stiff elbow. In *Elbow Arthroscopy*. (pp. 43-56). Berlin, Heidelberg: Springer Berlin Heidelberg.
- [9] S.J. Kim, H.K. Kim, J.W. Lee. (1995). Arthroscopy for limitation of motion of the elbow. *Arthroscopy: The Journal of Arthroscopic & Related Surgery*. 11(6), 680-683.
- [10] B.B. Phillips, S. Strasburger. (1998). Arthroscopic treatment of arthrofibrosis of the elbow joint. *Arthroscopy: The Journal of Arthroscopic & Related Surgery*. 14(1), 38-44.
- [11] E.W. Kelly, R. Bryce, J. Coghlan, S. Bell. (2007). Arthroscopic debridement without radial head excision of the osteoarthritic elbow. *Arthroscopy: The Journal of Arthroscopic & Related Surgery*. 23(2), 151-156.
- [12] E.W. Kelly, B.F. Morrey, S.W. O'Driscoll. (2001). Complications of elbow arthroscopy. *The Journal of Bone and Joint Surgery*. 83(1), 25.
- [13] T. Haapaniemi, M. Berggren, L. Adolfsson. (1999). Case report complete transection of the median and radial nerves during arthroscopic release of post-traumatic elbow contracture. *Arthroscopy: The Journal of Arthroscopic & Related Surgery*. 15(7), 784-787.
- [14] D.M. Gay, B.S. Raphael, A.J. Weiland. (2010). Revision arthroscopic contracture release in the elbow resulting in an ulnar nerve transection: a case report. *The Journal of Bone and Joint Surgery*. 92(5), 1246-1249.
- [15] N.L. Van Zeeland, K. Yamaguchi. (2010). Arthroscopic capsular release of the elbow. *Journal of Shoulder and Elbow Surgery*, 19(2), 13-19.