



# Functional outcomes of the use of posterior kocher langenbeck approach versus anterior intrapelvic approach in treatment of transverse acetabular fractures

*Ahmed S. Abdelnaem<sup>1</sup>, Mohamed A. Abozeid<sup>1</sup>, Ahmed H. Hasan, Ahmed S. Abdelfattah<sup>1</sup>*

*Faculty of Medicine, Minia University*

## Abstract

The transverse fracture of the acetabulum is confined to the acetabulum itself and does not affect the obturator ring. A transverse fracture is characterized by the involvement of both the front and back parts of the acetabulum. Current conventional treatment approaches using combined double or extensile approach and posterior and anterior column plating are now regarded as quite aggressive. The objective is to assess the functional result of patients who have had surgical fixation of transverse acetabular fractures using the Kocher-Langenbeck method compared to those with anterior intrapelvic fractures. This study was a prospective randomized controlled trial that involved a total of 30 patients who presented with transverse acetabular fractures at Minya University Hospital between January 2021 and June 2023. There were no statistically significant differences seen between the analyzed groups in terms of age, sex, Mechanism of Injury, side, complications, Initial displacement preoperatively, Postoperative quality of reduction, and Merle d'Aubigne score. The surgical treatment of transverse acetabular fractures can be performed using either anterior or posterior techniques.

**Keywords:** kocher-langenbeck (KL), transverse acetabular fractures (TAR), anterior intrapelvic approach.

**Full length article** \*Corresponding Author, e-mail: [ahmed.saved1@mu.edu.eg](mailto:ahmed.saved1@mu.edu.eg)

## 1. Introduction

A precise comprehension of both the patient's injury and the kind of acetabular fracture is crucial due to the intricate anatomical connections of the acetabulum, making the selection of the appropriate technique to treat the fracture essential. Several publications have shown that patients treated with a twofold or comprehensive approach protocol experience notable intra- and postoperative problems, such as severe bleeding, deep wound infection, and the development of functional heterotopic ossification. The user's text is empty. Due to the serious repercussions of a more intrusive treatment plan, a small number of writers have lately suggested employing a singular method for treating transverse acetabular fractures (TAR). The argument revolves around determining the most effective strategy for achieving anatomical reduction, assessing the other column, and ensuring stable fixation. The options being considered include the anterior intra-pelvic approach, the Kocher-Langenbeck (KL) approach, or the implementation of a sequential protocol. While literature has provided some indications for each approach, such as the level of transverse fracture (transtectal, juxtatectal, or infratectal), the obliquity of the fracture line, the direction, rotation, and amount of displacement, no specific criteria

have been reported to determine which approach to choose [1-2].

## 2. Patients and methods

A prospective randomized controlled trial was conducted from January 2021 to June 2023 to assess and compare the functional result of 30 patients with transverse fracture acetabulum who were treated using the KL technique vs the anterior route. Patients assessed at our Minya University Hospital. We included a cohort of 30 patients who presented with transverse acetabular fractures in our investigation. The patients were categorized into two groups: Group A included of 15 patients who underwent open reduction and internal fixation (ORIF) using the KL method, whereas Group B consisted of 15 patients who underwent ORIF using the anterior intrapelvic route.

### 2.1 Inclusion criteria

Individuals aged 18-60 years with exclusive transverse acetabular fractures.

### 2.2 Exclusion criteria

- Fractures occurring more than 3 weeks after the initial injury.

- Fractures caused by disease or abnormal conditions.
- Prior or ongoing infection.
- Unsuccessful previous attempt at stabilization.
  - If accompanied by pelvic ring trauma.

The patients had the following procedures: preoperative assessment, preoperative anteroposterior and Judet x-rays, preoperative 3D CT scan, random patient selection, postoperative x-rays, rehabilitation program, and follow-up examination.

### **2.3 Procedure for anterior intrapelvic approach in surgery**

The patient is positioned in a supine position on a radiolucent operating room table. The whole of the lower abdomen and pelvic area is thoroughly prepped and covered with drapes. The surgical cut starts 2 cm above the symphysis pubis in a horizontal manner, with the length spanning from the same side's external inguinal ring to the other side's external ring [3]. The rectus abdominis muscle is divided vertically from bottom to top, with caution given to remain outside the peritoneal cavity in the upper part. To safeguard the bladder, the rectus muscle is lifted upwards by means of precise cutting, allowing for the elevation of the rectus muscle in order to reveal the symphysis body and the upper pubic ramus. The rectus and neurovascular structures are laterally and anteriorly retracted for protection. The last portion of the surgical process is conducted below the iliac vessels, femoral nerve, and psoas muscle. Many vascular connections are commonly seen, with most being communications between the inferior epigastric and obturator vessels. External iliac anastomoses that extend to the bladder, as well as numerous nutrition vessels, are frequently seen. These are joined together as needed using either suture ligation or vascular clips [3]. The access is extended from the front to the back of the pelvic brim, by separating and raising the iliopectineal fascia upwards and the obturator fascia downwards.

### **2.4 Surgical technique for posterior KL approach**

The patient is placed either in the lateral decubitus posture or prone on pillows. The skin is then incised a few millimeters distal and lateral to the posterior superior iliac spine. To enhance visibility in obese or muscular individuals, a closer extension may be employed. The incision is extended anteriorly across the greater trochanter. The incision follows a curved path from the tip of the greater trochanter to the outer side of the femoral shaft, ending at the middle part of the thigh, just below where the gluteus maximus tendon attaches. Following the division of the subcutaneous tissues, proceed to make a precise incision along the same subcutaneous tissues:

#### **2.4.1 The gluteus maximus muscle (utilizing scissors)**

#### **2.4.2 The iliotibial tract (by means of a scalpel)**

The gluteus maximus is divided along the alignment of its fibers, beginning at the greater trochanter and extending proximally until it intersects with the first neurovascular bundle. The result is the formation of a posterior muscular belly, supplied by the inferior gluteal artery, and an anterior belly, supplied by the superior gluteal artery. The anterior belly consists of approximately one third of the gluteus maximus and the tensor fascia latae muscle. The iliotibial tract is cut in the lower half along its fibers till reaching the middle portion of the thigh. Remove the layer

*Abdelnaem et al., 2023*

of adipose tissue that is covering the short external rotators, revealing the point where the piriformis tendon, the gemelli, and the internal obturator muscle attach [4]. The sciatic nerve is positioned below the gemelli and internal obturator muscles, and in front of the piriformis muscle, located between the greater trochanter and the ischial tuberosity. Thoroughly see the sciatic nerve and Constantly ensuring that the nerve is not subjected to any direct pressure or strain. The piriformis tendon is isolated and a suture is positioned at a minimum distance of 1 cm to the side of its femoral insertion, followed by the dissection of the tendon. To prevent harm to the medial circumflex femoral artery, which is located at the top border of the quadratus femoris muscle, it is advisable to leave a 1 cm section of tendon linked to the greater trochanter. The piriformis muscle is moved to the side in order to reveal the area behind the hip socket known as the retroacetabular surface, which is located near the larger sciatic notch [4]. The conjoined tendon of the obturator internus muscle and the superior and inferior gemelli muscles is recognized. The medial circumflex femoral artery is protected by tagging and incising them 1 cm laterally from their femoral insertions. The muscle bellies of the three conjoined muscles are redirected to the side in order to reach the lower sciatic notch, the bigger sciatic notch, the ischial spine, and the lesser sciatic notch, which are now visible [5].

### **2.5 Postoperative Management**

#### **2.5.1 Radiographic evaluation**

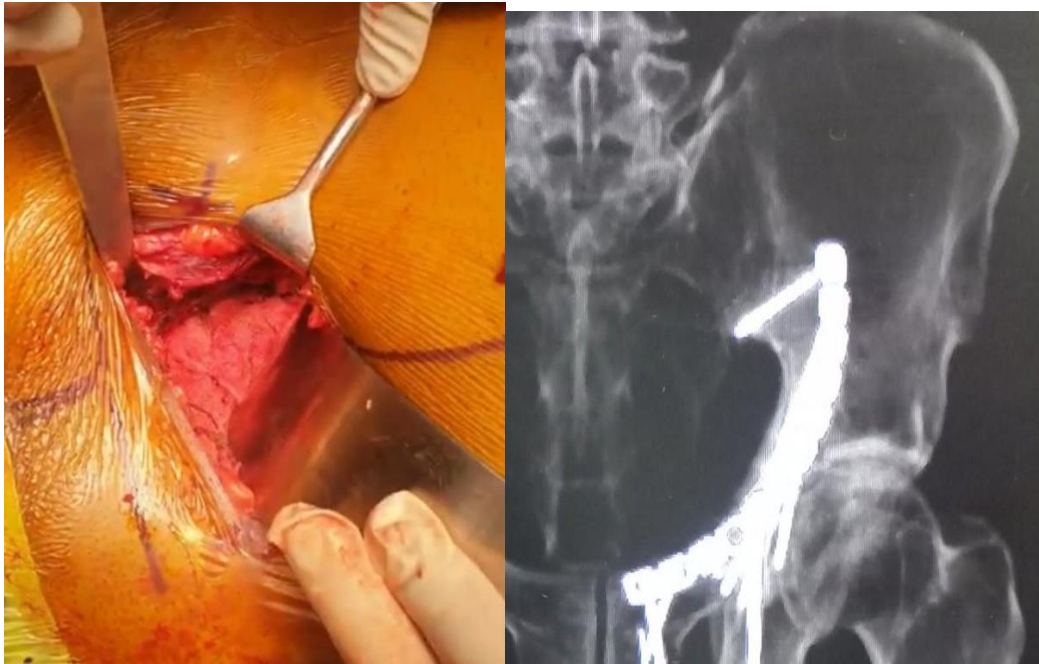
The quality of the alignment is evaluated using the criteria established by Matta [11] on the CT scans taken immediately after the surgery. The grading system categorizes the reduction as anatomical (maximum displacement on all images is 0-1mm), imperfect (2-3mm), or bad (more than 3mm) [6]. Patients will have a review at the follow-up clinic after 2 weeks to assess the wound and remove sutures. Subsequent reviews will take place at 6 weeks, 12 weeks, 6 months, and 1 year. During the subsequent review visits, AP and Judet views will be taken, and the functional result will be assessed and documented using the modified Merle d'Aubigne and Postel (MDP) score [7].

#### **2.6 Statistical Analysis**

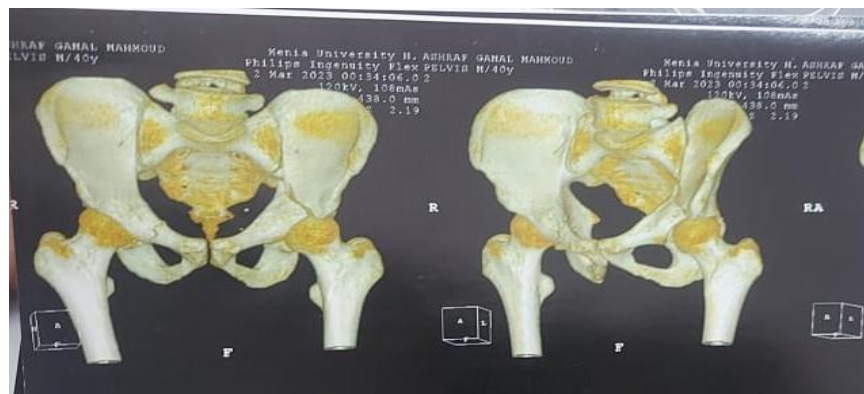The means and standard deviation for quantitative variables and the frequencies and percentages for qualitative variables were determined using SPSS Version 22.0 (IBM Corp, Armonk, NY). The Chi-square test and a significance level of  $P < .05$  were employed to compare the treatment groups.

### **3. Discussion**

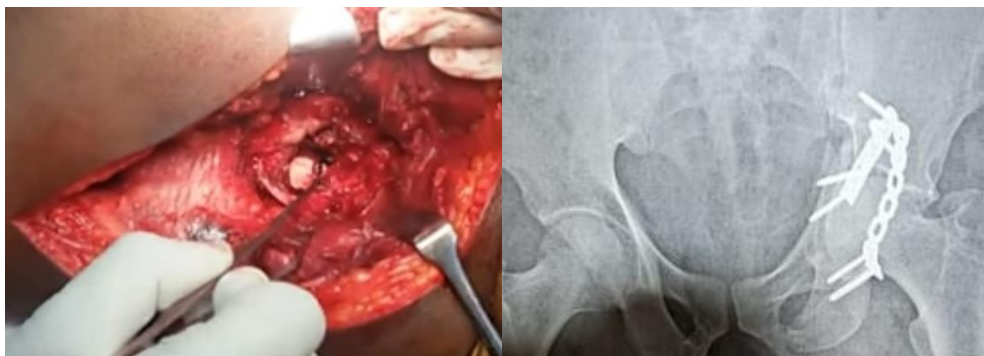
Considerable controversy exists over the optimal strategy for reducing and stabilizing transverse acetabular fractures [8]. This study did not find any statistically significant difference between groups in terms of initial displacement before surgery, Merle d'Aubigne score, and postoperative quality of reduction. According to the recent study conducted by HuTu et al. in 2017, it was shown that in cases of transverse fractures of the acetabulum, the anterior column is a straightforward pattern that requires anatomical reduction and secure fixation.



**Fig 1:** showing anterior approach with brim plate fixing transverse acetabular fracture



**Fig 2:** showing a CT for transverse acetabular fracture



**Fig 3:** Showing posterior KL approach with two posterior plates fixing transverse acetabular fracture

**Table 1. Baseline Demographic Data (N = 30)**

Variables	No.	%
Age, years	28.7 ± 6.8 (Range, 18 – 60)	
Gender		
Male	20	66.66
Female	10	33.33
Mechanism of Injury		
Motor car accident	18	60
Fall from high	10	33.33
Fall on the ground		6.66
Right	14	46.66
Left	16	53.33

There was no statistically significant difference between the studied groups as regard age, sex, Sports, Mechanism of Injury and side.

There was no statistically significant difference was found between groups regarding Initial displacement preoperatively and Postoperative quality of reduction (Chi-square test, P > 0.05).

**Table 2. radiological and clinical scores (N = 30)**

	Group (A)	Group (B)
Initial displacement	7.6 ± 4.71	7.98 ± 7.68
Postoperative quality of reduction(mm)	0.16 ± 0.21	0.17 ± 0.312
Merle d'Aubigne score	16.1 ± 2.3	15.89 ± 1.8

There was no statistically significant difference was found between groups regarding Merle d'Aubigne score at different follow-up intervals (Independent sample t test, P > 0.05).

**Table 3. complications (N = 30)**

	Group (A)	Group (B)
Local infection	2	0
Heterotropic ossification	1	1
Avascular necrosis	0	1

There was no statistically significant difference was observed between groups regarding the incidence of infection and heterotropic ossification (Chi-square test, P > 0.05) while cannot be applied in avascular necrosis.

Anatomic reduction of the anterior column fracture must be achieved before proceeding with the reduction of the posterior column and wall. The author conducted a case series study including 21 patients with transverse fractures of the acetabulum. The surgical treatment involved addressing the posterior column and wall using the KL method, resulting in successful anatomical realignment. These findings are in line with earlier research [9]. In this investigation, the fractures of the anterior column were minimized and internally corrected using an anterior technique. Successful anatomic realignment of the front part of the structure was accomplished in 20 instances. One instance was inadequately resolved due to technical limitations. The analysis demonstrated that there was no statistically significant disparity between the groups [9]. Furthermore, in comparison to the present study, Bhandari et al demonstrated that the posterior KL approach yielded better outcomes compared to the anterior approach, but this difference was not statistically significant. Ultimately, the decision was left to the surgeon's preference [10]. According to Porter et al's recent study, both methods had similar outcomes, but the KL strategy shown advantages in characteristics such as surgical duration and reduced hemorrhage [11]. Rickman et al. said that the selection of a surgical method is influenced by the pattern of the fracture. Therefore, if there is a change in fracture patterns over time, it should require a corresponding adjustment in the proportions of surgical procedures used. In addition, over the time span examined in both evaluations, there has been a gradual development of surgical techniques [2]. Surgeons have acknowledged the hazards associated with multiple or extensile methods and have improved their ability to manage intricate fractures with a single approach. The present investigation shown that there was no statistically significant disparity between the two treatments in terms of postoperative sequelae, including infection, avascular necrosis (AVN), and heterotopic ossification. The chi-square test yielded a p-value greater than 0.05. The present investigation was constrained by a small sample size, being a study conducted at a single site, and a very brief duration of follow-up. Additional comparative investigations with a larger number of participants and a longer duration of observation are necessary to validate our findings and ascertain the risk variables associated with unfavourable outcomes.

#### 4. Conclusions

Overall, the present study demonstrated that both anterior and posterior techniques yield similar results in the surgical management of transverse acetabular fractures. Both procedures were shown to be efficient in treating pure transverse acetabular fractures.

#### References

- [1] R. Judet, E. Letournel. (1974). *Les fractures du cotyle*. Paris: Masson .
- [2] M. Rickman, V. Varghese. (2017). Contemporary acetabular fracture surgery: treading water or swimming upstream? *The Bone & Joint Journal*. 99(9): 1125-1131.
- [3] M. Tannast, S. Najibi, J.M. Matta. (2012). Two to twenty-year survivorship of the hip in 810 patients with operatively treated acetabular fractures. *The Journal of Bone and Joint Surgery*. 94(17): 1559-1567.
- [4] M.L. Jimenez, M.S. Vrahas. (1997). Surgical approaches to the acetabulum. *Orthopedic Clinics*. 28(3): 419-434.
- [5] J. Daurka, P. Pastides, A. Lewis, M. Rickman, M. Bircher. (2014). Acetabular fractures in patients aged > 55 years: a systematic review of the literature. *The Bone & Joint Journal*. 96(2): 157-163.
- [6] S.K. Dailey, C.T. Phillips, J.M. Radley, M.T. Archdeacon. (2016). Achieving anatomic acetabular fracture reduction—when is the best time to operate? *Journal of orthopaedic trauma*. 30(8): 426-431.
- [7] M. Bircher, A. Lewis, S. Halder. (2006). Delays in definitive reconstruction of complex pelvic and acetabular fractures. *The Journal of Bone & Joint Surgery British Volume*. 88(9): 1137-1140.
- [8] D.O. Verbeek, J.P. van der List, J.C. Villa, D.S. Wellman, D.L. Helfet. (2017). Postoperative CT is superior for acetabular fracture reduction assessment and reliably predicts hip survivorship. *JBJS*. 99(20): 1745-1752.
- [9] T. Hu, H. Xu, C. Jiang, G. Ren, Z. An. (2017). Treatment of transverse with or without posterior wall fractures of acetabulum using a modified Smith-Petersen combined with Kocher-Langenbeck approach. *Medical Science Monitor: International Medical Journal of Experimental and Clinical Research*. 23: 2765.
- [10] M. Bhandari, J. Matta, T. Ferguson, G. Matthys. (2006). Predictors of clinical and radiological outcome in patients with fractures of the acetabulum and concomitant posterior dislocation of the hip. *The Journal of Bone & Joint Surgery British Volume*. 88(12): 1618-1624.
- [11] S.E. Porter, M.L. Graves, R.A. Maples, J. Woodall Jr, J.G. Wallace, G.V. Russell. (2011). Acetabular fracture reductions in the obese patient. *Journal of orthopaedic trauma*. 25(6): 371-377.

