



Evaluation of a mixture of xenograft with injectable platelet rich fibrin (I-PRF) around immediate dental implants in infected sockets

Atef M. Hassan¹, Samy S. El Naas²

¹Faculty of Dental Medicine, Al-Azhar University, Cairo, Boys, Egypt.

²Faculty of Dental Medicine, Al-Azhar University, Cairo, Boys, Egypt.

Abstract

The goal of the current study was to evaluate the clinical and radiographic results of a mixture of xenograft with injectable platelet rich fibrin (I-PRF) surrounding immediate dental implants placed into infected extraction sockets in the esthetic zone. A total of twelve patients with non-restorable teeth or teeth in the esthetic zone were chosen, and they were split into two equal groups at random: six patients in Group I received immediate implant placement with a jumping gap grafted using a combination of I-PRF and xenograft, and six patients in Group II received the same treatment but only xenograft. Clinically, implant stability was assessed immediately and after 6 months postoperatively using Ostell device. Radiographically, the assessment of osseointegration was conducted by bone density at the second postoperative day and six months after implant placement. Regarding the change in stability: after six months postoperatively, group I (injectable PRF + xenograft) recorded a significantly higher mean (83.83 ± 6.05) ISQ values, in comparison to (73.83 ± 5.81) in group II (Xenograft only). This difference was statistically significant ($p=0.015$). Regarding the change in bone density: the amount of increase in density after six months postoperatively, in group I (injectable PRF + xenograft) recorded a higher value (225.67 ± 81.89), in comparison to (92.67 ± 82.09) in group II (Xenograft only). This difference was statistically significant ($p=0.025$). The use of mixture of I-PRF and xenograft with immediate dental implant placement offers a new promising, safe, compatible, and effective method for managing the healing process around immediate dental implants placed into infected extraction sockets.

Keywords: I-PRF, Xenograft, Infected socket.

Full length article *Corresponding Author: Atef M. Hassan¹, e-mail: editor.j.official@gmail.com

1. Introduction

There are numerous alternatives available for the replacement of missing teeth. However, dental implants have emerged as one of the most commonly utilized biomaterials for the replacement of one or more missing teeth in recent decades. The concept of immediate implant placement involves the insertion of implants directly into freshly extracted sockets immediately following the extraction process [1]. This approach offers various potential benefits, such as reducing the need for multiple surgical procedures and shortening the overall duration of treatment. Furthermore, it may help to partially preserve bone volumes, potentially leading to favorable aesthetic outcomes and assisting in the maintenance of the bone crest. Additionally, it can contribute in achieving an ideal position for the implant from a prosthetic perspective. On the other hand, there are potential drawbacks to immediate implants, including an increased risk of infection and failures [2]. Both animal and human studies have demonstrated that the placement of immediate implants into infected post-extraction sockets is a

highly predictable procedure, yielding success rates reaching approximately 92%. However, when implants are placed immediately after tooth extraction, significant concerns arise regarding the incongruity between the alveolar walls and the implant. This incongruity is believed to have adverse implications in terms of the initial stability of the implant, the extent of osseointegration, as well as the support provided by both soft and hard tissues. [3,4]. Following the placement of implants in sites where teeth have been extracted, it is not uncommon for gaps to exist between the implants and the surrounding bony walls. Fortunately, it is possible to address these gaps while simultaneously augmenting the bone during the implantation process. Various techniques have been developed to achieve this objective. Notably, xenografts have emerged as a popular option for bone grafting due to their widespread availability and ease of processing. Xenografts offer an osteoconductive scaffold and possess a mineral composition that is comparable to that of human bone, facilitating integration with the host bone [5]. In addition to its significant function in the process of blood clotting, it is

widely acknowledged that platelets play a crucial role in the initiation and release of vital biomolecules. These biomolecules include proteins that are specific to platelets, growth factors such as platelet-derived growth factor (PDGF), factors involved in blood coagulation, molecules responsible for cell adhesion, cytokines/chemokines, and factors that promote the formation of new blood vessels. Moreover, these biomolecules possess the capability to stimulate the proliferation and activation of cells that are integral to the process of wound healing [6]. Platelet concentrates are classified as a concentrated amount of platelets derived from the autogenous blood in a small quantity of plasma, containing a substantial increase of 6-8 times in growth factors derived from blood that can subsequently impact the growth, development, and differentiation of cells, as well as aid in the healing of bones and tissues. Platelet rich fibrin (PRF) represents the next generation of platelet derivatives following platelet rich plasma (PRP). It can be prepared through a single-step process without the need for any additional substances. PRF offers a fibrin matrix which is enhanced with platelets, leukocytes, and growth factors. Among the various methods of PRF, the I-PRF is one of the most well-developed. The I-PRF procedure involves a brief period of centrifugation to create a liquid concentration of platelets, primarily consisting of liquid thrombin and fibrinogen prior to the formation of fibrin gel [7-11].

2. Patients and methods

The present investigation entailed a randomized controlled clinical trial, which comprised of patients afflicted with non-restorable tooth/teeth with chronic periapical infection that necessitated immediate implant placement. The selection of patients was conducted at the Outpatient Clinic of Oral and Maxillofacial Surgery, Faculty of Dental Medicine, Al-Azhar University, Cairo, Boys. Prior to any intervention, all participants were duly informed regarding the essence, advantages, and/or hazards associated with their involvement in the current study, and each participant provided their informed consent by signing a document. Every patient underwent a comprehensive pre-surgical preparation, which encompassed a detailed case history and a radiographic examination. The research work being presented herein was granted ethical approval by the Research Ethical Committee of the Faculty of Dental Medicine, Al-Azhar University, Cairo, Boys.

2.1 Eligibility criteria

2.1.1 Inclusion criteria

Patients having non-restorable tooth/teeth with chronic periapical lesion in the maxillary esthetic zone and the age of the participant patients ranged between 18 and 45 years including both genders.

2.1.2 Exclusion criteria

Severe bone loss or destructed extraction socket or acute suppurative infection related to the offending tooth.

2.2 Patients grouping

Patients who fulfilled the eligibility criteria were randomly divided into two groups (six patients each);

2.2.1 Group I (n=6)

Hassanan and Naas, 2023

Immediate dental implant installation and the gap between the implant and the bony socket wall grafted with a mixture of xenograft (Onegraft^R) and injectable platelet-rich fibrin (I-PRF).

2.2.2 Group II (n=6)

Immediate dental implant installation and the gap between the implant and the bony socket wall grafted with xenograft only.

2.3 Preoperative evaluation

Personal, medical, and dental history was taken from each patient. Patients were examined clinically and radiographically for the following:

2.3.1 Clinical examination

Every patient was examined at site of future implantation for the following :

1. Examination of the remaining coronal part of the tooth to be extracted .
2. Assessment of the gingiva around the tooth needed for extraction for any signs of acute inflammation .

2.3.2 Radiographic examination

Cone Beam Computed Tomography was used to evaluate the following:

1. Exact bone height and width of alveolar ridge.
2. Degree of bone resorption related to the periapical lesion.
3. Dimensions of the implant to be installed in relation to the limiting and vital structures.

2.4 Surgical procedure

2.4.1 Tooth extraction and socket preparation

- Extra oral surgical site was disinfected using Povidone-iodine 10% antiseptic solution. Then, the patient was instructed to rinse his/her mouth with Chlorhexidine gluconate mouthwash for 2 minute.
- Local anesthetic was administered and atraumatic extraction was executed.
- The extraction socket was carefully curetted to eliminate periodontal ligament or any residual infective tissue that could compromise the osseointegration.
- After socket cleaning, it was rinsed with 5 ml of a 0.2% Chlorhexidine solution followed by irrigation with sterile saline in order to remove out tissue debris from the socket. The inner surface of the socket was explored by a blunt instrument to assess its integrity.

2.4.2 Dental implant installation and grafting

According to the manufacturer instructions, sequential drilling of the osteotomy site was done. Under copious saline irrigation, a pilot drill was used to penetrate the palatal wall of the extraction socket. An osteotomy site was created in the apical third of the socket with palatal bias extending 2 to 3 mm apical to the socket base to achieve proper primary implant stability Figure (1).

- A periapical radiograph was taken to assess the pilot drill location and angulation. Then, the sequence of drilling was continued until the final drill was reached. Bone drilling was done intermittently with speed of 800-1000 rpm and torque 35 N.

- After proper osteotomy preparation, the implant fixture (Neo Biotech Co, Seoul, Korea) was seated completely within the confines of the prepared socket in a vertical plane and screwed manually to reach the maximum manual torque. Then continue with ratchet wrench to seat the implant into its final position 2-3 mm subcrestally Figure (2).
- Primary implant stability was evaluated by “Resonance Frequency Analysis (RFA) technique through using Ostell device (Osstell ISQ, Third generation, Gutenberg, Sweden). The SmartPeg was screwed into the internal thread of the implant fixture. Then, the Osstell probe was placed in close proximity to the SmartPeg and the implant primary stability recorded.
- The SmartPeg was replaced by the implant cover screw to permit enough space for grafting of the gap between the implant and the labial plate of bone. For group I, the gap was grafted with a mixture of xenograft and autogenous I-PRF. While in group II, the gap was grafted with xenograft only. Figure (3)
- After grafting, the cover screw was removed and a suitable healing abutment was screwed in to seal the socket. The height of healing abutment was selected in a way to ensure that there was no functional loading of the implant. Gingival tissue around the healing abutment was sutured with a 4.0 resorbable stitch in figure-of-eight fashion.

2.4.3 Preparation of injectable platelet rich fibrin (I-PRF) (12): Figure (4)

A sample of autologous venous blood was acquired from the patient using a sterile syringe in the absence of an anticoagulant. The complete blood was subsequently transferred to a 5 mL plain tube and subjected to centrifugation for duration of 3 minutes at a speed of 700 rpm under ambient conditions. This process led to the formation of a liquid I-PRF layer on the top of the tube, while the red blood cells settled at the bottom. Following this, the liquid form of I-PRF was extracted from the upper yellow fluid layer using a plastic syringe. The I-PRF was then introduced to the xenograft particles in a sterile kidney dish as part of the graft preparation for group I.

2.4.4 Postoperative instructions and medications

- Patients were instructed to apply frequent cold fomentations for the first 24 hours, maintain oral hygiene instructions, consume soft diets for the first postoperative day, use warm Chlorhexidine mouth wash every 6 hours from the first postoperative day for one week.
- Antibiotic [Amoxicillin 875mg + Clavulanic acid 125mg] was administered twice daily for 7 days. A non-steroidal anti-inflammatory drug [Ketorolac 10 mg] was instructed to be maintained for 5 days 3 times daily.

2.5 Postoperative assessment

2.5.1 Clinical evaluation

The secondary implant stability was assessed at 6 months postoperatively using an Ostell device as described before.

2.5.2 Radiographic evaluation

Postoperative CBCTs was taken at the second day after implantation and after six months to evaluate bone density changes around dental implant. Using Romexis software, the distance measurement tool was used for drawing rectangle at the implant sites (buccal and palatal). Then, HU measurement tool was used to generate the mean intensity values for the selected areas.

3. Results

All patients who were enrolled in the study have completed the follow up post-surgical period. In either group, all implants inserted showed an uneventful healing and proper osseointegration. The esthetic and prosthetic outcomes were highly accepted well by all patients. The mean and standard deviation of the ages of participants within group I and group II were 40.33 ± 2.25 and 32.50 ± 8.71 respectively. There was no statistical significant difference between the mean age values of the two groups ($p=0.059$).

3.1 Implant stability

As illustrated in (Table 1) and (Figure 5), the mean and standard deviation of the primary and secondary ISQ values of implants within group I were (61.83 ± 6.97) ISQ and (83.83 ± 6.05) ISQ respectively. The difference between the primary and secondary stability values in group I was statistically significant ($p=0.000$). Regarding group II, the mean and standard deviation of the primary and secondary ISQ values of implants were (59.17 ± 5.95) ISQ and (73.83 ± 5.81) ISQ respectively. The difference between the primary and secondary stability values in group II was statistically significant as well ($p=0.004$). When comparing both groups regarding the primary implant stability, the difference was statistically insignificant ($p=0.492$). In contrary, the difference in mean ISQ values after 6 months was statistically significant with higher ISQ values in group I ($p=0.015$).

3.2 Bone density

As described in (Table 2) and (Figure 6), the mean and standard deviation of bone density values recorded by CBCT around the implants immediately after implantation and at 6 months postoperatively within group I were (1887 ± 298.5) HU and (2112.67 ± 298.69) HU respectively, where the difference for both readings in group I was statistically significant ($p=0.001$). Regarding group II, the mean and standard deviation of bone density values recorded by CBCT around the implants immediately after implantation and at 6 months postoperatively were (757.17 ± 266.45) HU and (849.83 ± 321.72) HU respectively. Similarly, the difference was statistically significant ($p=0.040$). When comparing both groups regarding the bone density around dental implants, the difference was statistically significant for readings taken immediately postsurgical or after 6 months. The amount of difference in group I (injectable PRF + xenograft) recorded a higher value (225.67 ± 81.89) , in comparison to (92.67 ± 82.09) in group II (Xenograft only).

4. Discussion

Immediate implant placement is a widely accepted therapeutic approach that has demonstrated a commendable cumulative survival rate ranging from 92-100% [13].

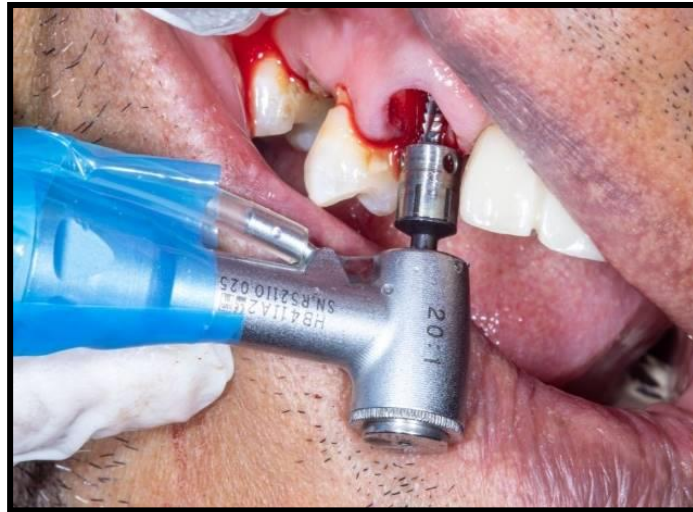

Figure 1: Use of pilot drill under copious saline irrigation

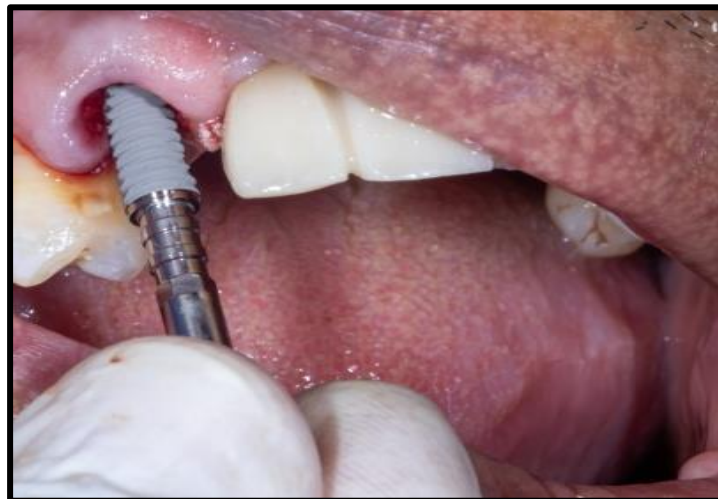

Figure 2: Dental implant manual insertion

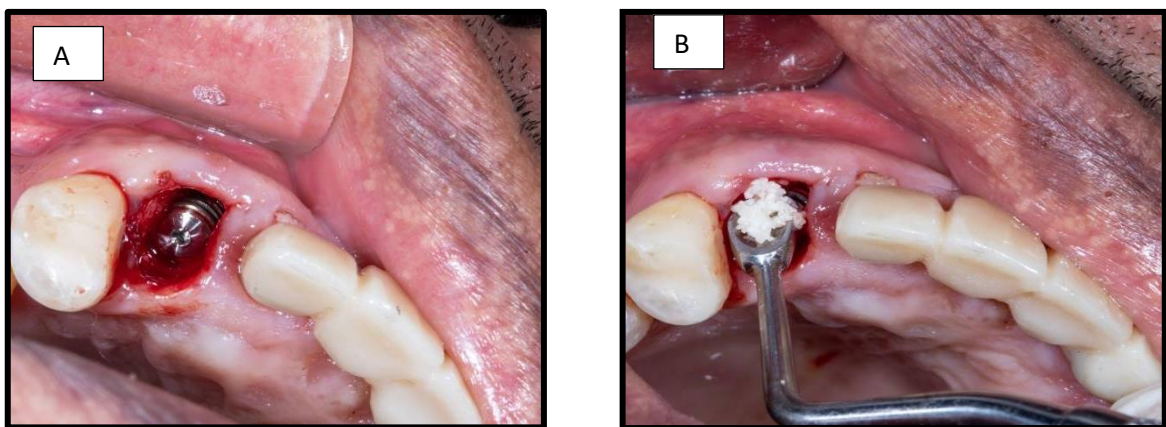


Figure 3: Immediate implantation into fresh extraction socket and grafting of the jumping gap; A: subcrestal positioning of the implant fixture with palatal bias, B: Grafting the gap between the implant fixture and the bony walls of the extraction socket with mixture of xenograft and (I-PRF)

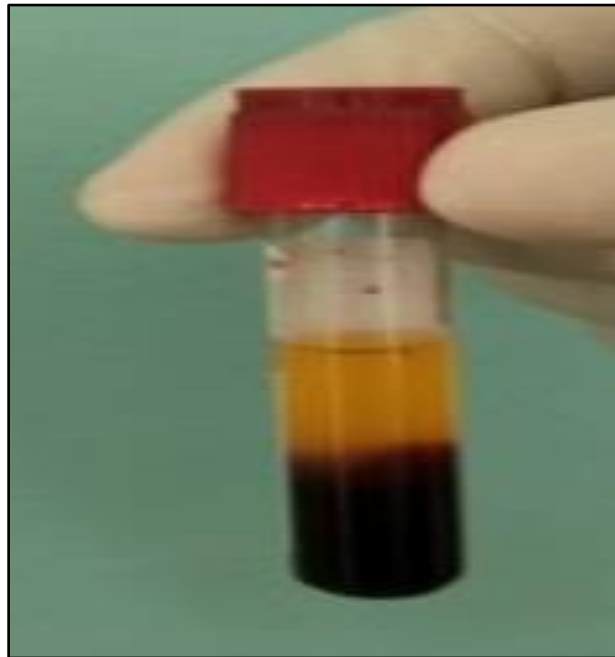

Figure 4: I-PRF

Table 1: Descriptive statistics and comparison of value of stability (ISQ) within the same group (Paired t test), and between the two groups (independent t test)

	Group I (I- PRF + xenograft)	Group II (xenograft only)	P value (between groups)
	Mean ± SD	Mean ± SD	
Immediate Postoperative	(61.83±6.97)	(59.17±5.95)	.492 ns
6 months Postoperative	(83.83±6.05)	(73.83±5.81)	.015*
P value (within each group)	.000*	.004*	

Significance level $p \leq 0.05$, * significant, ns=non-significant

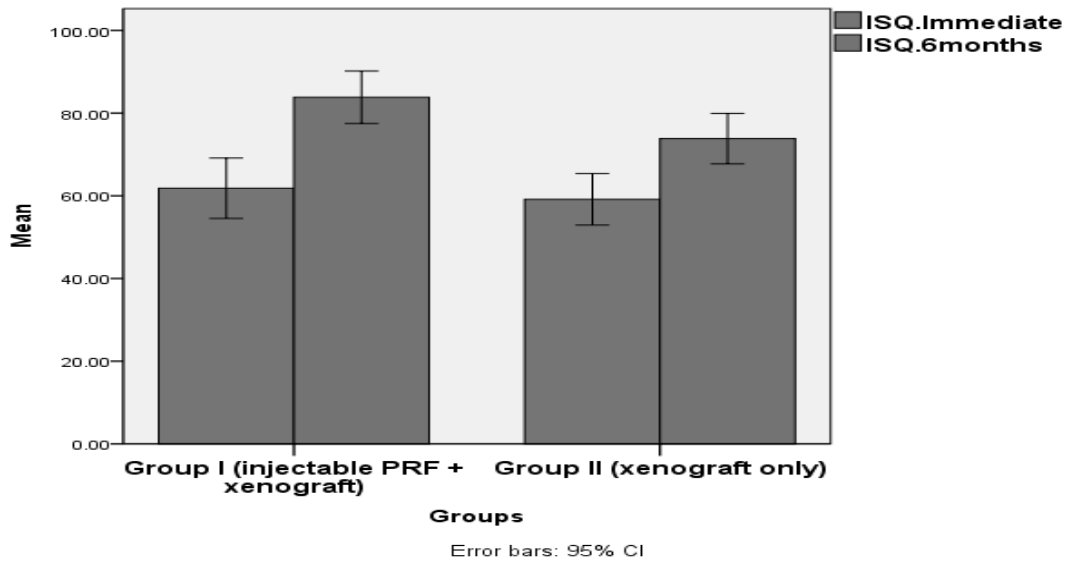


Figure 5: Bar chart illustrating mean stability (ISQ) in different observations intervals in both group

Table 2: Descriptive statistics and comparison of value of bone density within the same group

	Group I (I- PRF + xenograft)	Group II (xenograft only)	P value (between groups)
	Mean±SD	Mean±SD	
Immediate Post operative	1887.00±298.50	757.17±266.45	.000*
6 months Post operative	2112.67±298.69	849.83±321.72	.000*
P value (within each group)	.001*	.040*	
Amount of Difference	225.67±81.89	92.67±82.09	.025*

Significance level $p \leq 0.05$, *significant

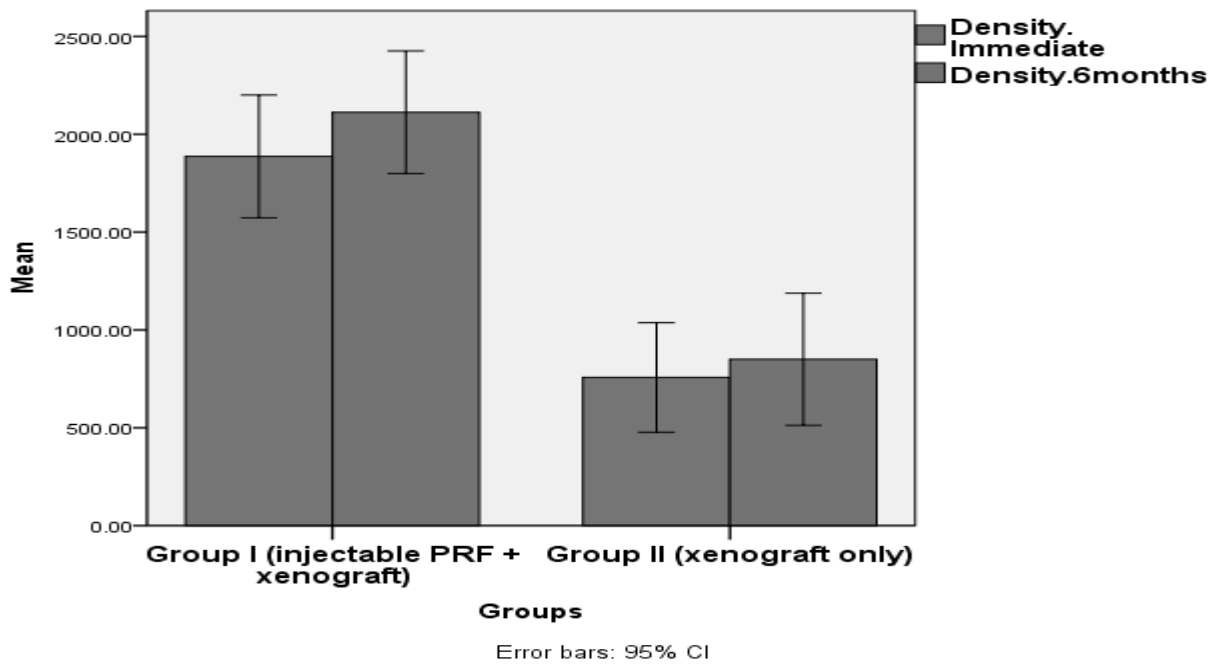


Figure 6: Bar chart illustrating mean value of bone density in both groups immediately after implantation and after 6 months

The immediate implant technique has exhibited favorable clinical outcomes characterized by a substantial survival rate and consistent maintenance of crestal bone level, comparable to the delayed implant placement. The advent of enhanced implant design and surface technology has popularized the practice of immediate implantation [14]. Patients participating in the current investigation were assigned randomly to one of two equal groups, each consisting of six patients. In group I, an immediate dental implant was surgically placed, and the space between the implant and the bony socket wall was filled with a combination of xenograft (OnegraftR) and injectable platelet-rich fibrin (I-PRF). Conversely, in group II, the gap between the implant and the bony socket wall was filled with xenograft alone. The stability of the implants was evaluated using the resonance frequency analysis (RFA) technique provided by the Osstell® device. This particular tool is widely regarded as an effective means of assessing both primary and secondary implant stability. Additionally, it is a straightforward and non-invasive diagnostic device that is commonly employed by numerous clinicians. The RFA method offers a valuable means of measuring osseointegration [15]. Compared to group II (xenograft only), group I (injectable PRF + xenograft) had much higher mean secondary implant stability values (83.83 ± 6.05) ISQ. This difference was statistically significant. These results are consistent with the evaluation of implant stability conducted by El Komi H. et al. [16] who have utilized injectable-PRF following immediate implantation. These findings suggest that injectable platelet rich fibrin used during implant surgery may contribute to improved implant durability.

Besides, CBCT is considered as a very valuable method for assessing alveolar bone quantity and quality with high efficiency, simplicity, availability and relatively low cost [17]. In the current study, CBCT was utilized to determine alveolar bone density around dental implants

immediately and 6 months post implant insertion. The bone density measured with Hounsfield units (HU) at region of interest using the Planmeca Romexis imaging software. The mean bone density in group I increased from (1887 ± 298.5) HU immediate postoperatively to (2112.67 ± 298.69) HU after 6 months. While in group II, bone density increased from (757.17 ± 266.45) HU immediate postoperatively to (849.83 ± 321.72) HU after 6 months. The difference between both groups was statistically significant. These results are consistent with Reda R. et al [18]. They examined the effects of using a combination of xenograft and I-PRF in implantation in an esthetic region as opposed to using xenograft alone. The xenograft group had a 74.83 ± 19.31 HU increase in bone density. The rise in the xenograft and I-PRF group was 154.16 ± 42.44 , with a very statistically significant difference. The development of PRF technologies, including I-PRF, has made it possible to use platelet concentrates in novel ways. It affects osteoblastic activity either in conjunction with bone grafting or independently through growth factor release. The key benefits and characteristics of I-PRF are its great potential for tissue regeneration, its capacity to regenerate tissue vascularization and, therefore, a successful dental implant, and its capacity to speed up the development of gingival and bone tissues [19]. Tarnow et al [20] demonstrated that the least amount of ridge contour alteration was produced by bone grafting into the gap during implant implantation in conjunction with a contoured healing abutment or a temporary repair. It is well known that the existence of infection can lead to the breakdown of wounded tissues as well as failure or delay in the healing process. Therefore, if urgent dental implantation is planned, it is imperative to prevent bacterial contamination and strictly control bacterial plaque in order to obtain satisfactory outcomes. Furthermore, maintaining healthy peri-implant tissue after surgery through the use of mouthwashes containing Chlorhexidine is an essential step in ensuring a

successful surgical operation and implant integration during the wound healing phase (21, 22). In the present investigation, attention was paid in order to remove diseased tissue and remaining periodontal ligaments by socket curettage following tooth extraction. A 25 mL sterile saline rinse was given after 5 ml of an aqueous 0.2% Chlorhexidine digluconate solution was used to irrigate the socket. Obviously, the study only included individuals who could follow instructions for maintaining proper dental hygiene and who had good oral hygiene.

5. Conclusions

A novel, safe, compatible, and efficient technique for controlling the healing process surrounding immediate dental implants inserted into contaminated extraction sockets is the use of a combination of I-PRF and xenograft in conjunction with immediate dental implant insertion.

Declaration of Interests

No financial conflicts of interest are to be declared. The study was self-funded by the investigators.

References

- [1] C. Hämmerle, S.T. Chen, T.G. Wilson Jr. (2004). Consensus statements and recommended clinical procedures regarding the placement of implants in extraction sockets. *The International Journal of Oral & Maxillofacial Implants*. 19(Suppl): 26-28.
- [2] M. Esposito, M.G. Grusovin, I.P. Polyzos, P. Felice, H.V. Worthington. (2010). Interventions for replacing missing teeth: dental implants in fresh extraction sockets (immediate, immediate-delayed and delayed implants). *Cochrane Database of Systematic Reviews*. (9).
- [3] S.-W. Chang, S.-Y. Shin, J.-R. Hong, S.-M. Yang, H.-M. Yoo, D.-S. Park, T.-S. Oh, S.-B. Kye. (2009). Immediate implant placement into infected and noninfected extraction sockets: a pilot study. *Oral Surgery, Oral Medicine, Oral Pathology, Oral Radiology, and Endodontology*. 107(2): 197-203.
- [4] R. Crespi, P. Cappare, E. Gherlone, G.E. Romanos. (2007). Immediate occlusal loading of implants placed in fresh sockets after tooth extraction. *International Journal of Oral & Maxillofacial Implants*. 22(6).
- [5] M. Retzepi, N. Donos. (2010). Guided bone regeneration: biological principle and therapeutic applications. *Clinical oral implants research*. 21(6): 567-576.
- [6] L. He, Y. Lin, X. Hu, Y. Zhang, H. Wu. (2009). A comparative study of platelet-rich fibrin (PRF) and platelet-rich plasma (PRP) on the effect of proliferation and differentiation of rat osteoblasts in vitro. *Oral Surgery, Oral Medicine, Oral Pathology, Oral Radiology, and Endodontology*. 108(5): 707-713.
- [7] R.E. Marx. (2001). Platelet-rich plasma (PRP): what is PRP and what is not PRP? *Implant dentistry*. 10(4): 225-228.
- [8] D.M. Dohan, J. Choukroun, A. Diss, S.L. Dohan, A.J. Dohan, J. Mouhyi, B. Gogly. (2006). Platelet-rich fibrin (PRF): a second-generation platelet concentrate. Part I: technological concepts and evolution. *Oral Surgery, Oral Medicine, Oral Pathology, Oral Radiology, and Endodontology*. 101(3): e37-e44.
- [9] S. Ali, S.A. Bakry, H. Abd-Elhakam. (2015). Platelet-rich fibrin in maxillary sinus augmentation: a systematic review. *Journal of Oral Implantology*. 41(6): 746-753.
- [10] F.J. Strauss, A. Stähli, R. Gruber. (2018). The use of platelet-rich fibrin to enhance the outcomes of implant therapy: a systematic review. *Clinical oral implants research*. 29: 6-19.
- [11] S. Kalash, N. Aboelsaad, M. Shokry, J. Choukroun. (2017). The efficiency of using advanced PRF-xenograft mixture around immediate implants in the esthetic zone: a randomized controlled clinical trial. *Journal of Osseointegration*. 9(4): 317-22.
- [12] R.J. Miron, M. Fujioka-Kobayashi, M. Hernandez, U. Kandalam, Y. Zhang, S. Ghanaati, J. Choukroun. (2017). Injectable platelet rich fibrin (i-PRF): opportunities in regenerative dentistry? *Clinical oral investigations*. 21: 2619-2627.
- [13] A.E. Bianchi, F. Sanfilippo. (2004). Single-tooth replacement by immediate implant and connective tissue graft: a 1–9-year clinical evaluation. *Clinical oral implants research*. 15(3): 269-277.
- [14] C.T. Lee, T.S. Chiu, S.K. Chuang, D. Tarnow, J. Stoupe. (2014). Alterations of the bone dimension following immediate implant placement into extraction socket: systematic review and meta-analysis. *Journal of clinical periodontology*. 41(9): 914-926.
- [15] M.M. Bornstein, C.N. Hart, S.A. Halbritter, D. Morton, D. Buser. (2009). Early loading of nonsubmerged titanium implants with a chemically modified sand-blasted and acid-etched surface: 6-month results of a prospective case series study in the posterior mandible focusing on peri-implant crestal bone changes and implant stability quotient (ISQ) values. *Clinical implant dentistry and related research*. 11(4): 338-347.
- [16] A. El Komi, H. Abd Elkarim. (2021). Clinical outcome of an injectable platelet-rich fibrin and platelet-rich plasma on immediate dental implant. *Al-Azhar Journal of Dental Science*. 24(4): 417-424.
- [17] R. Jacobs, B. Salmon, M. Codari, B. Hassan, M.M. Bornstein. (2018). Cone beam computed tomography in implant dentistry: recommendations for clinical use. *BMC Oral Health*. 18(1): 1-16.
- [18] R.M. Reda, A. Gawish, M. Shafik, M. Ghoniem. (2021). Evaluation of Injectable Platelet Rich Fibrin (I-PRF) with Bone graft around Immediate Dental Implant in Esthetic Zone. *Al-Azhar Dental Journal for Girls*. 8(3-B): 471-482.
- [19] R.M. Reda, A. Gawish, M. Shafik, M. Ghoniem. (2021). Evaluation of Injectable Platelet Rich Fibrin (I-PRF) with Bone graft around Immediate Dental Implant in Esthetic Zone. *Al-Azhar Dental Journal for Girls*. 8(3-B): 471-482.
- [20] D.P. Tarnow, S.J. Chu, M.A. Salama, C.F. J Stappert, H. Salama, D.A. Garber, G.O. Sarnachiaro, E. Sarnachiaro, S. Luis Gotta, H. Saito. (2014). Flapless postextraction socket implant

placement in the esthetic zone: part 1. The effect of bone grafting and/or provisional restoration on facial-palatal ridge dimensional change-a retrospective cohort study. *International Journal of Periodontics & Restorative Dentistry*. 34(3).

- [21] T. Maheswary, A. Nurul, B. Fauzi. (2021). The Insights of Microbes' Roles in Wound Healing: A Comprehensive Review. *Pharmaceutics*. 13:981-1003.
- [22] K. Atallah, L. Chee, L. Peng. (2008). Implant placement in extraction sockets: a short review of the literature and presentation of a series of three cases. *Journal of Oral Implantology*. 34: 97-106.