



# Optic Nerve Sheath Diameter as a marker for increased ICP and Disease Severity in Acute Ischemic Stroke

*Asmaa Sabbah<sup>1</sup>, Manal Mahmoud Elkattan<sup>1</sup>, Dalia M Labib<sup>1</sup>, Nancy Samir Wahdan<sup>1\*</sup>, Al-Shaimaa Mahmoud Aboulfotoh<sup>1</sup>*

<sup>1</sup>Department of Neurology, Faculty of Medicine, Cairo University, Egypt.

## Abstract

Increased Intracranial Pressure (ICP) can have serious consequences related to vascular and cerebrospinal fluid (CSF) dynamic changes within the optic nerve sheath. Transorbital Sonography (TOS) has emerged as a promising assessment tool to detect pre-clinical dilatation of the optic nerve sheath diameter (ONSD). Assessment of ONSD as a marker of brain oedema by TOS in acute ischemic stroke (AIS) patients (within the first week of stroke). This case control study, included two groups; ischemic stroke patients' group: a total of 60 patients -within the first week of the stroke- 30 acute ischemic atherosclerotic stroke patients, and 30 acute cardioembolic stroke patients, and the second group; included 30 age and sex matched normal healthy control subjects. All underwent clinical assessment and TOS, for measuring ONSD. There was a significant difference between AIS patients and control subjects regarding ONSD in both sides (P value < 0.001\*\*\*), AIS patients showed a higher ONSD at ipsilateral side of infraction than the contralateral side with a significant difference (P value < 0.001\*\*\*). We observed increase in ONSD in diabetic patients with statistical significance. There was a statistically significant positive correlation between ONSD and National Institute of Health stroke scale score (NIHSS) score, Modified Rankin Scale (mRS). ONSD assessment in AIS patients can predict increased ICP and indicate stroke severity.

**Keywords:** Acute ischemic stroke, Increased intracranial pressure, Optic nerve sheath diameter, Transorbital ultrasound.

**Full length article** \*Corresponding Author, e-mail: [Nancy.wahdan@gmail.com](mailto:Nancy.wahdan@gmail.com)

## 1. Introduction

Ischemic stroke accounts for nearly 76% of all stroke cases, malignant brain edema has a mortality rate as high as 80% [1]. Post ischemic stroke cerebral edema is a serious complication. It causes an increase in intracranial pressure, rapid deterioration of neurological symptoms, and formation of cerebral hernia, and represented an important risk factor for adverse outcomes after stroke [2]. The optic nerve is mostly assessed by ophthalmoscopy and MRI but recently the role of optic nerve ultrasound in the detection of increased ICP has been widely investigated in brain injuries, intracranial hemorrhage, hydrocephalus, brain tumors, and idiopathic intracranial hypertension [3]. The aim of this work is to evaluate the association of optic nerve sheath diameter (ONSD) within the first week of the stroke and to correlate it with the severity of the stroke according to NIHSS and mRS and to determine whether ONSD was associated with extra and transcranial large artery stenosis (LAS).

## 2. Subjects and Methods

### 2.1. Study design

This is a case-control, single-centre, acute ischemic stroke patients and controls were recruited from Kasr Al Ainy Stroke Unit, (Cairo University Hospitals) in the period from January 2020 till January 2021.

### 2.2. Patients and controls

Our study included 90 subjects; that were divided into 2 groups; 60 patients with acute ischemic stroke within the first week of the stroke and 30 age and sex matched normal healthy control subjects. Patients were further divided into two subgroups: Group I: 30 acute ischemic atherosclerotic stroke patients. Group II: 30 acute cardioembolic stroke patients. Inclusion criteria were as follows: age range 18–75 years and both sexes, while the exclusion criteria for patients were subarachnoid, subdural, extradural, intracerebral haemorrhage, orbital trauma, ruptured globe, lid problems, keratoprosthetics, corneal opacities, dense cataracts, and glaucoma.

### 2.3. Data collection

Demographic characteristics and full medical history were taken with special concern to vascular risk factors including diabetes mellitus (DM), hypertension (HTN), ischemic heart disease (IHD), previous stroke, smoking, drug abuse and when the patient was last seen normal. All participants were subjected to general examination, neurological, neurovascular examination, NIHSS and mRS, Transthoracic Echocardiography using Phillips S72 Omni ultrasound equipment [4-5]. Extracranial and transcranial color-coded mode duplex sonography using Phillips model IU22 machine; Extracranial duplex study by high-frequency (7- to 10-MHz) linear array transducer to scan the carotid from the most proximal common carotid artery (CCA) to the internal carotid artery (ICA) as far as the mandible permitted. We used the examination protocol and interpretation according to the criteria published by Society of Radiologists in Ultrasound North American Symptomatic Carotid Endarterectomy Trial, NASCET criteria were used for stenosis calculations [6-7]. Transcranial color-coded duplex ultrasonography was performed using a 2 - 5 MHz phased-array transducer through the temporal window to assess both right and left middle cerebral arteries (MCAs), anterior cerebral arteries (ACAs), posterior cerebral arteries (PCAs), Mean Velocity (MV) & Pulsatility Index (PI). Diagnosis of intracranial stenosis interpreted according to the internationally published criteria [8]. TOS using linear transducer probe: all subjects were examined in supine position with the head and the upper part of the body elevated to 20–30 degree to avoid any pressure on the eye and were asked to keep their eyes in a neutral position, trying to suppress eye movements. The mechanical index was reduced to 0.2 for safety reasons. The probe was placed on the temporal part of the closed upper eyelid and a thick layer of ultrasound gel was applied. The subject was instructed to maintain his/her gaze at midline to align the optic nerve along the probe. The anterior part of the optic nerve was depicted in an axial plane with the papilla and the optic nerve shown longitudinally. ONSD was assessed 3 mm behind the papilla. The distance between the external borders of the hyperechogenic area surrounding the optic nerve was quantified to measure the ONSD, by marking the internal borders.

### 2.4. Statistical analysis

Data were coded and entered using the statistical package SPSS (Statistical Package for the Social Sciences) version 25. Data was summarized using mean, standard deviation, median, minimum, and maximum in quantitative data and using frequency (count) and relative frequency (percentage) for categorical data. Comparisons between quantitative variables were done using the non-parametric Kruskal-Wallis and Mann-Whitney tests [9]. Correlations between quantitative variables were done using Spearman correlation coefficient [10]. P-values less than 0.05 were considered as statistically significant.

## 3. Results and Discussion

### 3.1. Demographic data and Clinical assessment scales

The age of the selected patients ranged from (31-74 years) with mean  $\pm$ SD (58.22  $\pm$  11.97) while the age of control subjects ranged from (34-60 years) with mean  $\pm$ SD (47.73  $\pm$  7.53). In Patient's group: 39 were males (65%) and 21 were females (35%), while in control subjects there were 20 males (66.7%) and 10 females (33.3%). Patients' NIHSS ranged from (2 to 19) with mean of 10.28  $\pm$  4.56 SD. Patients' mRS score ranged from (1 to 5) with mean of 3  $\pm$  0.99. Thirty-nine patients (65%) had right sided infarction while 21 patients (35%) had infarction at left side. All Demographic data and Clinical assessment scales were demonstrated Table 1 & 2.

### 3.2. Cerebral arterial duplex and TOS

Forty patients had abnormal duplex finding either intracranial or extracranial (66.7%), 20 patients had normal duplex (33.3%), while all control subjects had a normal duplex. Extracranial and the transcranial degree of stenosis are illustrated in Table 3. The mean of RT ONSD in patient groups was 0.72  $\pm$  0.10 and the mean of LT ONSD was 0.71  $\pm$  0.11, while the mean of ON was 0.34  $\pm$  0.04 SD on both sides.

### 3.3. Comparative analysis

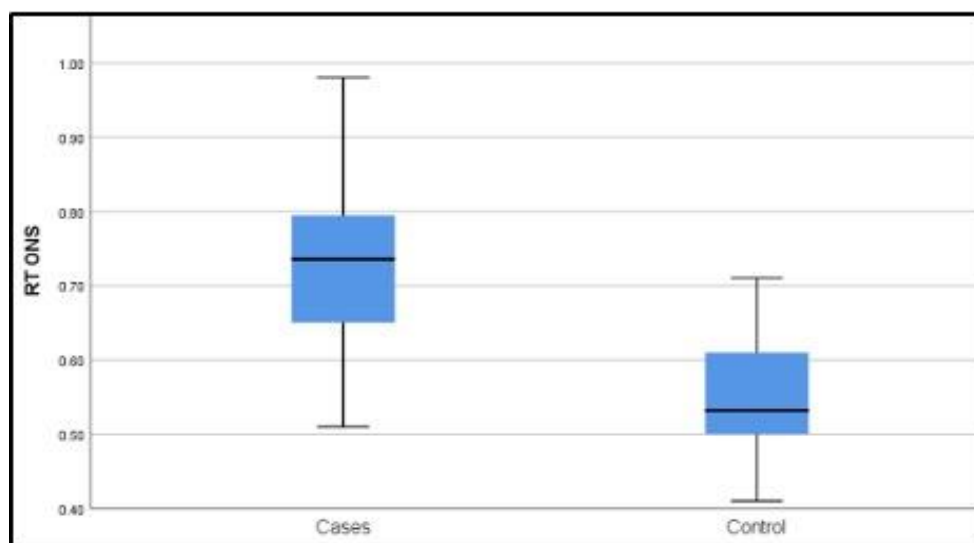
Stroke patients had increased ONSD in both sides when compared with control subjects with high statistical significance difference (P value < 0.001) (Figures 1 & 2). Moreover, ONSD was increased and higher at ipsilateral side of infarction when compared to the non-infarcted contralateral side and this difference was statistically highly significant (p value < 0.001). We noticed increase in ONSD in both side in patients with severe intracranial arteries stenosis, and there was more increase in right ONSD with statistical significance (P value = 0.038). According to influence of comorbidities on our results, diabetic patients developed increase in ONSD at ipsilateral side of infarction with statistical significance (P value = 0.024), we observed increase in right and left ONSD in diabetic patients with statistical significance p value = 0.039, 0.030 respectively (Figures 3 & 4), yet other comorbidities such as hypertension, smoking, cardiac problems, and history of previous stroke did not show any significant difference in ONSD. There was no significant difference between subgroups of patients in ONSD. No statistical significance was detected when we compared ONSD with degree of stenosis of extracranial arteries.

### 3.4. Correlative results

A significant positive correlation was found between NIHSS and ONSD with P value = < 0.001\*\*\* on the right eye and P = 0.001\*\*\* on the left eye. Also, a statistically significant positive correlation was found between mRS score and ONSD with P value = < 0.001 on the right eye and P value = 0.006 on the left eye. Moreover, Patients with high NIHSS had increased ONSD at same side of infarction with positive statistical significance p value = < 0.001\*\*\*. Patients with high mRS had increased ONSD at same side of infarction with positive statistical significance p value = < 0.001\*\*\*. Quantifying the severity and evolution of cerebral edema after stroke plays an important but challenging role in clinical studies [11]. In this case control study, we aimed to predict cerebral oedema and increased ICP in patients with acute ischemic stroke. Therefore, TOS was used as a screening tool of the ONSD in patients with acute ischemic stroke.

Clinical characteristics in our study; age, gender, smoking, HTN and previous history of stroke were not risk factors for the occurrence of post stroke increase ICP, while pre-existing DM showed observed increase in right and left ONSD as a clue of increased ICP in acute ischemic stroke patients. Donertas et al., (2019) also found that ONSD increased in diabetic patients when compared with healthy control subjects [12]. This might be attributed to brain edema that is associated with hyperglycemia and the result in increase of the ICP thus ONSD reflect the changes in intracranial pressure that results from brain edema. In this study, neuro-sonological data showed, intracranial and extracranial duplex had abnormal findings in 40 patients (66.7%). Twelve patients out of 30 acute ischemic atherosclerotic stroke patients (group I) had severe intracranial stenosis and 6 patients had severe degree of extracranial stenosis, while 10 patients out of 30 acute cardioembolic stroke patients (group II) had severe intracranial stenosis and only 1 patient had severe degree of extracranial stenosis. In our study, it was observed that there was no statistically significant association between ONSD and the degree of stenosis of extracranial arteries. However, we found statistically significant increase in ONSD in patients with severe intracranial stenosis. Contrary to what we found, Komut et al., (2021) observed a lower ONSD in patients with severe ICA stenosis than in patients without or with mild stenosis, suggesting that ONSD decreases when ICA stenosis grade increases [13]. This controversy can be explained by fact that arterial blood flow to the optic nerve is supplied by the ophthalmic artery, even in the presence of the common anatomical variations. Ophthalmic artery originates from the supra-clinoid segment of the ICA and enters the orbit through the optic canal. In some instances, the ophthalmic artery originates from the middle meningeal artery. In rare cases, with a persistent dorsal ophthalmic artery, it originates from the cavernous segment of the ICA and can also reach the orbit via the superior orbital fissure. Therefore, in cases of ICA stenosis or occlusion that cause significant hemodynamic changes downstream, changes are to be expected in the ophthalmic artery blood flow, and the optic nerve arterial flow may be directly affected [14]. Comparing ONSD between acute stroke patients (within

first 7 days of the onset of stroke) and control individuals, our results showed that there is highly significant increase in ONSD in both eyes of patient's group (P value < 0.001). Furthermore, ONSD was increased and higher at the ipsilateral side of infarction than contralateral side. In agreement with our result, Kozaci et al., (2020) observed that optic nerve sheath diameter increases in acute ischemic stroke [15]. Ischemia causes brain damage by activating the ischemic cascade and results in brain edema. The abnormal accumulation of fluid causes an increase in brain volume and elevation of intracranial pressure (ICP) because of an enclosed rigid skull and in turn increase ONSD. Chen et al., (2019) and Lee et al., (2020) also found positive correlations between ONSD and ICP following acute ischemic stroke [16-17]. ONSD decreases immediately following a reduction in CSF pressure. It is explained by that, the optic nerve is a part of the central nervous system, and is surrounded by the dura, arachnoid and pia mater; the optic nerve sheath is the continuation of the dura mater, and the subarachnoid space contains CSF. Thus, any increase in the ICP in the subarachnoid space is transferred to the fluid in the optic nerve surrounding it. Yet, Školoudík et al., (2011) found that ONSD enlargement was not detected in any acute ischemic stroke patients or healthy volunteers, but it was detected in patients with acute intracerebral hemorrhage [18]. As regards, clinical severity and disability data, our results demonstrated that there was a positive correlation between the high grades of mRS score, NIHSS and the consistency of ONSD as a proxy of increased ICP. This could be explained that ischemic stroke resulting from large size of infarction, is associated with more edema around infarcted area and much more increase in intracranial pressure and more increase in ONSD. Our results were in accordance with Yüzbaşıoğlu et al., (2018) who observed that ONSD of the patient with acute ischemic stroke was determined to be significantly higher than that of the control group and noticed positive correlation between the NIHSS score of the patients reflecting stroke severity and the ONSD [19]. While on the contrary, German Stroke Study Collaboration in (2004) found no relations between NIHSS score and ONSD [20].



**Figure 1:** RT Optic nerve sheath diameter in patients and control subjects.

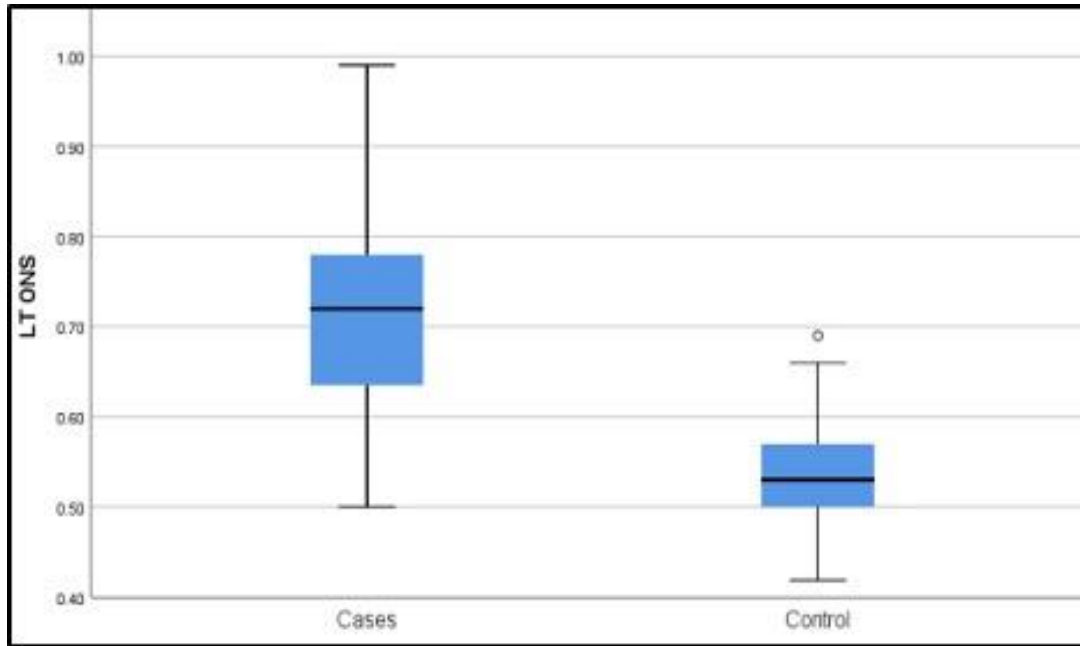


Figure 2: LT Optic nerve sheath diameter in patients and control subjects.

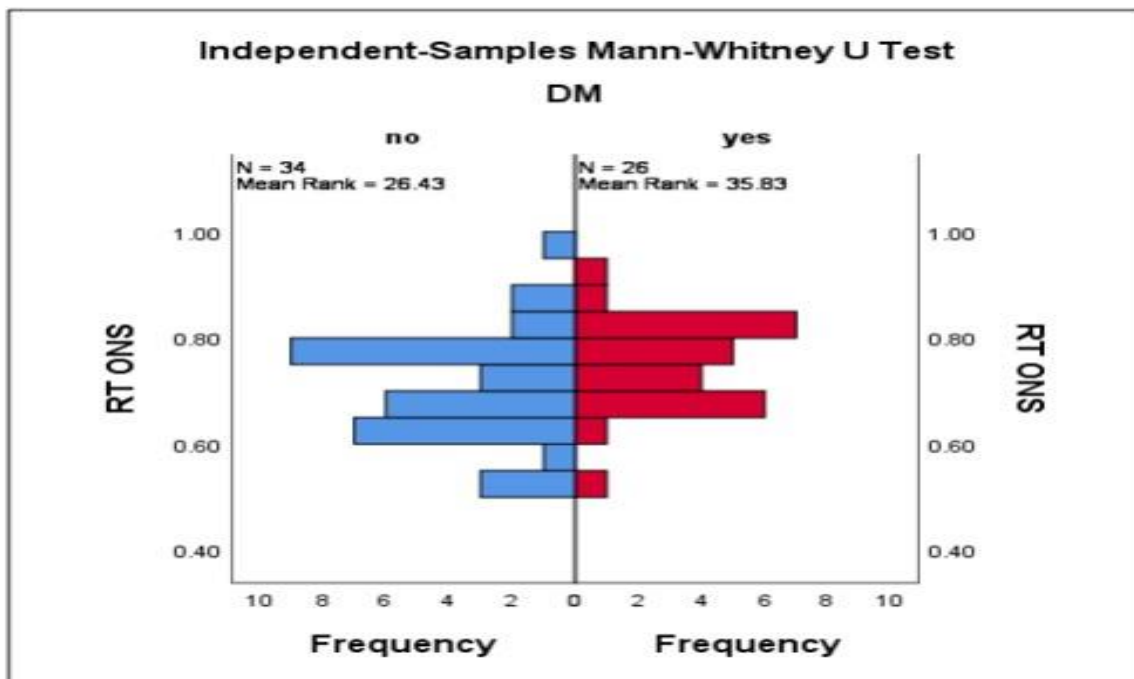


Figure 3: Comparisons between RT ONSD in diabetics and non-diabetic stroke patients.

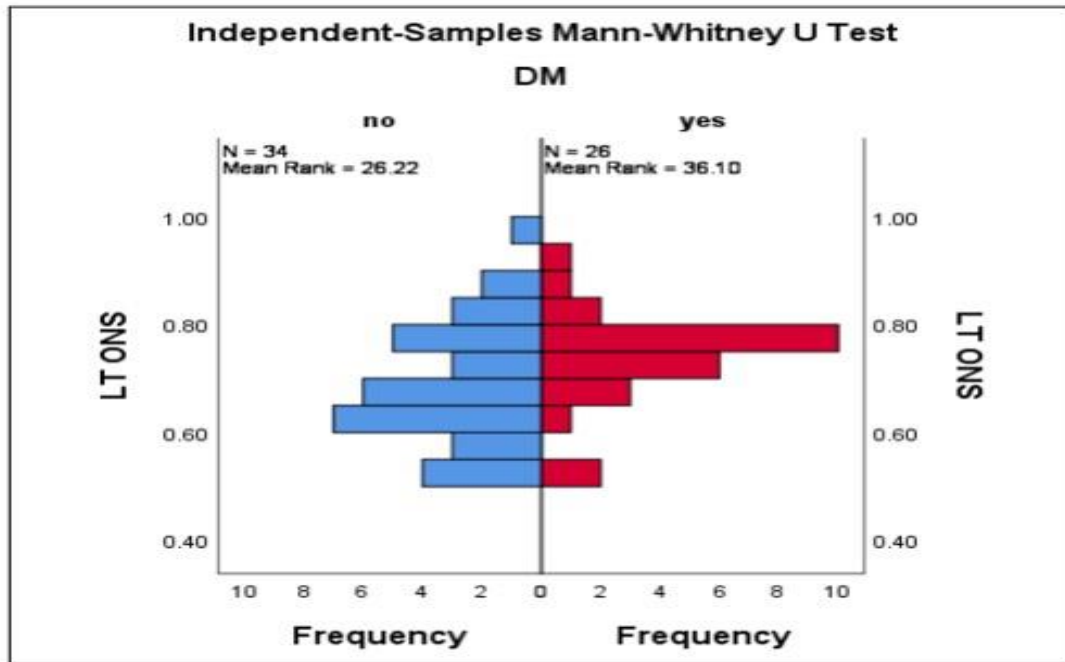


Figure 4: Comparisons between LT ONSD in diabetics and non-diabetic stroke patients

Table 1: Co-morbidities and Risk factors in patients and control groups.

		Group			
		Group A		Group B	
		Count	%	Count	%
HTN	yes	35	58.3%	15	50.0%
	no	25	41.7%	15	50.0%
DM	yes	26	43.3%	3	10.0%
	no	34	56.7%	27	90.0%
Cardiac	yes	35	58.3%	0	0.0%
	no	25	41.7%	30	100.0%
Smoking	yes	37	61.7%	15	50.0%
	no	23	38.3%	15	50.0%
Previous stroke	yes	19	31.7%	0	0.0%
	no	41	68.3%	30	100.0%
Hyperuricemia	yes	12	20.0%	2	6.7%
	no	48	80.0%	28	93.3%
Dyslipidemia	Yes	34	56.7%	5	16.7%
	no	26	43.3%	25	83.3%

**Table 2:** Co-morbidities, risk factors and Clinical Assessment Scales in subgroups of stroke patients.

Risk Factor		Group I		Group II	
		Count	%	Count	%
HTN	Yes	14	46.6%	19	63.33%
	No	16	53.3%	11	36.66%
DM	yes	14	46.6%	12	40%
	No	16	53.3%	18	60%
Cardiac	yes	6	20%	29	96.6%
	No	24	80%	1	3.3%
Smoking	yes	19	63.33%	18	60%
	No	11	36.66%	12	40%
Previous stroke	yes	10	33.3%	9	30%
	No	20	66.66%	21	70%
Hyperuricemia	yes	8	26.66%	4	13.33%
	No	22	73.33%	26	86.66%
Dyslipidemia	Yes	22	73.33%	12	40%
	No	8	26.66%	18	60%
NIHSS Score	0-5	6	20%	3	10%
	5-10	12	40%	9	30%
	10-15	8	26.6%	13	43.33%
	15-20	4	13.3%	5	16.66%
mRS	1	4	13.33%	1	3.33%
	2	6	20%	6	20%
	3	10	33.33%	13	43.33%
	4	8	26.66%	10	33.33%
	5	2	6.6%	0	0%

**Table 3:** Extracranial and the transcranial duplex findings in subgroups of stroke patients.

		Group I		Group II	
		Count	%	Count	%
Extracranial arterial stenosis	no	16	53.3%	25	83.3%
	mild	3	10.0%	0	0.0%
	moderate	5	16.7%	4	13.3%
	severe	6	20.0%	1	3.3%
Intracranial arterial stenosis	no	8	26.7%	17	56.7%
	moderate	10	33.3%	3	10.0%
	severe	12	40.0%	10	33.3%

#### 4. Conclusions

TSO has a significant role in early capture of post stroke increase ICP. ONSD, is a strong predictor of cerebral oedema in patients with acute ischemic stroke and severity assessment. ONSD is a quick, easy, cheap, and noninvasive bedside measurement method that can be a useful tool in evaluation of increase ICP in patients with acute ischemic stroke.

#### Declarations

##### Ethics approval and consent to participate

Informed oral consents were obtained from all patients after explaining the procedures of blood sampling and ultrasonography assessment, the benefits, and the possible risk of our study (apart from expected pain associated with obtaining the blood sample, no other risks were expected). The study protocol was approved by Research Committee of Neurology Department, Cairo University and the research ethics committee (REC) of Faculty of Medicine, Cairo University. The REC of Faculty of Medicine, Cairo University approved oral informed consent. Approved oral consent; as all patients were not exposed to any peculiar invasive technique, all stroke patients already get duplex study -extracranial and transcranial-as routine stroke work up, so TOS was added after taking oral consent from patients. A conduct that was approved by REC. The study was performed in accordance with the ethical standards as laid down in the 1964 Declaration of Helsinki and its later amendments.

##### Consent for publication

Not Applicable

##### Conflict of interest

No conflict of interest

##### Availability of data and materials

The datasets used and/or analysed during the current study are available from the corresponding author on reasonable request.

##### Competing interests

The authors declare that they have no competing interests.

##### Funding

No funding source to declare.

##### Authors' contributions

AS had role in the study methodology, patient selection, manuscript writing and correspondence. MME had role in the study methodology, implementation, communicating with the ethical committee and statistical analysis of the results of the study. DML, had role in patient enrollment, statistical analysis of the results of the study, reviewing the manuscript, doing revisions. NSW had role in selecting patients and including them in the study, performing clinical assessment and clinical scores, writing parts of the manuscript. AMA had role in performing the duplex; extracranial, TCD and transorbital ultrasound. All authors read and approved the final manuscript.

#### Acknowledgements

Not applicable

#### References

- [1] L. D. Deng, L. Qi, Q. Suo, S. J. Wu, M. Mamtilahun, R. B. Shi, Z. Liu, J. F. Sun, Y. H. Tang, Z. J. Zhang, G. Y. Yang, J. X. Wang. (2022). Transcranial focused ultrasound stimulation reduces vasogenic edema after middle cerebral artery occlusion in mice. *Neural Regeneration Research*. 17 (9): e2058-e2063.
- [2] Y. Gu, C. Zhou, Z. Piao, H. Yuan, H. Jiang, H. Wei, Y. Zhou, G. Nan, X. Ji. (2022). Cerebral edema after ischemic stroke: Pathophysiology and underlying mechanisms. *Frontiers in Neuroscience*. 16 (1): e988283.
- [3] E. A. Tawfik, F. O. Walker, M. S. Cartwright. (2015). Neuromuscular ultrasound of cranial nerves. *Journal of Clinical Neurology*. 11 (2): e109-e121.
- [4] V. Caso, M. Paciaroni, M. Venti, F. Palmerini, G. Silvestrelli, P. Milia, S. Biagini, G. Agnelli. (2007). Determinants of outcome in patients eligible for thrombolysis for ischemic stroke. *Vascular Health and Risk Management*. 3 (5): e749-e754.
- [5] A. I. Qureshi, S. A. Chaudhry, B. L. Sapkota, G. J. Rodriguez, M. F. K. Suri. (2012). Discharge destination as a surrogate for Modified Rankin Scale defined outcomes at 3-and 12-months poststroke among stroke survivors. *Archives of physical medicine and rehabilitation*. 93 (8): e1408-e1413.
- [6] E. G. Grant, C. B. Benson, G. L. Moneta, A. V. Alexandrov, J. D. Baker, E. I. Bluth, B. I. Carroll, M. Eliasziw, J. Gocke, B. S. Hertzberg, S. Katanick, L. Needleman, J. Pellerito, J. f. Polak, K. S. Rholl, D. L. Wooster, R. E. Zierler. (2003). Carotid artery stenosis: gray-scale and Doppler US diagnosis—Society of Radiologists in Ultrasound Consensus Conference. *Radiology*. 229 (2): e340-e346.
- [7] G. G. Ferguson, M. Eliasziw, H. W. Barr, G. P. Clagett, R. W. Barnes, M. C. Wallace, D. W. Taylor, R. B. Haynes, J. W. Finan, V. C. Hachinski, H. J. Barnett. (1999). The North American symptomatic carotid endarterectomy trial: surgical results in 1415 patients. *Stroke*. 30 (9): e1751-e1758.
- [8] K. S. Wong, P. W. Ng, A. Tang, R. Liu, V. Yeung, B. Tomlinson. B. (2007). Prevalence of asymptomatic intracranial atherosclerosis in high-risk patients. *Neurology*. 68 (23): e2035-e2038.
- [9] Y. H. Chan. (2003). *Biostatistics 102: quantitative data—parametric & non-parametric tests*. blood Press. 44 (08): e391-e396.
- [10] Y. H. Chan. (2003). *Biostatistics 104: correlational analysis*. *Singapore Medical Journal*. 44 (12): e614-e619.

- [11] A. Kumar, Y. Chen, A. Corbin, A. Hamzehloo, A. Abedini, Z. Vardar, G. Carey, K. Bhatia, L. Heitsch, J. J. Derakhshan, J. M. Lee, R. Dhar. (2022). Automated measurement of net water uptake from baseline and follow-up CTs in patients with large vessel occlusion stroke. *Frontiers in Neurology*. 13 (1): e898728.
- [12] E. Erol, N. Kozaci, M. Avci. (2022). The measurement of ultrasonographic optic nerve sheath diameter in patients with hyperglycemia. *Hong Kong Journal of Emergency Medicine*. 29 (3): e137-e143.
- [13] E. Komut, M. Murat, M. Büyüksireci, S. Komut, N. Kozaci, N. (2021). Relationship between internal carotid artery stenosis grade and optic nerve sheath diameter measured by transorbital ultrasonography. *Journal of Clinical Ultrasound*. 49 (7): e724-e730.
- [14] A. Michalinos, S. Zogana, E. Kotsiomititis, A. Mazarakis, T. Troupis. (2015). Anatomy of the ophthalmic artery: a review concerning its modern surgical and clinical applications. *Anatomy Research International*. 1155 (10): e1-e8.
- [15] N. Kozaci, M. Avci, G. Caliskan, S. Yuksel. (2020). Variability of optic nerve sheath diameter in acute ischemic stroke. *Hong Kong Journal of Emergency Medicine*. 27 (4): e223-e228.
- [16] L. M. Chen, L. J. Wang, Y. Hu, X. H. Jiang, Y. Z. Wang, Y. Q. Xing. (2018). Ultrasonic measurement of optic nerve sheath diameter: a non-invasive surrogate approach for dynamic, real-time evaluation of intracranial pressure. *British Journal of Ophthalmology*. 0 (1): e1-e5.
- [17] S. J. Lee, M. H. Choi, S. E. Lee, J. H. Park, B. Park, J. S. Lee, J. M. Hong. (2020). Optic nerve sheath diameter changes in prediction of malignant cerebral edema in ischemic stroke: an observational study. *BMC neurology*. 20 (1): e1-e10.
- [18] D. Školoudík, R. Herzig, T. Fadrná, M. Bar, P. Hradílek, M. Roubec, M. Jelínková, D. Šňák, M. Král, J. Chmelová, M. Heřman, K. Langová, P. Kaňovský, P. Kaňovský. (2010). Distal enlargement of the optic nerve sheath in the hyperacute stage of intracerebral haemorrhage. *British journal of ophthalmology*. 95 (2).
- [19] Y. Yüzbaşıoğlu, S. Yüzbaşıoğlu, S. Coşkun, F. Icme, T. Öz, R. Kunt, S. Becel, E. Akçay, H. Ş. Kavakli. (2018). Bedside measurement of the optic nerve sheath diameter with ultrasound in cerebrovascular disorders. *Turkish journal of medical sciences*. 48 (1): e93-e99.
- [20] German Stroke Study Collaboration. (2004). Predicting outcome after acute ischemic stroke: an external validation of prognostic models. *Neurology*. 62 (4): e581-e585.