



# Guided growth by figure of eight plate for correction of pediatric knee coronal angular deformities

*Atef Mohamed Morsy<sup>1</sup>, Emad Gaber Elbanna<sup>1</sup>, Shady Samir Fekry<sup>2</sup>, Ahmed Mahmoud Mohamed Mahmoud<sup>1\*</sup>*

<sup>1</sup>Department of orthopedic surgery, Faculty of Medicine, Beni Suef University

<sup>2</sup>Department of orthopedic surgery, Faculty of Medicine, Ain Shams University

## Abstract

Angular coronal deformities around the knee are common in pediatric orthopedic practice, surgical treatment is needed when the deformity persists or progress after correction of underlying biochemical abnormalities. To evaluate the outcome of guided growth method using tension band plate (epiphyseal 8 plate) for correction of pediatric knee coronal angular deformity. This prospective study conducted on 31 limbs in 20 patients (13 genu varum and 7 genu valgum) at Beni Suef University and Police Hospitals from January 2018 to January 2022. The mean time of plate application is 9.6 months (range 6-12 months). In Varus cases, the rate of correction of mL DFA ranged from 1.3° to 2.3°/ month with Mean about 1.6°/month, the rate of correction of mMPTA in Varus cases ranged from 0.6° to 1.1° with Mean about 0.8°/month. In valgum cases, the rate of correction of mL DFA ranged from 0.7° to 1.6° with Mean about 1.2°/month. the rate of correction of mMPTA in valgum cases ranged from 0.7° to 1.2° with Mean about 0.9° / month. There were 6 limbs from 31 limbs showed complications. Using the guide sleeve system was found to reduce operative time, radiation exposure, and incision size. Guided growth modulation is a best available alternative for the treatment of an angular deformity in the patients with open physis.

**Keywords:** Coronal angular deformity of the knee joint, Eight-Plate, Temporary hemiepiphyseodesis.

**Full length article** \*Corresponding Author, e-mail: [ptrservices2022@gmail.com](mailto:ptrservices2022@gmail.com)

## 1. Introduction

Angular deformities around the knee joint are common in the pediatric population, Physiological deformities account for most of these cases. Most physiological deformities peak between 1 and 3 years (Varus) or between 3 and 6 years (valgus). While physiological deformities usually correct with growth, pathological deformities can cause functional impairment in the form of abnormal gait, painful joint, and a potential risk of developing osteoarthritis of the knee [1-2]. Regardless of whether the etiology is idiopathic, dysplastic, or related to an endocrinopathy, the common goal of surgical treatment is to restore and maintain a neutral mechanical axis [3]. Corrective osteotomy is the gold standard for severe angular deformity but is a major surgical intervention with operative site morbidity, postoperative pain and prolonged therapy that requires internal or external fixation and restricted weight-bearing that are the main drawbacks of this surgery. Osteotomies, especially of the proximal tibia, are high-risk surgeries, with a small but significant incidence of compartment syndrome, neurovascular injury, overcorrection or under-correction,

delayed union or non-union [1]. Historically, permanent hemiepiphyseodesis, using open or percutaneous techniques, was effective in treating angular deformities, but relies on careful preoperative evaluation and postoperative follow-up to avoid overcorrection, under-correction, or both [4]. Temporary hemiepiphyseodesis (surgical growth plate manipulation), a relatively minor, usually no need of weight-bearing reduction. Temporary hemiepiphyseodesis has been shown to provide gradual deformity correction yet may allow resumption of growth with implant removal [4]. Gradual correction by temporary hemiepiphyseodesis can be achieved by stapling and transphyseal screw. Stapling has drawbacks related to implant failure including migration and breakage of implants. Drilling and screwing carries risk of permanent growth arrest. The timing of epiphyseodesis must be perfect otherwise there may be under correction or overcorrection. Stevens (2007) reported that using 8-plate in temporary hemi-epiphyseodesis producing good results with less complication [5-6].

The aim of this work was to evaluate the outcome of guided growth method using tension band plate (epiphyseal 8 plate) for correction of pediatric knee coronal angular deformity.

## 2. Patient and methods

This prospective study conducted on 31 limbs in 20 patients (13 genu varum and 7 genu vulgum) at Beni Suef University and Police Hospitals from January 2018 to January 2022. The mean time of plate application is 9.6 months (range 6-12 months).

### 2.1. Inclusion Criteria

Post ricketic knee deformity, residual physiologic deformity, skeletally immature patients, unilateral and bilateral deformity, and coronal plane deformities around knee.

### 2.2. Exclusion Criteria

Normal Physiologic angular knee deformity, sagittal and rotational deformity around knee, late presenting pediatric patients above 12 years old, children with injured physis and children with dysplastic deformity as achondroplasia and meatphyseal dysplasia.

## 2.3. Method

### 2.3.1. Preoperative Evaluation

Clinical assessment, laboratory parameters and radiographic assessment.

### 2.3.2. Surgical technique

This surgical procedure was done under general anesthesia, no regional or local anesthesia because of the age of patients. Patients placed in supine position, under tourniquet control; fluoroscopic imaging was used. In genu varum Cases lateral physis (femoral, tibial, or both) was localized with the C-arm in antero-posterior and lateral view, while in genu vulgum cases medial physis was localized. The implant used in this study was the Epiphyseal titanium 8 plate either stepped or arches contour (12 mm / 16mm) used according to the patient's anatomy with low profile / low contact surface design to minimize periosteum and growth plate irritation. The selected plate was attached to the corresponding aiming device. Then the handle and lock were inserted with the fixation bolt. Incision 2-3 cm in length was done with splitting of the iliotibial band in femoral genu varum, while in tibial genu varum or genu vulgum cases we didn't disturb the anterior compartment. Periosteum was preserved. The aiming device assembly was placed over the physeal line. The central axis of the plate was on the physeal line. Two 1.5 mm guide wires were inserted over the guide wire holes. Identification of the position of the plate and guide wires with fluoroscope was done in AP and Lateral views. If they were not in the correct placement, removing the guide wires was done and reposition the plate until it's correctly placed. The drill sleeve assembly was inserted into the aiming holes. The 1.5 mm guide wires were placed. The depth gauge was slid over the 1.5 mm guide wires to measure the depth. The direct read indicates the required screw length. the drill sleeve was removed for guide wires 3. plate was applied mid-sagittally (optimal); placing it too far anteriorly was

avoided (because of the risk of recurvatum) drilling done under c-arm to be sure we were away from the physis. Drilling by cannulated 3.0 drill using the c-arm (to be sure that we were away from physis) was applied. Wounds closed and a crepe bandage was performed.

### 2.3.3. Postoperative evaluation

All cases evaluated clinically & radiologically.

### 2.3.4. Postoperative care

Post-operative plain knee x-ray. Patient was discharged after next day postoperative. Oral antibiotic and analgesic were prescribed. Full weight bearing allowed.

### 2.3.5. Patient followed post-operative

Patient followed postoperative as follow 1<sup>st</sup> week new dressing was done, 2<sup>nd</sup> week sutures were removed, 1st month plain x-ray (long film) was done and degrees of correction of deformity were recorded. Follow up every 2 months by plain x-ray (long film) was done and degrees of correction were recorded. When the mechanical axis has been restored and over correction by 5 degrees reached, the implants were removed. Subsequent growth was monitored to detect any complication or recurrence of deformity. Depending on the etiology, there may be recurrent deformity due to rebound growth specially in Blount's disease in obese child; this was which was managed by repeating the procedure.

## 3. Results and Discussion

Our results showed that for Genu varum cases, the mean mL DFA was 101.1° (range from 99 to 105°) preoperatively and corrected to 86.8° (range from 83 to 89°) at latest follow up with. The rate of correction ranged from 1.3° to 2.3°/ month (Mean about 1.6°/month). While for Genu vulgum cases the mean mechanical Lateral Distal Femoral Angle (mL DFA) was 77.9° (range from 75 to 83°) preoperatively and corrected to 89.4° (range from 83 to 89°) at latest follow up with rate of correction ranges from 0.7° to 1.6° (Mean about 1.2° / month). Given the normal value for mL DFA of 87.5° (ranged from 85 to 90°). Tibia deformity parameters (mechanical Medial Proximal Tibial Angle) corrected to within 5° of their normal mean values. Given the normal value of MPTA of 87.5° (ranged from 85 to 90°). In Genu varum cases, the amount of MPTA was increased from a mean of 76° (range from 76 to 83°) preoperatively to 87.2° (range from 85 to 92°) at latest follow up with mean rate of correction 0.8/ month. While in Genu vulgum cases, the amount of MPTA was reduced from a mean of 96° (range from 93.5 to 98°) preoperatively to 85.9° (range from 82.5 to 89.5°) at latest follow up with mean rate of correction 0.9/ month. Ballal et al., (2010) reported 13 patients (28 physes) with genu varum deformity of mean age of 11.6 years. Patients were treated with the extra-periosteal application of 8 plates. The mean plate time of guided growth was 9.1 months (range 8–16 months). Sites of correction were 8 limbs with both distal femur and proximal tibia deformities, 7 limbs with distal femoral deformities and 5 limbs with proximal tibial deformities [8]. Femoral genu varum deformity (mL DFA) corrected within 3° of their normal mean values, while in tibial genu varum MPTA corrected within 4° of their normal mean values.

There was a mean rate of correction of 0.7 degrees per month in femur (range from 0.3 degrees to 1.5 degrees), 0.5 degrees per month in the tibia (range from 0.1 to 0.9 degrees), and 1.2 degrees per month if femur and tibia were treated concurrently (range from 0.1 degrees to 2.2 degrees). Correction was faster if the child was under 10 years of age [7]. Burghardt et al., (2010) reviewed guided growth in 10 patients (17 physes) with genu varum deformity of mean age of 9.7 years using 8 plates. The mean guided growth time as 8.5 months (range, 6-15 months). Sites of correction were 3 limbs with both distal femur and proximal tibia deformities, 11 limbs with proximal tibial deformities [8]. Femoral deformity (mLDFA) corrected within 2° of their normal mean values, while MPTA corrected within 2° of their normal mean values with exclusion of 2 patients which failure of correction occur in both [8]. In our series we have one case with superfascial infection that managed by debridement, three cases with limited knee flexion (2 varum and 1 vulgum) that respond well to physiotherapy and exercise, limited flexion of knee joint explained by entrapment of soft tissue (includes iliotibial band, MPFL, joint capsule) between plate and periosteum. There was also a case with bilateral Blount's disease shown unacceptable correction (under correction) of its side after 10 months from insertion of plates with high degree of screws divergence while Rt side show full correction, so managed by implant removal from Rt side and osteotomy of Lt side also after hardware removal. There was also a case with unilateral genuvarus shown epihyseal screw migration 2 months after operation, reversion done by another screw. 6 months' later removal of hardware done after full correction.

Ballal et al., (2010) reviewed one patient with plate and screw migration and one patient with deep infection who have surgical debridement but no permanent physal tethers were encountered after following up patients between 6 and 32 months after plate removal, while Burghardt et al., (2010) reviewed failure of correction occur in two patients because of not enough growth remaining in the physes [7-8]. Casteneda et al., (2008) reviewed failure of correction occur in 5 patients, 5 patients with staple back out and one patient with superficial infection, while Cho et al., (2009) reviewed rebound tibial varus deformity occur in one patient [9-10]. Nohu et al., (2004) reviewed failure of correction occur in one patient, while Shin et al., (2010) reviewed rebound deformity occur in two proximal tibial and three distal femoral physes, arrested physes in one patient and staple extrusion from one distal femoral physes [11-12].

**4. Case presentation**

A girl 3 yrs old with Bilateral genu varum deformity. Patient spend about 6 months applying plate. Site of correction were bilateral distal femur and proximal tibia .

- **For Rt side** preoperative mLDFA reduced from 101.5° to 88° while preoperative mMPTA increased from 80° to 85° and TFA decreased from 11° to 7°.
- **For Lt side** preoperative mLDFA reduced from 102° to 89° while preoperative mMPTA increased from 82° to 89.5° and TFA decreased from 10° to 2°.

**Table 1:** Patients' Demographics.

Age group	2-3	3-4	4-5	5-6	6-7	7-8	8-9	9-10	10-11	11-12
Numbers	2	4	9	2	0	1	1	0	0	1
Percentages	10%	20%	45%	10%	0%	5%	5%	0%	0%	5%
Mean	4.7 years old									
Sex	Number					Percentages				
Male	11					55%				
Female	9					45%				
Total	20					100%				

Table 1 showed that patients age ranged between 2.5–11 years old at the time of surgery. The mean age was 4.7 years. It also showed that 45% of patients were females and 55% were males.

**Table 2:** Rate of correction of mLDFA in varus and valgum cases per month.

Varus cases												
Case no.	1	2	3	4	5	6	7	8	9	10	11	12
Rate of correction / month	1.6	1.6	1.8	1.5	2.2	1.5	2.1	1.3	1.4	1.5	1.3	1.5
Mean	1.6°/month											
Valgum cases												
Case no.	1	2	3	4	5	6	7					
Rate of correction / month	0.78	1.43	1	1.17	1.56	1.25	1.44					
Mean	1.2° / month											

Table 2 showed that the rate of correction of mLDFA in varus cases ranged from 1.3° to 2.3°/ month with Mean about 1.6°/month and the rate of correction of mLDFA in valgum cases ranged from 0.7° to 1.6° with Mean about 1.2° / month.

**Table 3:** Rate of correction of mMPTA in varus and vulgum cases per month.

Varus cases											
Case no.	1	2	3	4	5	6	7	8	9	10	11
Rate of correction / month	0.6	0.7	1	1	0.9	1.1	0.8	1	0.6	0.8	0.6
Mean	0.8°/month										
Vulgum cases											
Case no	1	2	3	4	5	6					
Rate of correction / month	0.88	0.79	1.13	1.08	0.67	0.89					
Mean	0.9 ° / month										

Table 3 showed that the rate of correction of mMPTA in Varus cases ranged from 0.6° to 1.1° with Mean about 0.8°/month and the rate of correction of mMPTA in vulgum cases ranged from 0.7° to 1.2° with Mean about 0.9 ° / month.

**Table 4:** Rate of correction of TFA in Varus and vulgum cases per month.

Varus cases													
Case no.	1	2	3	4	5	6	7	8	9	10	11	12	13
Rate of correction / month	0.3	0.8	0.8	0.8	0.8	1	1.1	0.8	0.9	1	1.2	1.1	0.9
Mean	0.9 ° / month												
Vulgum cases													
Case no.	1	2	3	4	5	6	7						
Rate of correction / month	1.3	1.1	0.7	1.2	0.8	1.1	1						
Mean	1 ° / month												



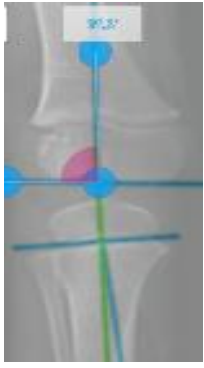
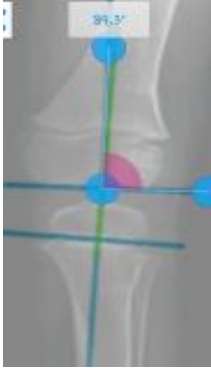
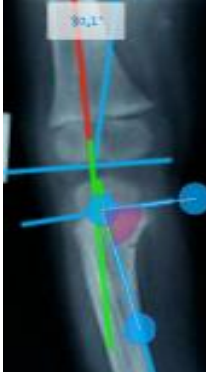

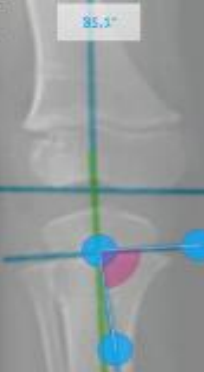
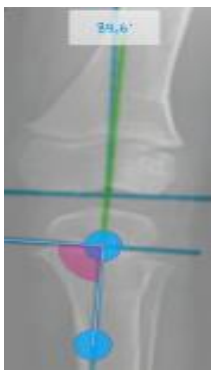


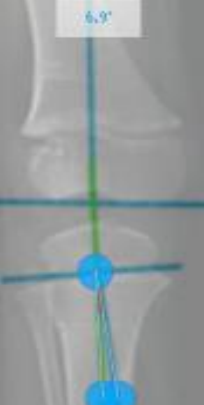
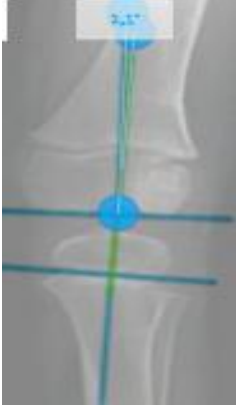
Table 4 showed that the rate of correction of TFA in Varus cases ranged from 0.3° to 1.2° with Mean about 0.9°/month and the rate of correction of TFA in vulgum cases ranges from 0.7° to 1.2° with Mean about 1° / month.

**Table 5:** Complications in our study.

Complications	Number	Percentages
Super-fascial infection	1 limb	3.2%
Limited flexion	3 limbs	9.7%
Under-correction	1 limb	3.2%
Screw migration	1 limb	3.2%
<b>Total</b>	6 limbs from 31 limbs	19.4 %

Table 5 showed that there were 6 limbs from 31 limbs showed complications (1 limb showed super fascial infection, 3 limbs showed limited flexion, 1 limb showed unacceptable correction (under correction) and 1 limb showed screw migration).

**Table 6:** Pre and post correction angles.

	Preoperative		Postoperative	
	Rt	Lt	Rt	Lt
<b>mLDFA</b>	 101.5°	 102°	 88°	 89°
<b>mMPTA</b>	 80°	 82°	 85°	 89.5°
<b>TFA</b>	 11°	 10°	 7°	 2°

**5. Conclusions**

Our results reflect the efficacy of epiphyseal eight-plate which corrects angular deformity by acting as a tension band on one side of the growth plate and offers the advantage of reversible Hemi epiphyseal growth modulation. The guided system used in our study determine the optimal incision based on the guide pins also using the guide sleeve system before the skin incision allow accurate plate positioning and screws insertion into the epiphysis and the metaphysis without physeal injury accurately place our plates in the coronal and sagittal planes This technique was found to reduce operative time, radiation exposure, and incision size.

Guided growth modulation is a best available alternative for the treatment of an angular deformity in the patients with open physis.

**References**

[1] A. Kumar, S. Gaba, A. Sud, P. Mandlecha, L. Goel, M. Nayak. (2016). Comparative study between staples and eight plate in the management of coronal plane deformities of the knee in skeletally immature children. *Journal of Children's Orthopaedics*. 10 (5): e429-e437.

- [2] T. J. Cho, I. H. Choi, C. Y. Chung, W. J. Yoo, M. S. Park, D. Y. Lee. (2009). Hemiepiphyseal stapling for angular deformity correction around the knee joint in children with multiple epiphyseal dysplasia. *Journal of Pediatric Orthopaedics*. 29 (1): e52-e56.
- [3] V. Abad, J. L. Meyers, M. Weise, R. I. Gafni, K. M. Barnes, O. L. A. Nilsson, J. D. Bacher, J. Baron. (2002). The role of the resting zone in growth plate chondrogenesis. *Endocrinology*. 143 (5): e1851-e1857.
- [4] W. E. Horton Jr, L. Feng, C. Adams. (1998). Chondrocyte apoptosis in development, aging and disease. *Matrix Biology*. 17 (2): e107-e115.
- [5] P. M. Stevens. (2007). Guided growth for angular correction: a preliminary series using a tension band plate. *Journal of Pediatric Orthopaedics*. 27 (3): e253-e259.
- [6] S. P. Das, S. Pradhan, P. K. Sahoo, R. N. Mohanty, S. K. Das. (2012). Our experience with correction of angular deformities of knee by flexible figure of 8-plate hemiepiphysiodesis. *IJPMR*. 23 (2): e68-e73.
- [7] M. S. Ballal, C. E. Bruce, S. Nayagam. (2010). Correcting genu varum and genu valgum in children by guided growth: temporary hemiepiphysiodesis using tension band plates. *The Journal of Bone & Joint Surgery British Volume*. 92 (2): e273-e276.
- [8] R. D. Burghardt, S. C. Specht, J. E. Herzenberg. (2010). Mechanical failures of eight-plate-guided growth system for temporary hemiepiphysiodesis. *Journal of Pediatric Orthopaedics*. 30 (6): e594-e597.
- [9] P. Castañeda, B. Urquhart, E. Sullivan, R. J. Haynes. (2008). Hemiepiphysiodesis for the correction of angular deformity about the knee. *Journal of Pediatric Orthopaedics*. 28 (2): e188-e191.
- [10] T. J. Cho, I. H. Choi, C. Y. Chung, W. J. Yoo, M. S. Park, D. Y. Lee. (2009). Hemiepiphysial stapling for angular deformity correction around the knee joint in children with multiple epiphysial dysplasia. *Journal of Pediatric Orthopaedics*. 29 (1): e52-e56.
- [11] F. Nouth, L. A. Kuo. (2004). Percutaneous epiphysiodesis using transphyseal screws (PETS): prospective case study and review. *Journal of Pediatric Orthopaedics*. 24 (6): e721-e725.
- [12] S. J. Shin, T. J. Cho, M. S. Park, J. Y. Bae, W. J. Yoo, C. Y. Chung, I. H. Choi. (2010). Angular deformity correction by asymmetrical physeal suppression in growing children: stapling versus percutaneous transphyseal screw. *Journal of Pediatric Orthopaedics*. 30 (6): e588-e593.