



# Healing of large periapical lesion by Regenerative Endodontic procedure in immature and mature permanent teeth with/without collagen-hydroxyapatite scaffold: A Case report

*Menna Allah Ali Abdeldaiem Ali, Maram Farouk Obeid, Abeer Abdelhakim El Gendy*

*Endodontic department, Ain Shams University, Egypt*

## Abstract

The purpose of this case report is to report healing of a large periapical lesion with average size of the lesion 9.538 cm<sup>3</sup> related to immature and mature necrotic teeth using a novel collagen-hydroxyapatite scaffold in regenerative endodontic procedure. Apical periodontitis related to tooth number seven and eight with (in the same patient) was determined from preoperative cone beam computed tomography scans. Teeth were treated via a revascularization protocol using 1.5% sodium hypochlorite irrigant, a double antibiotic paste was placed for 21 days, collagen-hydroxyapatite scaffold and a coronal seal of mineral trioxide aggregate, and glass ionomer restoration were placed in the second visit. After 1-year follow-up, teeth showed resolution of clinical signs and symptoms in addition to resolution of periapical radiolucency. Results from this case show that regenerative endodontic procedure is an effective treatment option for both immature and mature teeth with apical periodontitis. Based on this case report, the following recommendations are made to help with the regenerative endodontic technique: (1) patient compliance for multiple appointment treatment plan may be significant for case selection. (2) Optimum disinfection protocol is a key factor for success of regenerative endodontic process. (3) Preserving coronal seal throughout interappointment time and after completion of treatment.

**Keywords:** Immature, scaffold, hydroxyapatite, mineral trioxide aggregate, regeneration

**Full-length article** \*Corresponding Author, e-mail: [menna.ali1991@gmail.com](mailto:menna.ali1991@gmail.com)

Doi # <https://doi.org/10.62877/87-IJCBS-24-25-19-87>

## 1. Introduction

Pulp tissue regeneration has emerged in endodontics mainly as an alternative treatment to conventional root canal treatment for immature necrotic teeth [1]. The first trials for regenerative endodontics included the induction of blood clot for pulp revascularization, recruiting stem cells residing in the apical papilla and utilizing growth factors embedded in dentine. The blood clot itself was considered the scaffold that holds cells and molecules together [2]. This approach is known as cell homing [3]. Scaffold acts as a three-dimensional vehicle that aids in cellular adhesion, cell-cell and cell-matrix interactions and formation of new tissues. The most commonly used material as a scaffold is collagen type 1 since it is considered the major component of the extracellular matrix, biodegradable, easily replaced with newly formed regenerated tissues and allows easy placement of stem cells and morphogenesis [1]. The incorporation of bioactive molecules within a natural scaffold has been recently introduced in dental literature highlighting the potential of better cellular differentiation, dentogenesis, and cementogenesis leading to faster healing and apical closure.

Calcium phosphates play a crucial role in cell adhesion and adsorption of extracellular matrix proteins on the surface [4]. Hydroxyapatite and tricalcium phosphates are

the most common naturally occurring calcium phosphates in the human body. Both are well known for their bioactive potential. The only difference between these two compounds is that hydroxyapatite is non resorbable [5] while the latter is. In 1986 a mixture of HAP and  $\beta$ -TCP was first prepared as a biphasic form of calcium phosphates [6]. This mixture was then reintroduced in the market by GENOSS Co., Ltd. as a bone grafting material named OSTEON III [7]. OSTEON III was approved by FDA in 2016 for human use, and was composed of an interconnected porous structure, of macro and micro pores similar to the structure of human cancellous bone. Lately, a new attempt has been carried out to combine osteoconductive property of hydroxyapatite and beta tricalcium phosphate and ease of handling, shaping and wettability of collagen and introduced a new scaffold "Osteon III collagen" in market [8]. Hence, this study is conducted to test the outcome of regenerative endodontic procedure using this newly introduced scaffold versus the conventional blood clot scaffold.

## 2. Materials and methods

A healthy 11-year-old male was referred for treatment of chronic apical abscess related to tooth number 7. The patient reported that he had been subjected to trauma 4

years before. An intraoral swelling was noted on the buccal mucosa above tooth number 7. Preoperative CBCT scan revealed periapical lesion with average size 9.538 cm [3] related to teeth number 7 and 8 and incomplete root development in tooth number 8. After clinical and radiographic examination (Fig. 1A), the diagnosis was as follows: tooth number 8 - pulpal necrosis, asymptomatic apical periodontitis and tooth number 7 - pulpal necrosis and chronic apical abscess. Revascularization procedures were recommended for both teeth. Patient approved the application of treatment. After informed consent was obtained, the teeth were anesthetized with 4% Articaine with 1:100,000 epinephrine, isolated with a rubber dam, and accessed. Upon access, purulent exudate was found in tooth number 7. The canals of both teeth were irrigated with 20 mL of 1.5% NaOCl, followed by 20 mL of saline, then double antibiotic paste was injected in the root canals [9].

Double antibiotic paste was prepared as follows; 1:1 mixture of ciprofloxacin and metronidazole was freshly prepared in propylene glycol vehicle with final concentration 0.5mg/5ml in an injectable form. Access cavity was sealed with 3 to 4 mm of glass ionomer restoration and the patient was dismissed and recalled after 3 weeks for the second visit. Second visit (After 21 days): Response to initial treatment was assessed, signs/symptoms were resolved. Anesthesia with 3% mepivacaine without vasoconstrictor, rubber dam isolation, Copious gentle irrigation with 20 mL of ethylenediamine tetraacetic acid (EDTA), followed by saline was applied [9]. Blood induction inside the root canals of both teeth was done by over-instrumentation using K file size 30 until the canals are flooded with blood. Furthermore, 0.025 g Osteon III collagen moldable scaffold was packed inside the root canal space of tooth number 8. A layer of 3-4 mm of white MTA was placed 3 mm below CEJ, moist cotton is placed above MTA to ensure final setting covered with reinforced glass ionomer as a temporary restoration.

### 3. Results and Discussions

At the 6-month and 1-year (Fig. 1E) recall examinations, the patient remained asymptomatic. CBCT images taken at 1 year showed that the periapical lesion appeared to heal with average size 0.051 cm [3]. Regenerative endodontic procedure is considered the first line of treatment for immature necrotic teeth. The American association of Endodontists recommends that an ideal outcome of any regenerative endodontic procedure should include three goals: 1) primary goal: the elimination of symptoms and evidence of bone healing; 2) secondary goal: an increase in root development; 3) tertiary goal: a positive response to vitality. Recent studies highlighted the concept of "biological obturation" of the root canal in mature teeth and re-establishing newly formed tissues with sensory and immune mechanisms. The present case represented regeneration using experimental external scaffold, Osteon 3 collagen in immature permanent human teeth, against conventional blood clot in mature one.

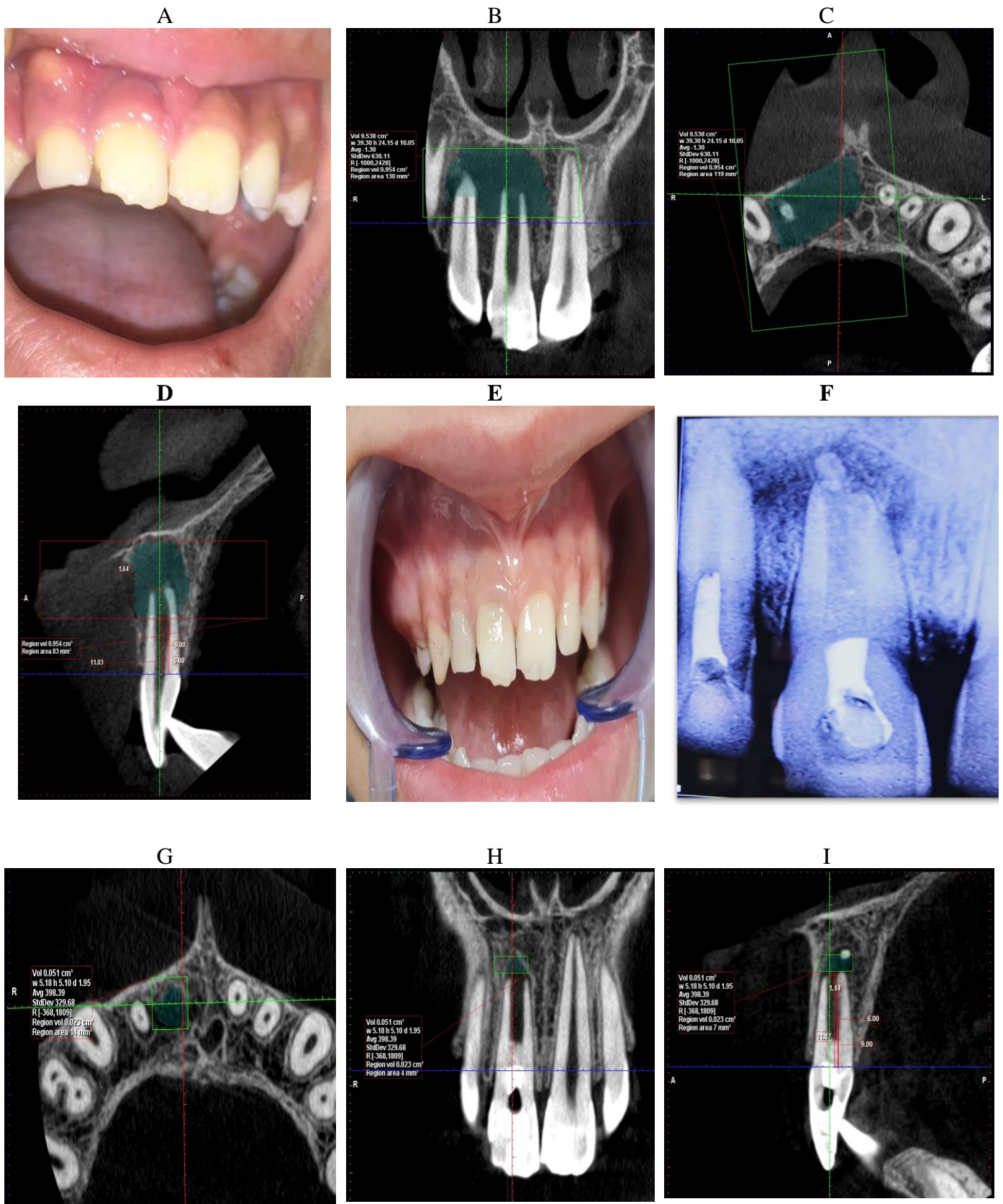
Generally, the control of infection established in the root canal and periapical tissues is critical. However, it is also essential to preserve the stem cells' viability present on the apical papilla. Nevertheless, the control of microorganism reinfection is crucial to regenerate the dentin-pulp complex [10-11]. In the current study, the applied disinfection protocol was the same as recommended in AAE guidelines [9]. Root

canals were irrigated with 1.5 % sodium hypochlorite (20mL/canal, 5 min) to maintain viability of stem cells since maximum clinically used concentration was reported to have detrimental effect on stem cell survival and denatures growth factors in dentin as reported by Galler et al [11], Essner et al [12] and Casagrande et al [13]. Freshly prepared double antibiotic liquid (1:1 mixture of ciprofloxacin and metronidazole in propylene glycol vehicle) with final concentration 0.5mg/5ml was placed in the root canal for three weeks. The recommended dilution appears as a liquid and no longer a paste in order to retain the desirable anti-bacterial and anti-biofilm effect and avoiding stem cell toxicity.

Ruparel et al [14] reported in a previous study that survival rate of SCAP was observed from 33% to 56% when cells were exposed to 1 mg/mL DAP and showed a survival rate of 100% when greater dilutions were used. Moreover, Althumairy et al [15] reported that preparing DAP in a paste form resulted in very high concentrations up to 1000 mg/mL with no viable SCAP. 17% EDTA was used in the second visit to extract growth factors embedded in dentin, especially VEGF and TGF- $\beta$  and thus promotes proliferation and differentiation of stem cells. Moreover, EDTA is a strong chelating agent, removes smear layer, has antibacterial property by extracting bacterial surface proteins, which lead to bacterial death, removes biofilm and decreases intracanal microbial load. It was proven that not only EDTA preserve stem cells viability but also it increases their attachment to dentin in many previous studies [16-17].

Even with the maximum infection control procedures, there are still challenges, such as creating a blood clot as a scaffold [18]. Bioactive ceramic scaffolds containing HA or TCP or mixture of both have been previously investigated by Gronthos et al., Sonoyama et al, Nevins et al, Zhu et al who reported success of regenerative procedure [19-25]. Osteon 3 collagen scaffold is a bioactive ceramic scaffold that was previously reported to be used as a bone grafting material [26]. The scaffold is supplied in a cylinder form that changes to various shapes in wet environment. Recent studies reported the use of Osteon 3 collagen in regenerative endodontics. Regenerative endodontics was the treatment of choice in tooth number 7 as regeneration in mature teeth has shown promising outcomes in recent previous studies [18-27-28].

Although mechanical seal made by different obturation techniques yield high success in literature, the concept of biological obturation of the root canal with newly-formed tissues has more beneficial aspects; mainly re-establishing sensory and immune mechanisms, decreasing the incidence of flare-ups and increasing fracture resistance of endodontically treated teeth [27]. MTA is a bioceramic material, which possess beneficial criteria as it is chemically stable, bioactive, biocompatible, and non-toxic, does not shrink, and Osteo inductive. Moreover, MTA enhances MSCs osteo/odontogenic ability. In particular, it upregulates osteo/odontogenic markers such as Osteocalcin (*OCN*), Alkaline phosphatase (*ALP*), Bone sialoprotein (*BSP*), Osteopontin (*OPN*), Collagen I (*COL1*), Runt-related transcription factor 2 (*RUNX2*), Osterix (*OSX*), and *DSPP*. The transcription factor *RUNX2* is considered the master regulator of mineralization-related genes. That's why MTA is the material of choice in REP [28].



**Figure 1.** (A) A preoperative photograph showing intraoral swelling related to tooth # 7. Preoperative Cone-beam images (B); Axial cut, (C) Coronal cut, (D) Sagittal cut showing a periapical radiolucency approximately 9.5 cm<sup>3</sup> in diameter. (E) A photograph healing of intraoral swelling after 21 days disinfection (F) Immediate postoperative radiograph taken with Osteon 3 collagen placed into the root canal of tooth number 8. 1-year postoperative Cone-beam images: (G) axial views, (H) coronal view (I) sagittal view showing significant decrease in periapical radiolucency of 0.05 cm<sup>3</sup> in diameter

Method of assessment of radiographic outcome in the current study is Cone beam computed tomography, according to AAE joint position statement recommendation number 11 in which Limited Field of view CBCT should be taken for diagnosis and management of limited dento-alveolar trauma [29]. Preoperative and 1 year follow up CBCT scans were compared, bony lesion size, root length, dentine thickness, and apical diameter were measured, documented, tabulated and subjected for statistical analysis. It should be noted that the regeneration conditions between bone and dentin are very different. Bone contains marrow space where stem cells responsible for the regeneration of the adjacent bone resides. Dentin does not contain any marrow space and its regeneration is dependent on the condition of the pulp. Therefore, having a healthy pulp is a prerequisite for dentin regeneration. The critical size defect was defined in the study of bone regeneration that, without introducing any supportive approaches, the tissue will not regenerate naturally during the lifetime of the animal [30]. The critical size defect has never been experimentally tested for pulp.

Theoretically, the entire pulp chamber roof dentin, if lost, may be regenerated with the dentin bridge. However, it is difficult to determine how much pulp tissue loss exceeds the natural ability to regenerate. Unfortunately, Pulp tissue regeneration accomplished by cell homing technique is not expected since it would have exceeded its critical size defect [30]. In the present study, bony lesion healed at 1 year follow up CBCT, our results agree with Nevins et al [24] in which periapical lesions healed in all teeth using the same scaffold material. Many clinical case reports have shown good outcomes with pulp revitalization of immature teeth in terms of healing and absence of pathology. Regarding root development, the results vary in those case reports, especially when comparing the dentin wall thickness, the root length, and the size of the pulp canal after treatment. In the present case study, root development did not show any progression. In a review reported by Torbinejad [31] the rate of root development varied from 21%–100%, which shows the low predictability of the secondary outcome after revascularization.

#### 4. Conclusions

Under the circumstances of this study, it can be concluded that: Regenerative endodontic procedures are an effective and reliable line of treatment for necrotic immature and mature permanent teeth. Placement of artificial external scaffolds, even though being bioactive, did not increase the success of regenerative endodontic procedure.

#### References

- [1] S.E.-D.M. Saber. (2009). Tissue engineering in endodontics. *Journal of oral Science*. 51(4): 495-507.
- [2] H. Dhillon, M. Kaushik, R. Sharma. (2016). Regenerative endodontics—creating new horizons. *Journal of Biomedical Materials Research Part B: Applied Biomaterials*. 104(4): 676-685.
- [3] M. Albuquerque, M. Valera, M. Nakashima, J. Nör, M. Bottino. (2014). Tissue-engineering-based strategies for regenerative endodontics. *Journal of dental research*. 93(12): 1222-1231.
- [4] E. Fujii, M. Ohkubo, K. Tsuru, S. Hayakawa, A. Osaka, K. Kawabata, C. Bonhomme, F. Babonneau. (2006). Selective protein adsorption property and characterization of nano-crystalline zinc-containing hydroxyapatite. *Acta biomaterialia*. 2(1): 69-74.
- [5] J. Jeong, J.H. Kim, J.H. Shim, N.S. Hwang, C.Y. Heo. (2019). Bioactive calcium phosphate materials and applications in bone regeneration. *Biomaterials research*. 23(1): 4.
- [6] R.F. Ellinger, E.B. Nery, K.L. Lynch. (1986). Histological Assessment of Periodontal Osseous Defects Following Implantation of Hydroxyapatite and Biphasic Calcium Phosphate Ceramics: A Case Report. *International Journal of Periodontics & Restorative Dentistry*. 6(3).
- [7] A.A. Mubarakah, A. Syaify, S.P. Lastianny. Effectiveness of MIST with hydroxyapatite and  $\beta$ -tricalcium phosphate in alveolar bone density and osteocalcin level improvement during treatment of infrabony pockets. *Majalah Kedokteran Gigi Indonesia*. 8(2): 110-116.
- [8] P. Demir, B. Demircan, E.T. Bulut, N. Şimşek. (2022). Knowledge and clinical experiences of pediatric dentists and endodontists regarding regenerative endodontic procedures. *Ann Clin Anal Med*. 13(4): 451-456.
- [9] A. ElSheshtawy, H. Nazzal, O. El Shahawy, A. El Baz, S. Ismail, J. Kang, K. Ezzat. (2020). The effect of platelet-rich plasma as a scaffold in regeneration/revitalization endodontics of immature permanent teeth assessed using 2-dimensional radiographs and cone beam computed tomography: a randomized controlled trial. *International Endodontic Journal*. 53(7): 905-921.
- [10] D.E. Martin, J.F.A. De Almeida, M.A. Henry, Z.Z. Khaing, C.E. Schmidt, F.B. Teixeira, A. Diogenes. (2014). Concentration-dependent effect of sodium hypochlorite on stem cells of apical papilla survival and differentiation. *Journal of endodontics*. 40(1): 51-55.
- [11] K.M. Galler, R.N. D'Souza, M. Federlin, A.C. Cavender, J.D. Hartgerink, S. Hecker, G. Schmalz. (2011). Dentin conditioning codetermines cell fate in regenerative endodontics. *Journal of endodontics*. 37(11): 1536-1541.
- [12] M.D. Essner, A. Javed, P.D. Eleazer. (2011). Effect of sodium hypochlorite on human pulp cells: an in vitro study. *Oral Surgery, Oral Medicine, Oral Pathology, Oral Radiology, and Endodontology*. 112(5): 662-666.
- [13] L. Casagrande, F.F. Demarco, Z. Zhang, F. Araujo, S. Shi, J. Nör. (2010). Dentin-derived BMP-2 and odontoblast differentiation. *Journal of dental research*. 89(6): 603-608.
- [14] N.B. Ruparel, F.B. Teixeira, C.C. Ferraz, A. Diogenes. (2012). Direct effect of intracanal medicaments on survival of stem cells of the apical papilla. *Journal of endodontics*. 38(10): 1372-1375.
- [15] R.I. Althumairy, F.B. Teixeira, A. Diogenes. (2014). Effect of dentin conditioning with intracanal medicaments on survival of stem cells of apical papilla. *Journal of endodontics*. 40(4): 521-525.

- [16] E.G. Trevino, A.N. Patwardhan, M.A. Henry, G. Perry, N. Dybdal-Hargreaves, K.M. Hargreaves, A. Diogenes. (2011). Effect of irrigants on the survival of human stem cells of the apical papilla in a platelet-rich plasma scaffold in human root tips. *Journal of endodontics*. 37(8): 1109-1115.
- [17] K.C. Ring, P.E. Murray, K.N. Namerow, S. Kuttler, F. Garcia-Godoy. (2008). The comparison of the effect of endodontic irrigation on cell adherence to root canal dentin. *Journal of endodontics*. 34(12): 1474-1479.
- [18] A. Subbiya, L. Saatwika, R. Tamilselvi. (2020). Regenerative endodontics on necrotic mature permanent teeth—a review. *Eur J Mol Clin Med*. 7: 2121-7.
- [19] W. Sonoyama, Y. Liu, D. Fang, T. Yamaza, B.-M. Seo, C. Zhang, H. Liu, S. Gronthos, C.-Y. Wang, S. Shi. (2006). Mesenchymal stem cell-mediated functional tooth regeneration in swine. *Plos one*. 1(1): e79.
- [20] A.J. Nevins, F. Finkelstein, B.G. Borden, R. Laporta. (1976). Revitalization of pulpless open apex teeth in rhesus monkeys, using collagen-calcium phosphate gel. *Journal of endodontics*. 2(6): 159-165.
- [21] A. Nevins, W. Wrobel, R. Valachovic, F. Finkelstein. (1977). Hard tissue induction into pulpless open-apex teeth using collagen-calcium phosphate gel. *Journal of endodontics*. 3(11): 431-433.
- [22] A. Nevins, F. Finkelstein, R. Laporta, B.G. Borden. (1978). Induction of hard tissue into pulpless open-apex teeth using collagen-calcium phosphate gel. *Journal of endodontics*. 4(3): 76-81.
- [23] A.J. Nevins, R.F. LaPorta, B.G. Borden, L.S. Spangberg. (1980). Pulpotomy and partial pulpectomy procedures in monkey teeth using cross-linked collagen-calcium phosphate gel. *Oral Surgery, Oral Medicine, Oral Pathology*. 49(4): 360-365.
- [24] A. Nevins, P. Crespi. (1998). A clinical study using the collagen gel Zyplast in endodontic treatment. *Journal of endodontics*. 24(9): 610-613.
- [25] X. Zhu, J. Liu, Z. Yu, C.-A. Chen, H. Aksel, A.A. Azim, G.T.-J. Huang. (2018). A miniature swine model for stem cell-based de novo regeneration of dental pulp and dentin-like tissue. *Tissue Engineering Part C: Methods*. 24(2): 108-120.
- [26] S. Kuttappan, D. Mathew, M.B. Nair. (2016). Biomimetic composite scaffolds containing bioceramics and collagen/gelatin for bone tissue engineering—A mini review. *International Journal of Biological Macromolecules*. 93: 1390-1401.
- [27] H.M. Abada, A.A.R. Hashem, A.M. Abu-Seida, M.M. Nagy. (2022). The effect of changing apical foramen diameter on regenerative potential of mature teeth with necrotic pulp and apical periodontitis. *Clinical Oral Investigations*. 1-11.
- [28] D. Babaki, S. Yaghoubi, M.M. Matin. (2020). The effects of mineral trioxide aggregate on osteo/odontogenic potential of mesenchymal stem cells: a comprehensive and systematic literature review. *Biomaterial Investigations in Dentistry*. 7(1): 175-185.
- [29] M. Bhatt, J. Coil, B. Chehroudi, A. Esteves, J. Aleksejuniene, D. MacDonald. (2021). Clinical decision-making and importance of the AAE/AAOMR position statement for CBCT examination in endodontic cases. *International Endodontic Journal*. 54(1): 26-37.
- [30] G.T.J. Huang, M. Al-Habib, P. Gauthier. (2013). Challenges of stem cell-based pulp and dentin regeneration: A clinical perspective. *Endodontic Topics*. 28(1): 51-60.
- [31] M. Torabinejad, A. Nosrat, P. Verma, O. Udochukwu. (2017). Regenerative endodontic treatment or mineral trioxide aggregate apical plug in teeth with necrotic pulps and open apices: a systematic review and meta-analysis. *Journal of endodontics*. 43(11): 1806-1820.